

# MODIFICATION OF THE AUSTIN BUNIONECTOMY

**Stanley R. Kalish, D.P.M.**  
**Marc R. Bernbach, D.P.M.**

## Introduction

Kelikian describes over 100 procedures for correction of hallux abducto valgus. Various subjective and objective clinical criteria exist for each of these procedures. However, due to the wide variety of operative procedures, it may be assumed that some less than satisfactory results have been obtained.

Approaches to hallux abducto valgus surgery have varied from proximal or distal metaphyseal correction to joint destructive procedures. In 1962 Dale W. Austin, D.P.M., M.D. performed a distal metaphyseal first metatarsal osteotomy. The osteotomy was a horizontally directed 60 degree "V" displacement osteotomy. The procedure was developed in response to his dissatisfaction with previous surgical operations. The advantages of the osteotomy as cited by Austin and Leventen in *Clinical Orthopedics and Related Research*, 1981 indicate intrinsic stability of the osteotomy without fixation and, early ambulation without casting, as well as a low rate of reoccurrence of deformity.

Although the Austin procedure has been a very successful operation over the years complications have occurred including 1) displacement of the osteotomy, 2) delayed or nonunion, 3) Kirschner wire (K-wire) pin tract infection if fixated, and 4) limitation of first metatarsophalangeal joint range of motion.

The Kalish modification addresses the complications of the original Austin procedure (Fig 1). Rigid internal fixation and a more intrinsically stable 55 degree "V" osteotomy reduces the possibility of displacement as well as delayed or nonunion. Due to the absence of externally placed fixation devices pin tract infection has been avoided. Earlier range of motion with ambulation beginning the day of surgery has helped decrease first metatarsophalangeal joint range of motion limitation.

## Indications

The indications for the Kalish modification are similar to those originally described by Austin. However, in our experience a larger metatarsus primus adductus angle may be corrected than with the traditional procedure.

This is attributed to the increased stability and rigid internal fixation of the osteotomy allowing greater lateral displacement of the capital fragment. When early ambulation is desired and the disadvantages of K-wire fixation are to be avoided, this modification is an excellent choice. The following indications have been identified:

1. Hallux abductus angle greater than 15 degrees
2. Metatarsus primus abductus angle less than or equal to 15 degrees
3. Pain free first metatarsophalangeal joint range of motion
4. Absence of degenerative joint disease

## Technique

Utilizing the concepts of anatomic dissection of the first metatarsophalangeal joint, an approximately 7 cm curvilinear incision is made over the first metatarsophalangeal joint. The incision is deepened through skin and subcutaneous tissue to the level of first metatarsophalangeal joint capsule. Dissection is carried down to the floor of the first interspace. The adductor hallucis tendon is released and tagged for later use. Dissection along the medial side of the joint is carried along the deep fascia and capsule to the plantar most aspect of the joint. An inverted L capsular incision is then performed.

After resection of the medial eminence of the first metatarsal head, a .045 K-wire is placed through the medial lateral cortices of the first metatarsal head to serve as an apical axis guide (Fig 2). By appropriate placement of the axis guide the surgeon is able to plantarflex, dorsiflex, or maintain the current level of the first metatarsal head.

Additionally, either elongating, shortening, or no change (neutral) of the first metatarsal length may be obtained by apical axis guide positioning (Fig 3).

## Osteotomy

Utilizing the axis guide, a 55 degree V-osteotomy with an elongated dorsal wing is then performed. The dorsal wing must be large enough to accommodate two 2.7 mm ASIF screws. The plantar cut should approximate the

direction of screw placement, dorsal distal to proximal plantar. Distal traction is then placed on the first metatarsophalangeal joint and the capital fragment is then translocated laterally one-fourth to one-half the width of the first metatarsal shaft.

## Fixation

### Pre-fixation

After translocation of the capital fragment, a .045 K-wire is placed distally across the osteotomy in a dorsal lateral to plantar medial direction followed by a proximal .062 K-wire to serve as temporary fixation (Fig 4). A .062 K-wire is then placed between the two previous wires to serve as a pilot hole. Placement of all three wires is to be parallel to each other.

### Primary Fixation

#### Stage I.

Once pre-fixation has been achieved, primary fixation is performed. Utilizing appropriate AO technique a 2.7 mm screw is then placed across the osteotomy site utilizing the .062 central pilot hole previously drilled. The technique is described by the following steps (Fig 5).

1. 2.0 mm central hole drill
2. 2.7 mm overdrill
3. Countersink
4. Depth gauge (12-18 mm range)
5. Tap
6. Screw

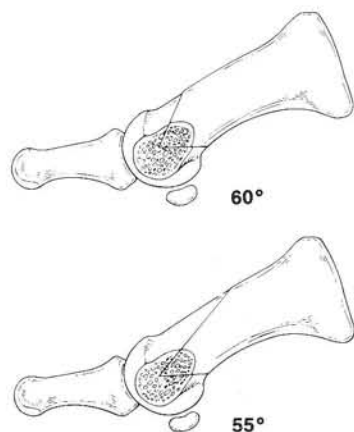


Fig. 1. 55 degree Kalish modification vs 60 degree traditional Austin.

## Closure

Adductor hallucis tendon transfer, closure of the first metatarsophalangeal joint capsule, deep fascia, superficial fascia and skin layer are then performed.

## Retrospective Study

A retrospective study was performed at Doctors Hospital with 64 patients and a greater than one year followup. The study involved the use of a subjective questionnaire as well as objective clinical followup.

### Preliminary Results

Subjective Study. 92% of those patients questioned indicated a better than expected overall result. 98% of those patients questioned indicated no reoccurrence of the deformity at this time. The absence of screw discomfort was stated by 98% of those patients surveyed. The average period of postoperative edema was indicated to be less than six weeks.

### Objective Study

	Preop	Postop	Average
Metatarsus primus adductus	14 degrees	3 degrees	11 degrees
Hallux abductus angle	30 degrees	16 degrees	14 degrees

Further objective evaluation and followup from one to three years is now being done.

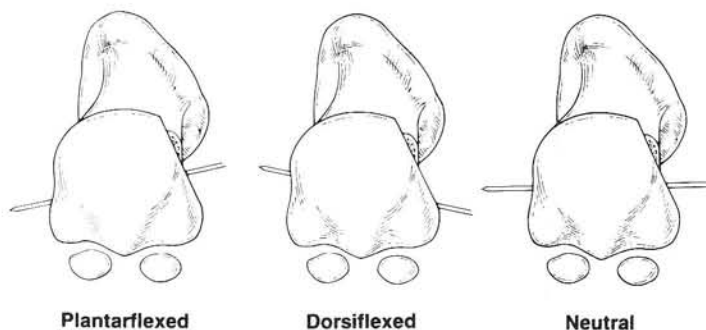


Fig. 2. Axis guide positioning.

## Primary Fixation

### Stage II (Proximal Hole)

Once the distal screw has been placed across the osteotomy site and secured, the proximal .062 K-wire is removed. Utilizing appropriate AO technique a 2.7 mm cortical screw is placed across the osteotomy utilizing the previously drilled proximal hole (Fig 6). The technique is illustrated by the following steps.

1. Follow .045 K-wire direction
2. 2.0 mm drill
3. 2.7 mm overdrill
4. Countersink
5. Depth gauge
6. Tap
7. Screw
8. .045 K-wire removed

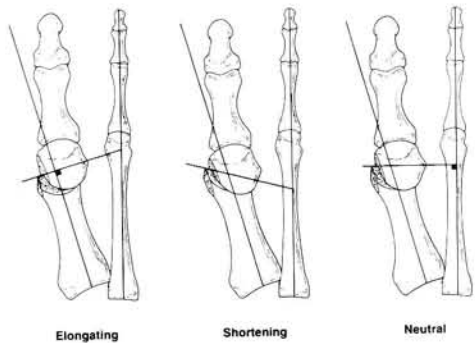


Fig. 3. Axis guide positioning.

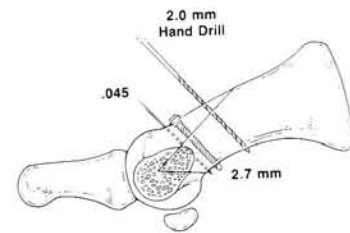


Fig. 5. 2.0 mm drill in place for proximal hole.

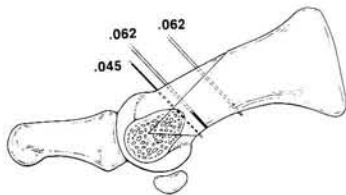


Fig. 4. K-wire placement for pre-fixation.

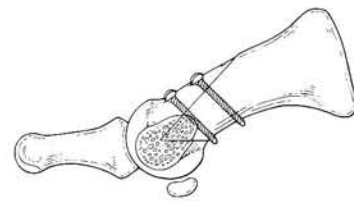


Fig. 6. Osteotomy and fixation completed.

## Complications

Hallux varus is a definite possibility of this procedure because of the large amount of metatarsus primus adductus correction available. It is imperative that the hallux, first metatarsal, and tibial sesamoidal position be evaluated intraoperatively to avoid this complication. Non-union and delayed union are possible complications of any osteotomy procedure. However, proper attention to the performance of the osteotomy as well as to the fixation will limit the risk of this complication. Intraoperative fracture of the dorsal shelf of the capital fragment is one of the more common complications although it is rare. The most common location of an intraoperative fracture is at the proximal dorsal drill hole site. This is reasoned to be secondary to improper placement of the proximal screw or inadequate countersink-

ing of the proximal drill hole leading to the uneven force on the dorsal cortical surface.

### Summary

Considering the benefits of rigid interfragmental compression, early ambulation, the avoidance of pin tract infections and excellent retrospective results, this modification adds considerably to the armamentarium of the

podiatric surgeon.

### Bibliography

- Austin D, Leventen E: A new osteotomy for hallux valgus. *Clin Orthop* 157:25, 1981.
- Kelikian H: *Allux Valgus, Allied Deformities of the Forefoot and Metatarsalgia* WB Saunders Co, Philadelphia, 1965.