

MODIFICATIONS OF THE AUSTIN HALLUX VALGUS REPAIR (KALISH OSTEOTOMY)

Stanley R. Kalish, D.P.M.

INTRODUCTION

In 1983, the Kalish Osteotomy was first presented. Its introduction was met with a normal amount of skepticism as osteotomies of the first metatarsal were not considered revolutionary.

Kelikian reviewed more than 100 procedures for the correction of hallux abducto valgus. The podiatric literature has added its share of osteotomies, derotational transposition osteotomy (DRATO), SCARF, Vogler, and others. Some of these are still used today while others have been discarded because of their many complications.

In 1962, Dr. Dale Austin presented a paper which was later published in 1981 describing a distal metaphyseal first metatarsal osteotomy (Fig. 1). The osteotomy was a horizontally directed 60 degree V displacement osteotomy. The advantage of the osteotomy as cited by Austin and Leventen in *Clinical Orthopedics and Related Research* in 1981 indicated intrinsic stability of the osteotomy without fixation and early ambulation without casting. They reported a low rate of recurrence of the deformity. The procedure was well accepted by podiatric surgeons and is a commonly performed operation today.

The disadvantages of the Austin Procedure:

- 1) osteotomy displacement
- 2) malposition
- 3) delayed union, hypertrophic bone formation, and nonunion
- 4) Kirschner wire displacement and pin tract infections if fixated
- 5) limitation of first metatarsophalangeal joint range of motion.

The Kalish modification addresses the complications of the original Austin procedure (Fig. 2). By creating a 55 degree osteotomy which is intrinsically more stable and by adding rigid internal fixation in the form of two parallel 2.7 mm cortical bone screws, the Austin osteotomy has been greatly improved. Patients have a stable 55 degree well fixated osteotomy which has been scientifically created with the axis guide principle. They

have no Kirschner wire infections as all hardware is now internal (Fig. 3). Earlier range of motion exercise and immediate ambulation are permitted, thus avoiding joint limitus. Patients are able to bathe in 10 days and are encouraged to return to closed shoes in 2 to 4 weeks.

INDICATIONS

The indications for the Kalish osteotomy are similar to those originally described by Austin. In our experience and in studies currently underway by Drs. Downey and Malay at the Pennsylvania College of Podiatric Medicine, the Kalish osteotomy may be used to correct larger degrees of metatarsus primus adductus than was originally recommended. This increase in parameters is permitted by the increased stability and rigid internal fixation of the osteotomy allowing greater lateral displacement of the capital fragment. However, care must be taken to avoid the troughing effect common to those osteotomies of greater than 18 degrees (Fig. 4). Complications from this effect include fracture of the metatarsal, rotary instability (as the lateral cortex rotates in the plantar medullary canal), and inability to correct high proximal articular set angles with a single cut.

Pelligrino in the *Journal of the American Podiatric Medical Association*, 1986, correctly observed that some degree of PASA will be corrected by unidirectional Austin type osteotomies. In attempting to stretch the indications for this procedure we occasionally transfer the adductor tendon which, according to Beck in *Journal of the American Podiatry Association*, 1972, and Ruch 1982 (personal communications) will reduce intermetatarsal angles.

In our initial study of 64 patients we found an exceptionally high frequency of hallux varus (5 out of 64 cases) and hallux adductus. This we attributed to the universal transfer of the adductor tendon in our earlier studies. However, our dissection technique continues to transect the fibular sesamoidal ligament and mobilize the fibular sesamoid. The adductor tendon is mobilized and sacrificed in those situations where we do not desire additional intermetatarsal correction.

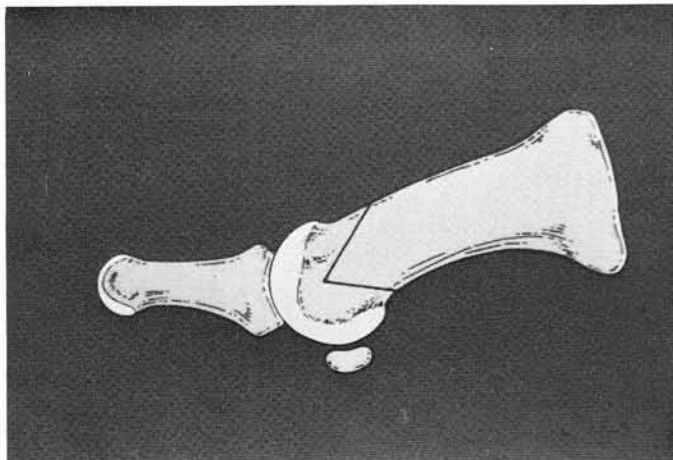


Fig. 1. Sixty degree horizontal "V" osteotomy described by Austin.

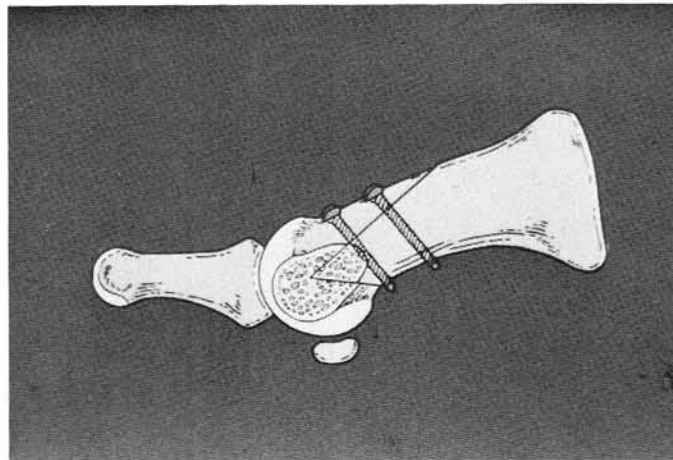


Fig. 2. Fifty-five degree Kalish modification of Austin procedure.

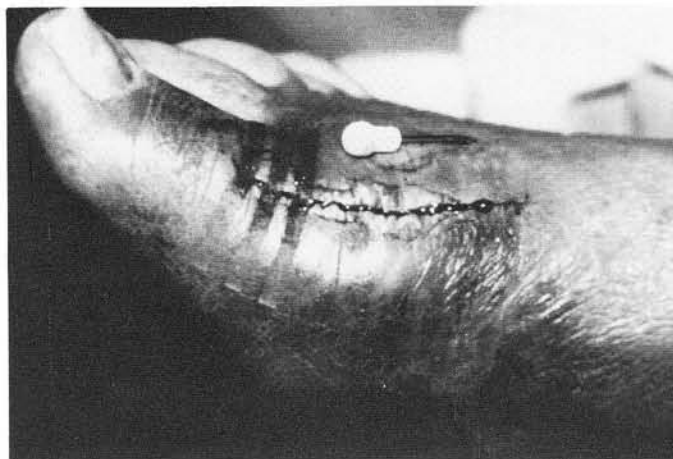

Fig. 3. Pin tract infection seen with external Kirschner wire fixation.




Fig. 4. Troughing effect seen with excessive lateral displacement of metaphyseal osteotomies.

The following indications have been identified.

1. Hallux abductus angle greater than 15 degrees.
2. Metatarsus primus adductus 15 degrees or less.
 - A. Without adductor transfer.
 - B. Metatarsus primus adductus 15-18 degrees with adductor tendon transfer.
3. Pain-free range of motion with no significant osteophytes.
4. Absence of severe degenerative joint disease.

TECHNIQUE

Using the concepts of anatomic dissection of the first metatarsophalangeal joint, an approximately 7 cm curvilinear incision is angled over the first metatarsophalangeal joint. This incision is slightly longer on the proximal segment to accommodate the longer dorsal cut (Fig. 5). The incision is deepened through the skin and subcutaneous tissue to the level of the first metatarsophalangeal joint capsule. Dissection is carried down

to the floor of the first interspace. The adductor hallucis tendon is released and tagged for possible use (Fig. 6). The fibular sesamoidal ligament is transected. The great toe is adducted, and the sesamoidal plate should move back beneath the metatarsal head.

Dissection through the medial side of the joint is carried along the deep fascia and capsule to the plantar aspect of the joint. An inverted L capsular incision is then performed. An intact plantar medial blood supply is maintained by this capsulotomy. After minimal resection of the medial eminence of the first metatarsal, a smooth .045 Kirschner wire is placed through the medial to lateral cortex of the first metatarsal head to serve as an apical axis guide (Fig. 7). By appropriate placement of the axis guide the surgeon is able to plantarflex, dorsiflex, or maintain the current level of the first metatarsal head. Additionally, either elongating, shortening, or no positional alteration of the first metatarsal length may be obtained by apical axis guide position (Fig. 8).

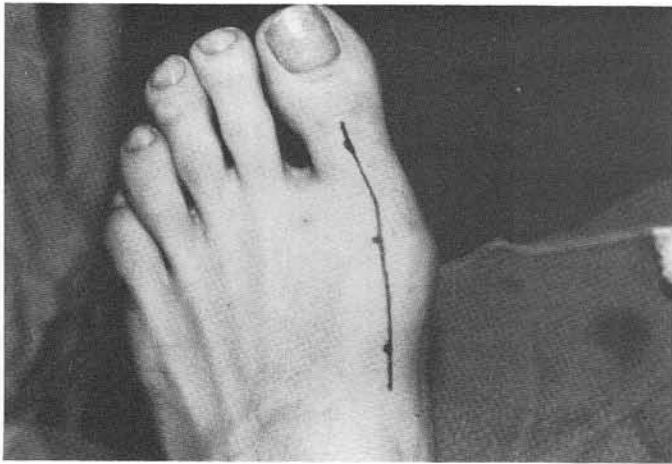


Fig. 5. Skin incision for Kalish osteotomy.

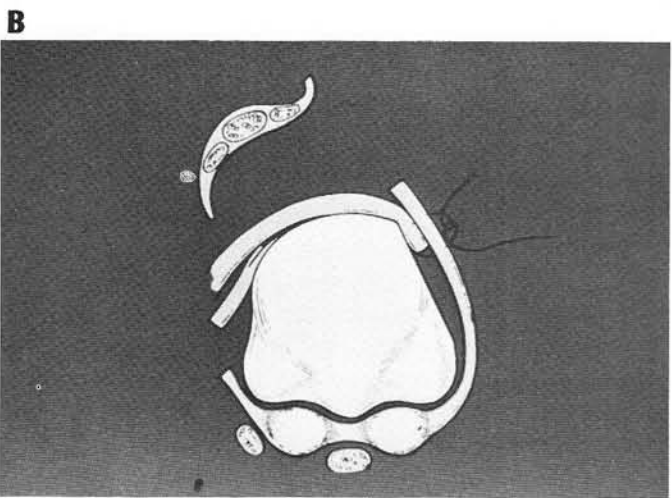
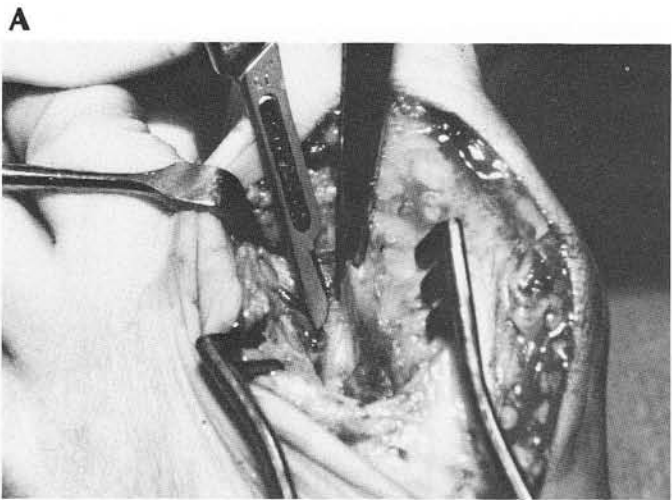


Fig. 6 A., 6B. Adductor tendon transfer, and schematic diagram showing axial sesamoid position after fibular sesamoidal ligament is transected.




Fig. 7. Axis guide positioning for neutral, plantarflexion and dorsiflexion displacement of metatarsal head.

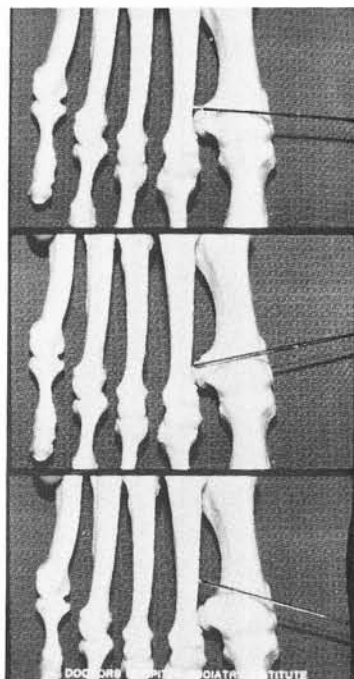


Fig. 8. Axis guide positioning for neutral, lengthening, or shortening osteotomy.

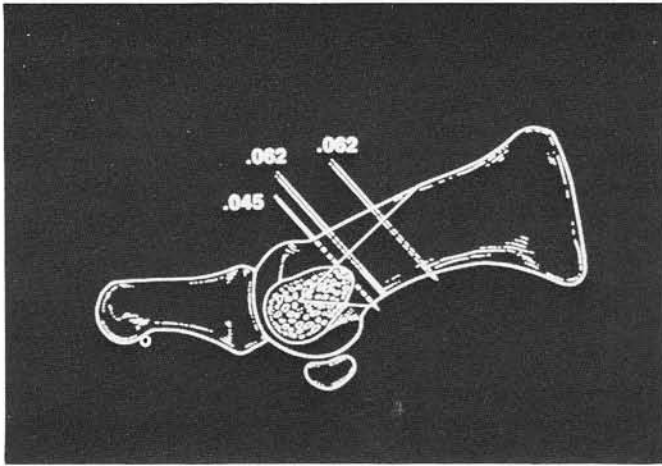


Fig. 9. Placement of temporary Kirschner wires prior to permanent screw fixation.

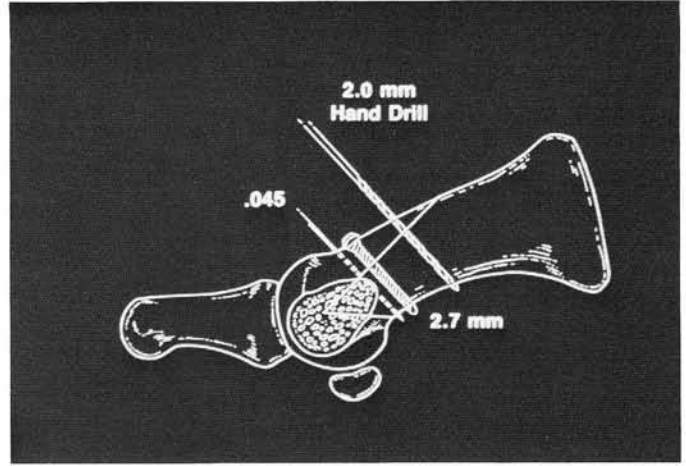


Fig. 10. Osteotomy with one 2.7 mm screw and one .045 and one .062 Kirschner wire still in place.

THE OSTEOTOMY

Using the apical axis guide, a 55 degree V osteotomy is created with the sagittal saw. The dorsal osteotomy is created first. The dorsal wing must be long enough to accommodate two 2.7 mm screws or one 2.7 mm screw and one 2.0 mm screw (Figs. 9, 10). The plantar cut is made after completion of the dorsal cut. We feel the stability of the more critical dorsal cut is insured by this sequence.

The apical axis guide Kirschner wire is removed and the head is distracted and moved laterally. Careful observation of the joint is made to achieve maximum correction. A negative intermetatarsal angle must be corrected if this is seen to occur when the head is repositioned laterally on the metatarsal neck. Greater than 50% displacement of the metatarsal can cause the undesirable *troughing effect*. Small amounts of PASA deviation may be corrected by medial compression of the osteotomy.

FIXATION

Prefixation I

After translocation of the capital fragment, prefixation wires are placed through the osteotomy. A .045 Kirschner wire is placed distally across the dorsal cut in a dorsolateral to plantar medial direction. It crosses the plantar aspect of the metatarsal medially proximal to the plantar wing of the osteotomy.

This .045 Kirschner wire serves two functions (Figs. 9, 10):

1. Stabilization of the osteotomy is accomplished.
2. Direction for later screw placement.

A proximal .062 Kirschner wire (1.9 mm) is then placed and will serve as the second screw position (Figs. 9, 10). This leaves the middle portion of the osteotomy available for the central screw. This is the most important of the fixation points especially when a second screw cannot be placed.

Stage I

A .062 Kirschner wire (1.9 mm) is introduced in the central position and immediately withdrawn. The technique described for osteosynthesis as follows:

1. 2.0 mm central drill hole
2. 2.7 mm overdrill
3. Countersink
4. Depth gauge (12-18 mm range)
5. Tap 2.7 mm
6. Sink appropriate screw

At this point we have the .045 wire, the 2.7 mm screw, and the .062 Kirschner wire. The second .062 wire is removed and the identical technique used for placement of the second screw.

Countersinking is especially important in preventing dorsal wing fracture.

Stage II

The use of a 2.0 mm screw as the second screw as proposed by Dr. Thomas Cain has its merits in small bone or in those situations where the osteotomy was accidentally cut too short (Fig. 11).

Closure

The adductor hallucis tendon transfer may be performed if additional intermetatarsal correction is desired. Capsular correction by capsulorrhaphy is rarely indicated. All layers are approximated with 3-0 and 4-0 absorbable suture of Dexon or Vicryl. Skin closure is generally accomplished with 5-0 absorbable suture.

RETROSPECTIVE STUDY

Two hundred and sixty four (264) osteotomies have been performed at the Podiatry Institute since 1983. The first 64 patients were intensely studied by questionnaire interview and objective examinations. Preliminary results revealed the following:

1. 92% of those patients questioned indicated a better result than expected.
2. 98% indicated no recurrence of the deformity.
3. 98% had no screw discomfort.
4. Postoperative edema was less than 6 weeks.

COMPLICATIONS

Hallux varus is the most common complication observed in the Kalish modification (Fig. 12). Five out of 64 patients observed in the initial study and three out of 200 patients in the later studies were observed to suffer from hallux varus. All were associated with adductor tendon transfer and/or medial capsulorrhaphy.

It is imperative that hallux first metatarsal and tibial sesamoid position be evaluated intraoperatively to avoid these complications. Patients with less than 15 degree intermetatarsal angles preoperatively should not undergo adductor tendon transfer.

Stress fractures occurred in two out of 264 cases and were found in the second metatarsal. The exact cause is not certain but may be related to inappropriate dorsal displacement of the first metatarsal head. Fracture of the dorsal shelf occurred in seven out of 264 osteotomies and were treated by forefoot fiberglass splinting in combination with the Darco shoe.

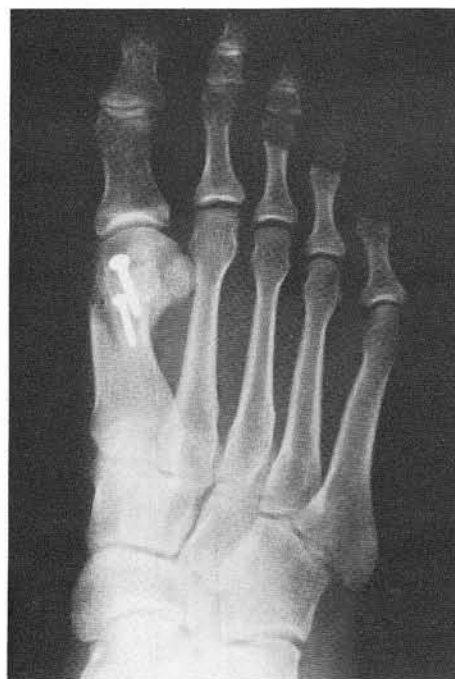

Fig. 11. Fixation with one 2.7mm and one 2.0mm screws.

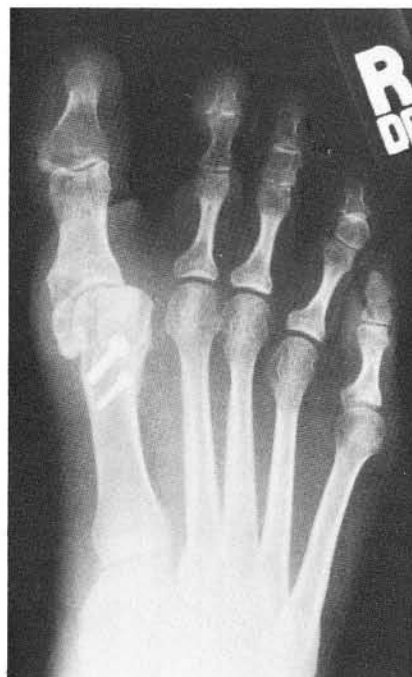

Fig. 12. Hallux varus following Kalish procedure.

Table 1

OBJECTIVE FINDINGS (64 PATIENTS)

	Preop	Postop	Average Correction
Metatarsus primus adductus	14 degrees	3 degrees	11 degrees
Hallux abductus angle	30 degrees	16 degrees	14 degrees

Careful planning of the osteotomy length and proper countersinking of screw heads will avoid this complication. Nonunion and delayed union have not been observed in this study.

CONCLUSIONS

The benefits of modifying the Austin hallux valgus correction by the Kalish osteotomy can be summarized as follows:

1. Rigid internal fixation by two 2.7 mm bone screws provide primary bone healing.
2. The osteotomy is intrinsically stable due to the 55 degree V angulated osteotomy.
3. No pin tract infections as all hardware is internal.
4. The procedure has high patient acceptance.

5. Full range of motion with early active and passive dorsiflexion.
6. Bathing in 10 to 14 days is permitted and the patient can return to closed shoes in 2 to 4 weeks.

References

- Austin D, Leventen : A new osteotomy for hallux valgus. *Clin Orthop* 157:25, 1981.
- Kelikian H: *Hallux Valgus and Ally Deformities of the Forefoot and Metatarsalgia*. Philadelphia, WB Saunders Co, 1965.
- John A. Ruch, D.P.M. and Thomas Cain, D.P.M.: personal communications, 1988.
- Harry Vogler, D.P.M.: personal communications, 1987.