

# PAN METATARSAL HEAD RESECTION: INDICATIONS AND USES IN FOREFOOT RECONSTRUCTION

E. Dalton McGlamry, D.P.M.  
Dennis E. Martin, D.P.M.

Since Hoffman's original description in 1911, pan metatarsal head resection has proven to be an effective and versatile procedure in treating forefoot deformity<sup>1</sup>. His description included an accurate description of the rheumatoid forefoot (Fig. 1 A-C). Hoffman's original procedure consisted of excision of all the metatarsal heads and, as needed, part of the neck through one plantar transverse incision. He astutely recognized the need for aggressive osseous resection to allow adequate soft tissue relaxation and realignment of the digits on the metatarsal stumps.

Since that time, the procedure has undergone several technical modifications and its indications have been broadened. The procedure has been classically used to treat the deformed rheumatoid forefoot. This is still one of the important applications of the procedure. Encouraged by this success in the rheumatoid patient, pan

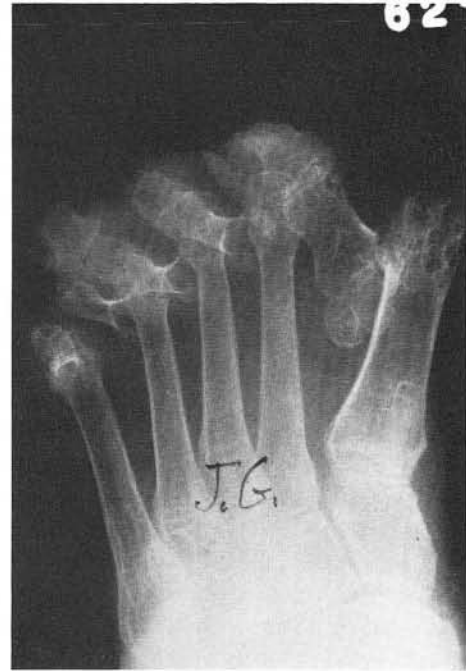

Fig. 1B.

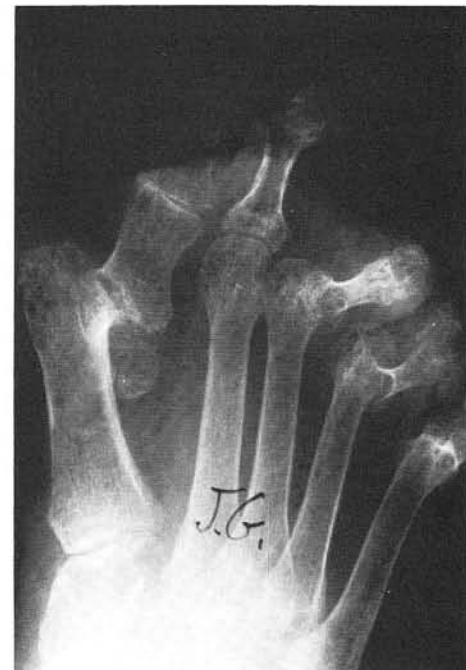

Fig. 1C.

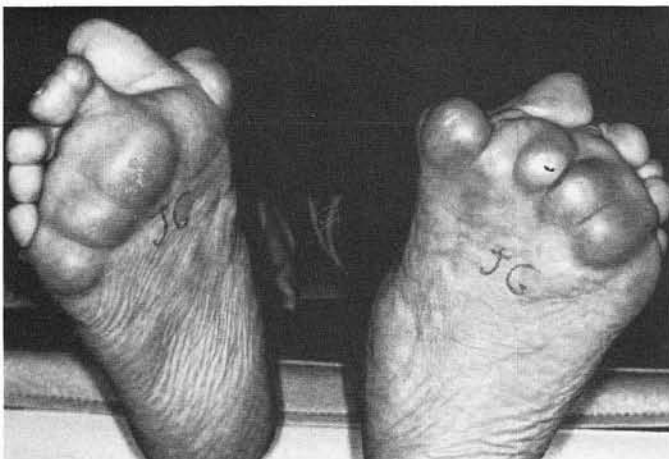

Fig. 1A-C. Illustrates severe rheumatoid forefoot deformities.

metatarsal head resection has been adapted to manage a variety of forefoot derangements of other causes. Included in this latter group are the diabetic Charcot foot, the iatrogenically deformed foot, nerve entrapment or causalgia-like syndromes, and biomechanically related metatarsal derangements.

Jacobs was the first to describe the pan metatarsal head resection in the treatment of diabetic feet<sup>2</sup>. He performed the procedure on twelve diabetic feet with varying degrees of insensitivity and ulceration beneath the metatarsal heads. It is not uncommon to see the patient who has undergone previous ray resection for mal perforans ulceration to now present with ulceration beneath adjacent metatarsal heads. McGlamry and Banks presented several patients who, following previous foot surgery, went on to develop extensive Charcot changes at adjacent and more proximal joints<sup>3</sup>. Pan metatarsal head resection can recreate an equal distribution of weight across the ball of the foot, while allowing existing ulcers to heal.

Unfortunately, iatrogenically induced forefoot deformity is an all too familiar scenario. When performing digital and metatarsal surgery, we hope to obtain a functional, asymptomatic foot postoperatively. However, this is not always the case. There will be times when the original pain or deformity returns or an unexpected deformity develops. These unwanted results can occur for a variety of reasons, including inappropriate choice of surgical procedure, postoperative complication, or poor postoperative patient compliance. Regardless of the cause, the patient is often left with an apulsive, deformed foot requiring further surgical intervention. The pan metatarsal head resection can be used to restore a balanced forefoot loading, and reestablish a pain free range of motion at the metatarsophalangeal joints.

Nerve entrapment or causalgia-like symptomatology is often times associated with iatrogenic deformities. In a previous paper, the authors described the above scenario as it occurs in both the structurally deformed as well as the minimally malaligned foot<sup>4</sup>. If for any reason a surrounding nerve has been damaged, either directly or indirectly, it can be subject to one or more of several pathological processes. As the nerve begins its regenerative process, the axonal branching may become entrapped within its own or surrounding scar tissue. This can produce ischemic and compressive changes resulting in painful paresthesia. The nerve can also become adhered to adjacent tendinous, ligamentous, or other periarticular structures leading to a painful tethering or traction phenomenon. In instances where the plantar fat pad has been disrupted, the nerve or its regenerated branches will be subjected to the direct unprotected

forces of weight bearing. This can produce persistent, painful stimulation with each step.

Through a series of case presentations we will demonstrate these various applications of the pan metatarsal head resection. As we discuss the procedure, recent advances in instrumentation and technique will be presented.

## SURGICAL CONSIDERATIONS

There are numerous, almost equally important surgical considerations in pan metatarsal surgery. The planning of incisions, the technique of surgical exposure, the accurate planning and assessment of length pattern of resection, the preparation of the end of the stump, the use of Kirschner wires for an appropriate period of time, and the planned instrumentation. Adjunctive procedures provide an additional important consideration.

### Incisions

Numerous incisions have been used in the past. Today, our incisional preferences include the five dorsal longitudinal digital incisions or the plantar transverse incision. While the five dorsal longitudinal incision approach is preferred, there is a definite place for the plantar transverse incision in the patient with severe dorsal contracture and extremes of deformity.

The five dorsal digital incisions extend proximally to the level of the junction of the metatarsal head with the neck, except for the first and fifth rays where the incisions can be any length. It is important that the central three incisions extend no further proximally since the creation of long peninsulas of soft tissue will invite vascular compromise.

The advantage of the five dorsal incisions is that each incision is placed directly over the ray and lies midway between medial and lateral neurovascular supply for the toe. Dissection is taken down directly to the tendon and follows the hood fibers medially and laterally around the ray. This facilitates exposure without compromise to the neurovascular supply. An added advantage of the five incisional approach is the easy access to the proximal interphalangeal joints through the same incisions.

The plantar transverse skin incision, on the other hand, provides a direct access to the five metatarsal heads through the same incision. The skin and fatty incision is transverse, but the incisions into the individual rays are made longitudinally. The transverse incision facilitates

excision of redundant plantar soft tissue. This can be very beneficial in helping to keep the toes from riding dorsally. Additionally, the plantar approach is a very rapid approach once one is thoroughly familiar with the technique. A disadvantage of the plantar approach is that additional incisions have to be made for correction of related digital deformities.

### Surgical Exposure

Through the dorsal longitudinal digital incisions, dissection is carried down through the superficial fascia to the level of the extensor hood fibers. Soft tissues are then separated medially and laterally to the floor of the interspace. The extensor tendon is undermined, Z-plasty split, and retracted proximally and distally. The metatarsophalangeal joints are all opened by longitudinal incisions and the medial and lateral collateral ligaments undermined and sectioned. A metatarsal elevator is then used to deglove all metatarsal heads and necks plantarly, dorsally and laterally. Such exposure is carried out for all metatarsal heads at one time. Having all metatarsal heads exposed at once facilitates proper planning and execution of appropriate resections to follow.

### Resection of Bone

It is most important that the surgeon understands the appropriate pattern of weight bearing for metatarsals. Typically the second metatarsal should remain the longest followed in descending lengths by the first, third, fourth, and fifth (2-1-3-4-5). Since the second metatarsal bone descends from the highest point of the arch, it would likely bear no weight unless it remains longest.

Once resection has been effected of all metatarsals, the rearfoot is placed in neutral position and the forefoot loaded evenly. The stumps of the metatarsals are palpated for any prominence. If a single metatarsal protrudes below the others it can be filed slightly to eliminate its prominence.

Once satisfied with the length pattern, a 17mm metatarsal elevator is introduced as a retractor and a high speed rotary burr used to smooth the stump of the metatarsals.

One should be certain that adequate bone has been resected to relieve all soft tissue tension. Resection of inadequate bone is the most common cause for failure of the procedure.

### Related Digital Procedures

Digital correction most often involves arthrodesis of the three middle toes and arthroplasty of the fifth toe. Arthrodesis provides a stable lever arm on which the flexors can act to help stabilize the metatarsophalangeal joints. One should avoid arthrodesis of the fifth toe since its rigidity can create difficulties from shoe irritation.

Digital procedures are planned so that they are executed at the same time as the metatarsal procedures. One should be able to plan all bone resection so that the power saw need only be picked up once, and the power burr but once.

A great deal of time is saved by carefully planning the surgical approaches.

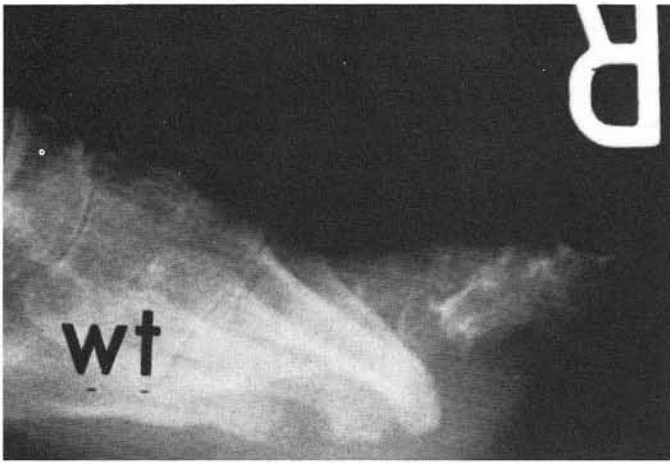
### Kirschner Wires

Kirschner wires are driven out the end of the toes from the interphalangeal joints and retrograded proximally across the metatarsophalangeal joints. A one centimeter space is maintained at the metatarsophalangeal joint. The wires are typically maintained for six weeks, but if x-rays at 3 to 4 weeks show collapse of the metatarsophalangeal joint space it is best to retract the wires across the joint into the toes and to begin passive range of motion exercises. Leaving the wires across the metatarsophalangeal joint more than four weeks can result in stiffness of the joints if the one centimeter space has closed.

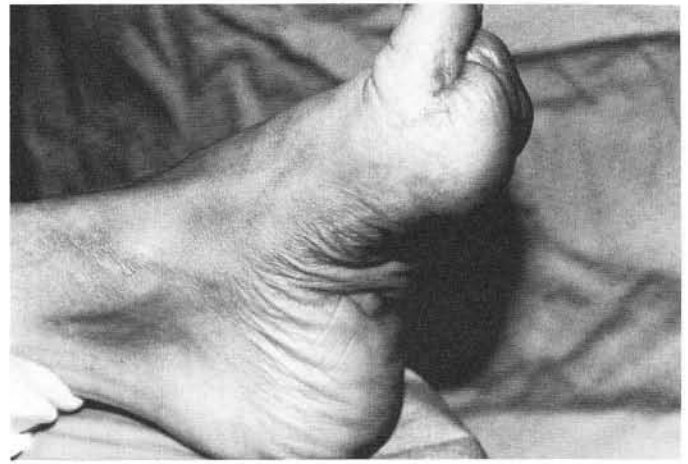## **SURGICAL APPLICATIONS OF PAN METATARSAL RESECTION**

There is an almost unlimited number of forefoot deformities which lend themselves to reconstruction using pan metatarsal head resections as a major component of the surgery. These include the rheumatoid foot, the iatrogenically deformed foot, the traumatically compromised forefoot, the diabetic forefoot deformity, and the chronic pain forefoot involving nerve entrapments, nerve tethering, and nerve constrictions in beds of tissue induration and scarring.

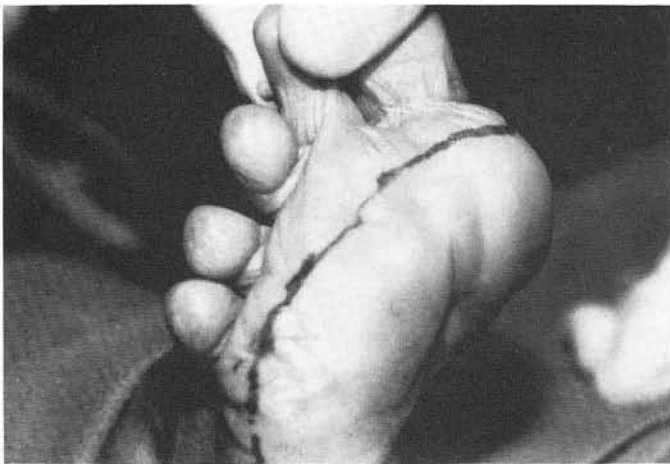
The cases which follow will illustrate specific applications of pan metatarsal head resections to a number of these conditions.



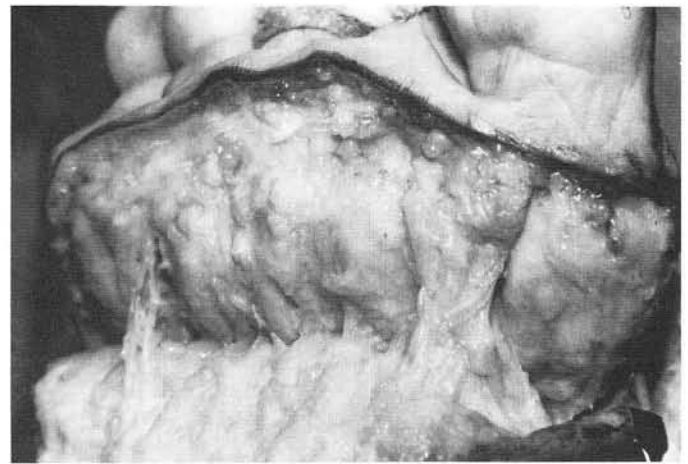**Fig. 2 A-H.** Illustrates severe dorsal contractures associated with forefoot rheumatoid deformities. Severe dorsal contractures makes plantar approach to surgery most feasible. **A.** Lateral radiograph, note severe plantar protrusion of metatarsals.



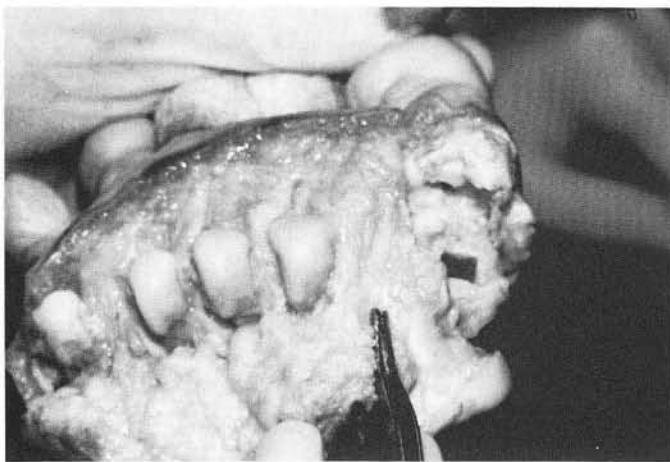
**B.** Medial view of foot shows plantar protrusion of metatarsals.



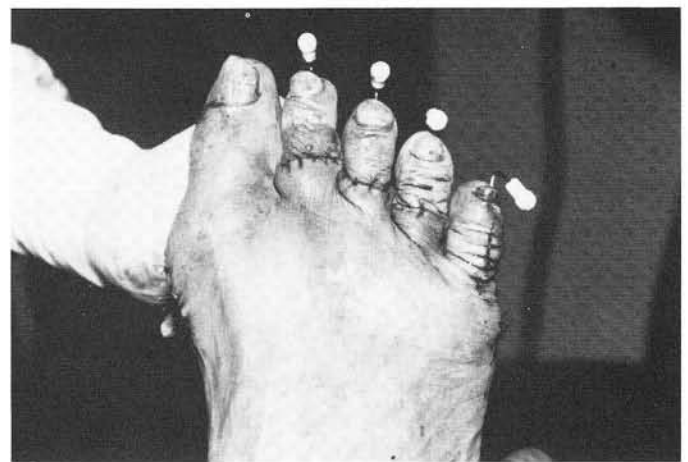**C.** Transverse plantar incision through skin and fatty layer incorporates medial and lateral wings to facilitate exposure.



**D.** Neurovascular bundles have retracted to shelter between metatarsals making possible their protection.

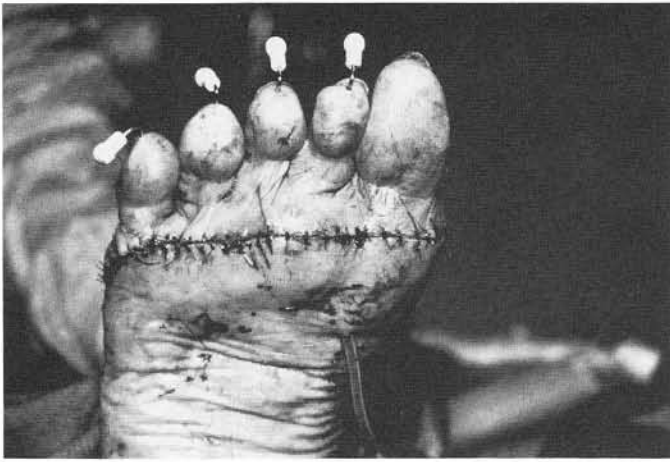

**E.** Incisions into individual rays is by longitudinal incisions.

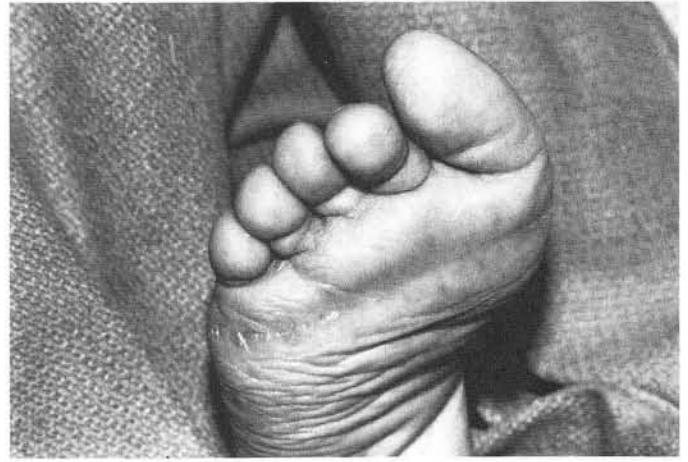


**F.** Related procedures such as digital stabilizations must be done through separate incisions, disadvantage of plantar approach.





G. A surgical drain is recommended since large flap may be vulnerable to disruption should hematoma occur underneath flap.



H. Supple plantar scar distal to weight-bearing ends of metatarsals is seen at two months following surgery.

## Rheumatoid With Severe Dorsal Contractures (Fig. 2 A-H)

This patient is a 40 year old white female with a 22 year history of rheumatoid arthritis seen on referral from Dr. David Wuertzer of Dothan, Alabama. Looking at the severe dorsal contracture of the metatarsophalangeal joints as evidenced on the lateral radiograph and the lateral clinical view, it is obvious that a plantar surgical approach provides the most direct access. Additionally it is obvious that redundant plantar tissue will need to be excised to prevent it from being an obstacle to maintenance of realignment (Fig. 2 A-B).

A transverse plantar skin incision is made at least 1/2" proximal to the web area (Fig. 2C). The incision has medial and lateral wings to facilitate dissection and to minimize stress on the soft tissues. The transverse portion of the incision is at least 1/2" proximal to the web areas. With dorsal contracture of the toes at the metatarsophalangeal joint, the neurovascular bundles retract into the space between the metatarsal heads. Keeping the incisions proximal to the web helps to avoid neurovascular structures.

The transverse skin incision is through the skin and the fatty layer. With the skin and fatty layer retracted, the neurovascular bundle can be seen lying between the metatarsal heads (Fig. 2D). Incisions into the individual rays are longitudinal. Once incised, all metatarsal heads are exposed quickly with a metatarsal elevator (Fig. 2E).

With a plantar approach to the metatarsal heads, any related digital procedures require separate incisions (Fig. 2F).

Kirschner wires are introduced quite easily from the plantar wound and are utilized as needed. Because of the large plantar flap a surgical drain is inserted before closure (Fig. 2G).

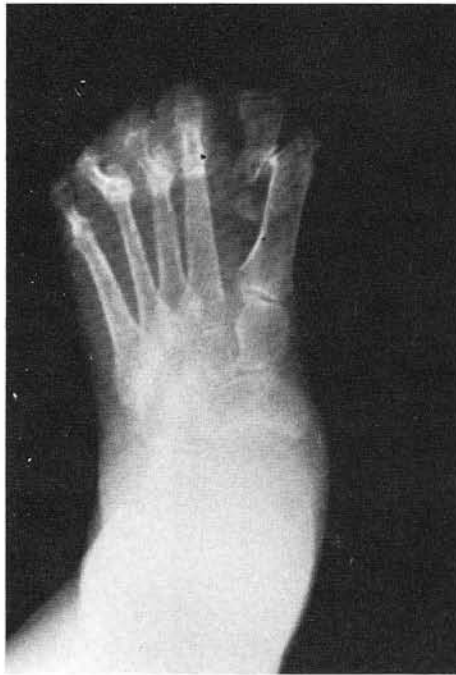The plantar scar should lie at a point well distal to the metatarsal stumps. In this instance a two month post operative view demonstrates a soft supple scar off the weight bearing area (Fig. 2H).

Evaluation of the patient 1 year post operatively showed no disturbance of sensation to any of the toes and with full sensation of the plantar tissues as well as satisfactory retention of alignment of the toes.

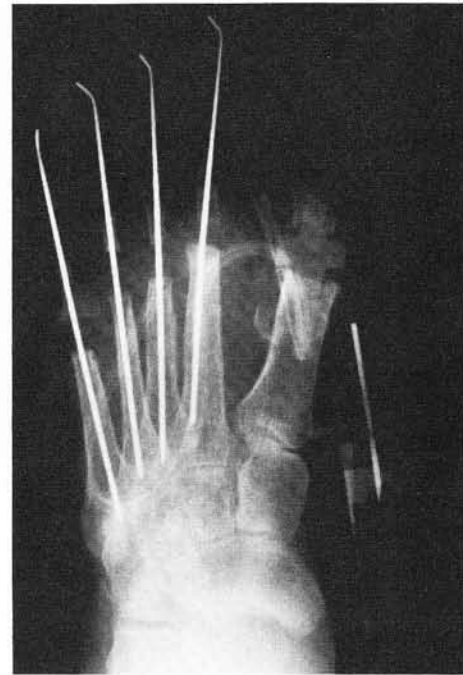## Rheumatoid Forefoot With Recurrent Plantar Sinus Tract (Fig. 3 A-C).

N.C. is a 52 year old white female with an 11 year history of rheumatoid arthritis. She has been hospitalized three times in the past ten months for treatment of an infected plantar sinus tract beneath the second metatarsal head. The metatarsophalangeal joints show total dislocation with telescoping of the toes over the metatarsal (Fig. 3A).

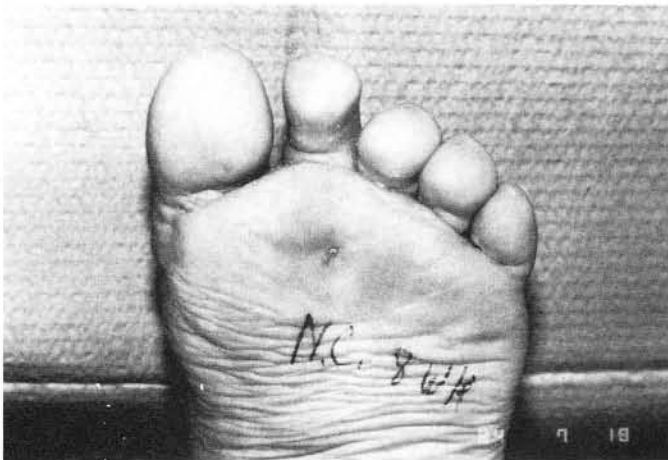Figure 3B shows post operative radiograph with surgical drain in place and with excellent demonstration of planned metatarsal length pattern, a 2-1-3-4-5 descending length configuration. Also observe the maintenance of space at the metatarsophalangeal joint. This is important to the flexibility of the joints after the Kirschner wires are removed. The wires were kept in place for six weeks, but would have been removed at 3-4 weeks if radiographs had demonstrated collapse of the metatarsophalangeal joint space.



**Fig. 3 A-C.** Severe rheumatoid foot with total dislocations of metatarsophalangeal joints. A. Preoperative dorsoplantar radiograph.



**B.** Immediately following surgery. Note excellent length pattern of metatarsals (2-1-3-4-5) descending length pattern.



**C.** Supple plantar surface of foot 8 weeks following surgery.

Eight weeks post surgery the plantar nodules and sinus tract show resolution (Fig. 3C).

#### Length Patterns Must Be Planned (Fig. 4 A-C)

T.S. is a 49 year old white female. She has previously undergone resection of the second, third, and fourth metatarsal heads and an implant arthroplasty of the first metatarsophalangeal joint.

Evaluating the painful forefoot, one is impressed with the unacceptable length pattern of the metatarsals. One

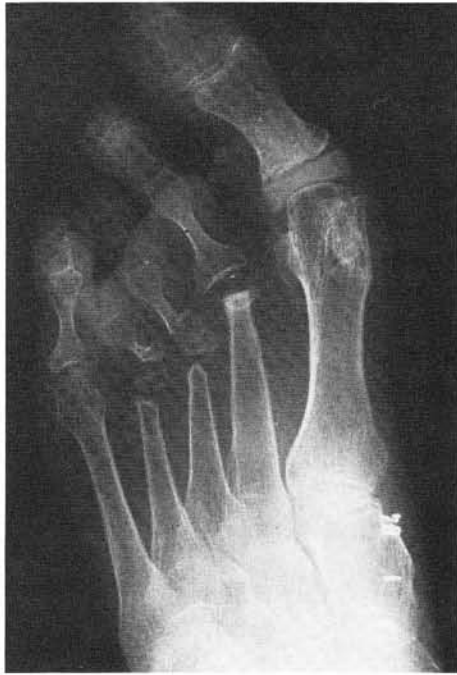should view metatarsal head resection as an all or none surgery. In this instance the first and fifth metatarsals are severely traumatized by their excessive length. Additionally, the hallux was allowed to remain longer than the second toe which almost certainly assures recurrence of the hallux deformity as well as crowding and displacement of the lesser toes (Fig. 4 A-B).

A post operative radiograph at 8 months shows an acceptable metatarsal length pattern. The patient at this time has been able to return to comfortable standing and walking with an accommodative orthotic device in the shoe (Fig. 4C).

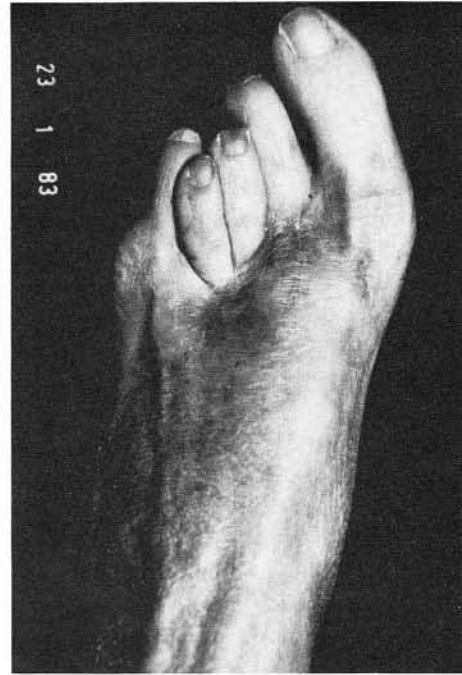
#### Reconstruction of Extensive Iatrogenic Forefoot Deformities (Fig. 5 A-E)

M.B. is a 62 year old white female who had undergone previous multiple forefoot surgeries bilaterally. Nothing, it seemed had been satisfactory. The patient had painful hallux limitus, bilaterally. The lesser metatarsophalangeal joints were stiff, painful on attempted motion, and were medially displaced. All the toes were angulated and medially adducted (Fig. 5 A-B). Note the totally unstable fifth toe and metatarsophalangeal joint.

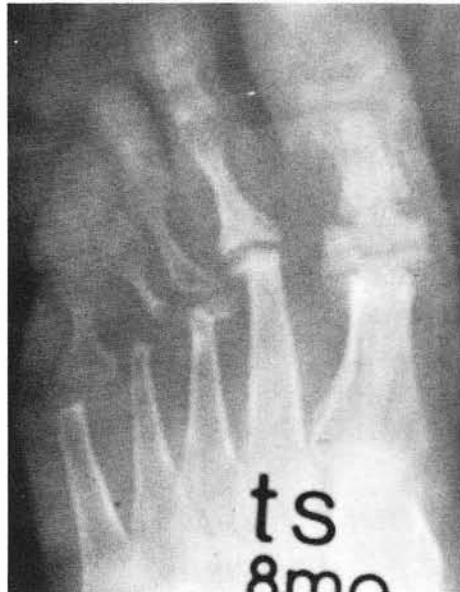Figures 5 C-D demonstrate pan metatarsal head resections with implant arthroplasty of the first joint and with syndactylization of the fifth toe to the fourth for stabilization.



**Fig. 4 A-C.** Iatrogenic Forefoot Deformities. A. Prior surgery has resulted in severe concentration of weight at first and fifth metatarsals. This length pattern results in no weight under second, third, and fourth metatarsals.



**B.** Shows contractures of floating toes 2-4 with recurrent hallux valgus deformity.



**C.** Postoperative radiograph at 8 months following surgery.

Figure 5E shows postoperative views of the left foot at two months and the right at five months. Both feet are asymptomatic and the patient has returned to walking for exercise. Note the excellent length pattern and the very satisfactory realignment of the toes and metatarsophalangeal joints.

### Iatrogenic Painful Rigid Forefoot (Fig. 6 A-D)

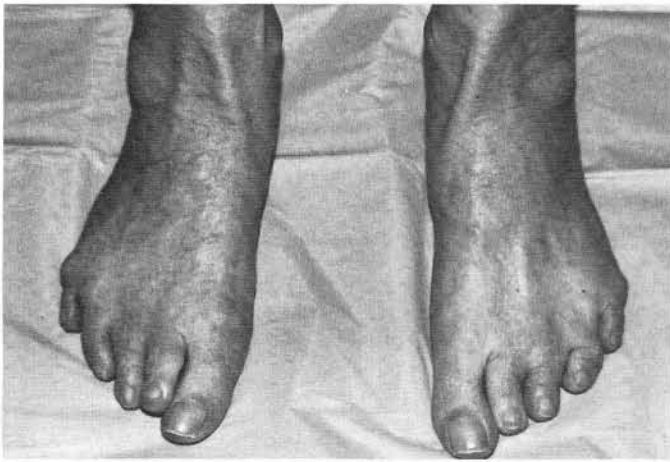V.A. is a 40 year old white female who consulted with Dr. Joseph Hauser following previous foot surgery including arthrodesis of the first metatarsophalangeal joint and subsequent shortening of the second, third, and fourth metatarsals and resection of the head of the fifth (Fig. 6 A-B). The patient was referred by Dr. Hauser for reconstructive surgery.

Plantar lesions were present and were painful despite weekly debridement and the wearing of a 1/2" plastizote insole. Any motion of the second, third, or fourth metatarsophalangeal joints produced exquisite pain.

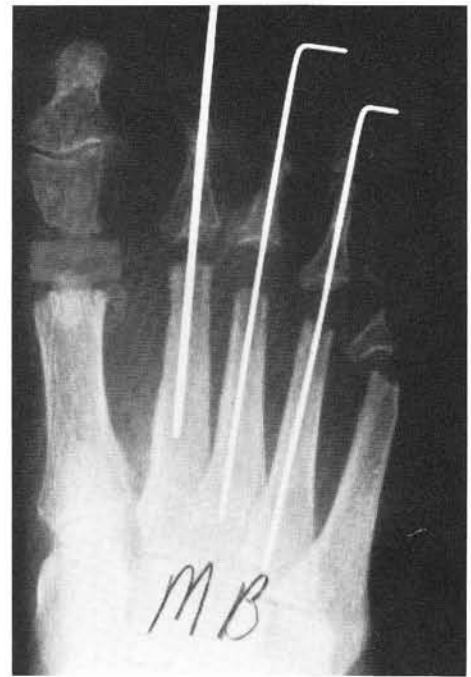Surgical reconstruction included implant arthroplasty of the first through fourth metatarsophalangeal joints following metatarsal head resections.

In order to have sufficient bone diameter to accept the implant stems, inadequate bone was resected (Fig. 6 C-D). Though the three and one-half month follow up evaluation was good, the two year evaluation was disappointing and a recommendation was made for additional bone resection from the bases of the second through fourth toes and removal of the lesser ray implants.

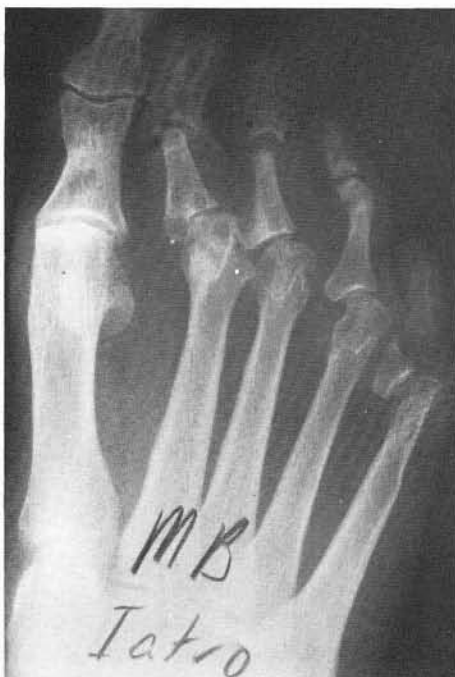Lesser metatarsophalangeal joint implants do not function well where they require placement under tension. A major lesson to be learned in pan metatarsal head resec-



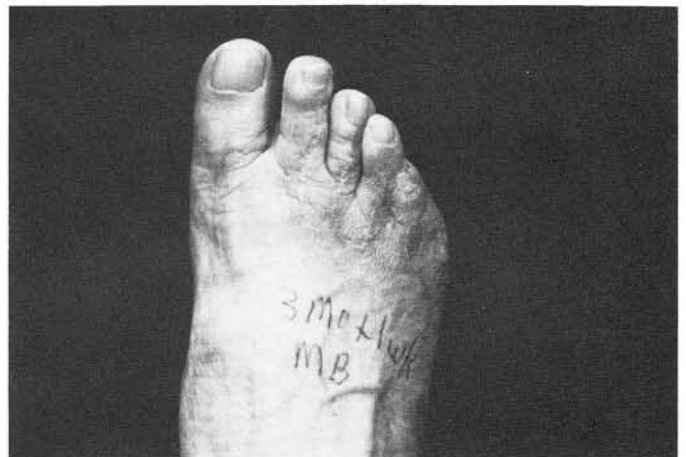
**Fig. 5 A-E.** Multiple, bilateral, forefoot deformities following earlier attempt at repair of hallux valgus and digital deformities. A. Clinical appearance of foot when patient first seen on referral.



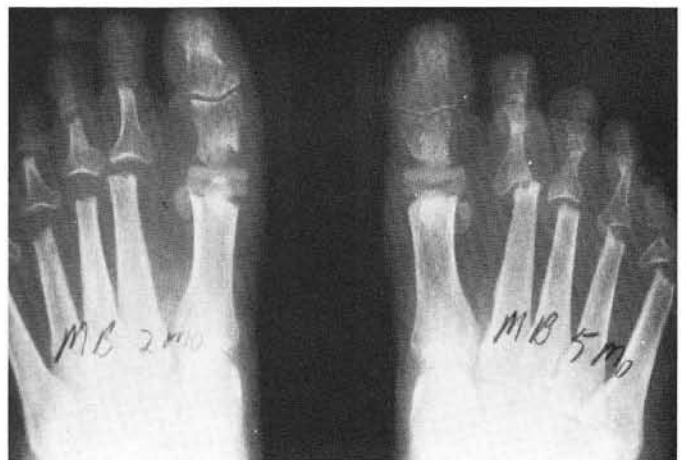C. Postoperative appearance three weeks after surgery.



B. Radiographic appearance at initial examination. Note total instability of fifth metatarsophalangeal joint.



D. Satisfactory alignment of right foot three months postoperatively.



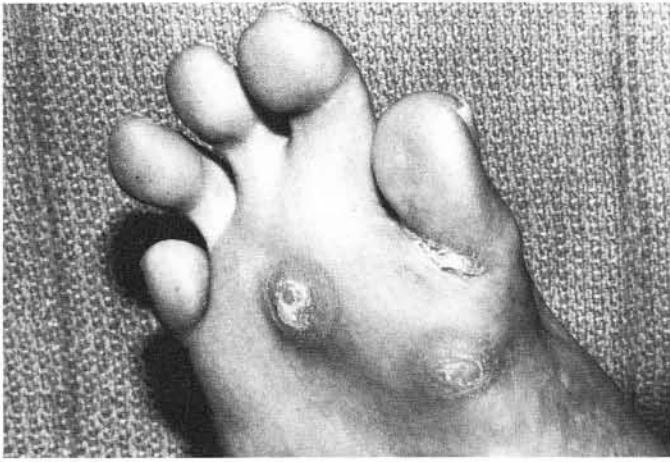
E. Post operative radiographs, 2 months left and 5 months right.

tions is that one must resect sufficient bone to relieve all soft tissue tension.

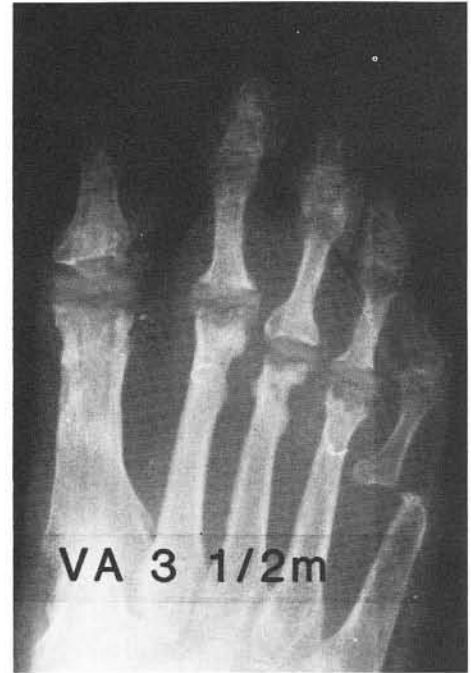### Diabetic Charcot Forefoot (Fig. 7 A-E)

N.S. is a 28 year old insulin dependent diabetic who was referred for reconstructive surgery by Dr. Anne Kinzer of Atlanta, Georgia. Prior to consulting Dr. Kinzer, the patient had undergone surgery to remove a tibial sesamoid after years of recurring mal perforans ulcers at that location. Following removal of the sesamoid, she devel-

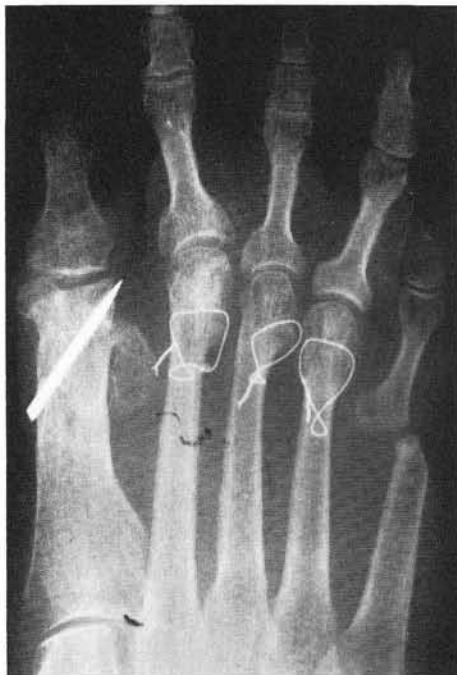



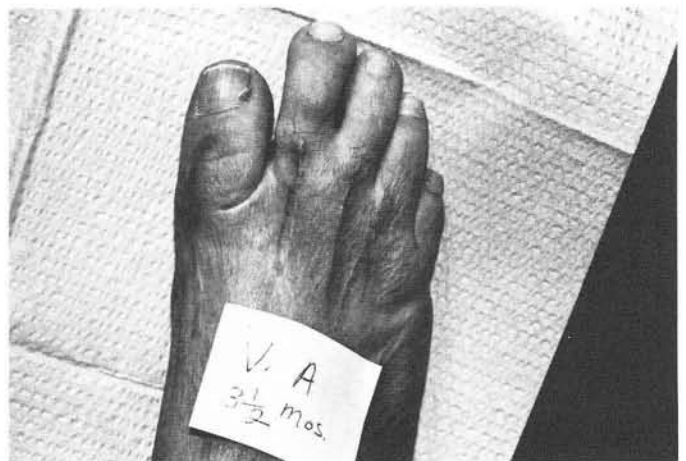**Fig. 6 A-D.** Iatrogenic rigid forefoot following first metatarsophalangeal joint arthrodesis and subsequent shortening of second, third, and fourth rays and head resection on fifth. **A.** Severe lesions despite weekly professional debridement.



**C.** Appearance of radiographs at 3 1/2 months following surgery.



**B.** Dorsoplantar view when patient initially seen.



**D.** Clinical appearance at 3 1/2 months.

oped a Charcot joint of the second metatarsophalangeal joint. Following healing of the second joint a similar Charcot collapse occurred at the third metatarsophalangeal joint. At the same time Charcot collapse of the proximal phalanx occurred at the first metatarsophalangeal joint.

When first referred to us, there was a recurrent mal perforans ulcer beneath the first metatarsal head and motion of the second and third metatarsophalangeal joints was almost non-existent. On weight bearing the

hallux floated and was responsible for a constantly recurring ulceration over the interphalangeal joint of the great toe (Fig. 7 A-B).

Surgical reconstruction included pan metatarsal head resections with Keller type arthroplasty carried out through five dorsal longitudinal incisions. No implant was used in the first metatarsophalangeal joint due to severe mixed neuropathy combined with rather spongy bone (Fig. 7C).

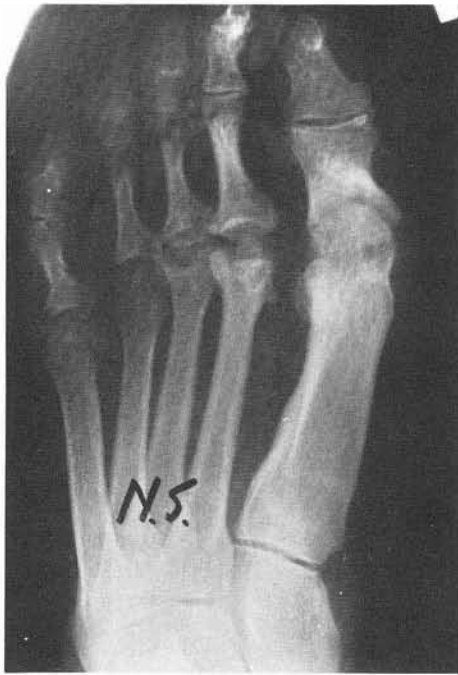
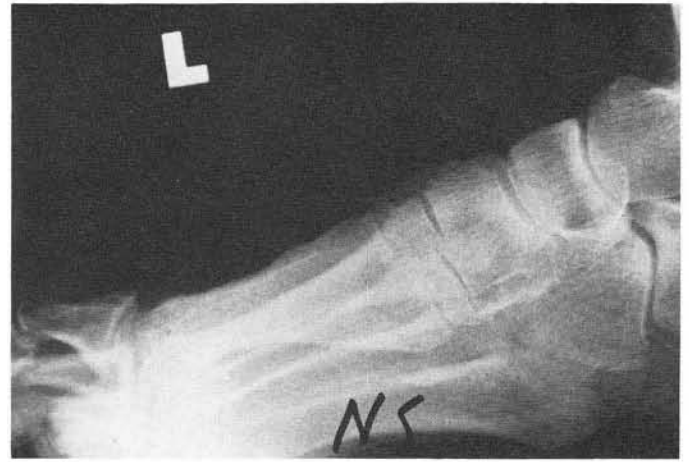
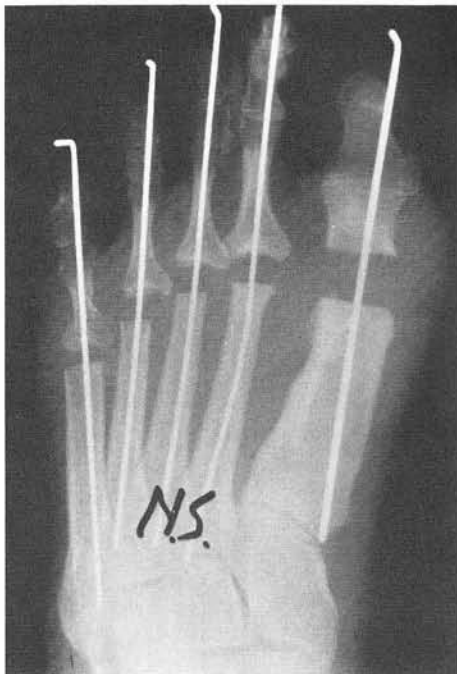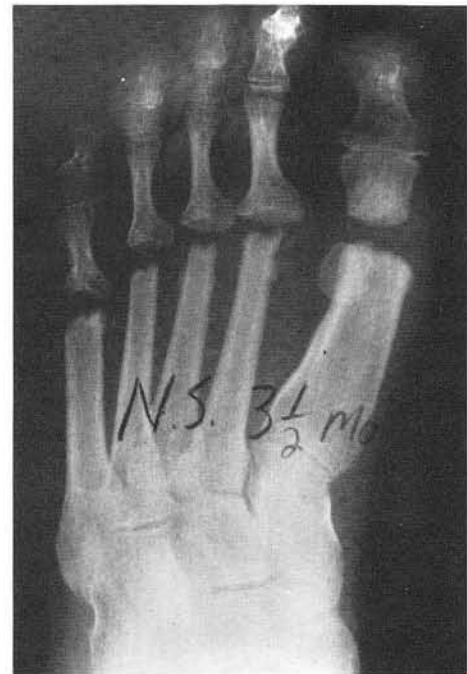Fig. 7 A-E. Diabetic Charcot joints of forefoot. A. Charcot second, third metatarsophalangeal joints followed tibial sesamoidectomy.



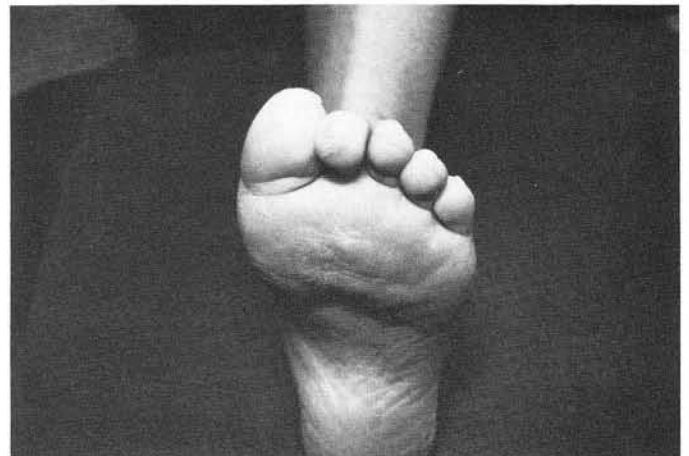
B. Lateral view shows dorsal contracture of hallux.



C. Post surgery excellent length pattern is illustrated with good preservation of metatarsophalangeal joint space.



D-E. Appearance of radiograph and plantar view of foot at 3 1/2 months post surgery.



At three and one half months, radiographs demonstrate an excellent length pattern of the metatarsals and quite even weight distribution. The second toe shows some contracture which subsequently needed stabilization arthrodesis (Fig. 7 D-E).

A most important consideration in this, as in all diabetic feet, was the determination of the circulatory status of the feet. This patient presented with considerable hyperemia of both feet resulting from pronounced autonomic (sympathetic) neuropathy. It was apparent that the mal perforans ulcers were a result of pressure combined with sensory neuropathy and not due to any deficiency in circulation. It is critical that a determination of circulatory status be made before any surgery is contemplated.

### Reconstruction of Iatrogenic Forefoot Deformities in Diabetic With Metatarsus Adductus (Fig. 8 A-G)

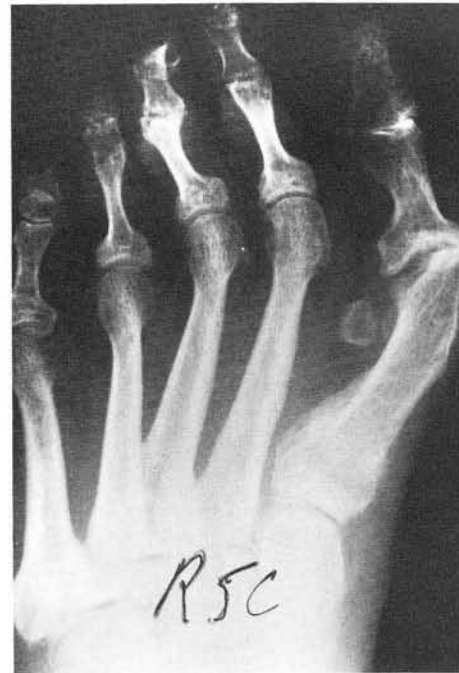R.S.C. is a 58 year old non insulin dependent diabetic who was initially seen on referral from Drs. Andy Peterson and William Kennedy of Sarasota, Florida. The patient had undergone earlier surgery to correct hallux valgus, hammertoes, and an unstable first metatarsal prior to seeking help from Drs. Peterson and Kennedy. The patient was referred for forefoot reconstruction.

Special surgical considerations included patient's diabetes, status of his circulation, the presence of neuropathy, rigidity of the toe deformities, a staked first metatarsal head, severe plantar protrusion of the second and third metatarsal heads, severe metatarsus primus adductus, and severe metatarsus adductus.

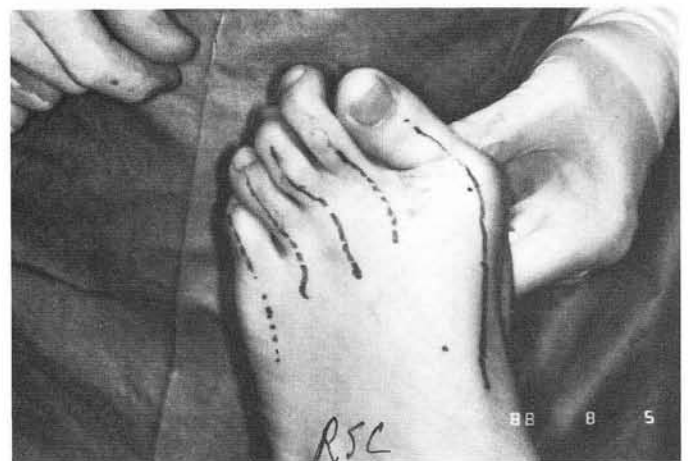
The patient's diabetes was found to be adequately controlled. Circulatory evaluation demonstrated significant hyperemia of both feet. Mixed peripheral neuropathy was present bilaterally. The staked first metatarsal head combined with degenerative joint disease and jamming of the second and third metatarsophalangeal joints contributed to a decision to relieve soft tissue tension by resecting metatarsal heads (Fig. 8A).

At the same time it was recognized that the presence of metatarsus adductus and metatarsus primus adductus necessitated an abductory and plantarflexory osteotomy of the first metatarsal base.

Figure 8B illustrates the incisional planning for five dorsal longitudinal incisions. All incisions are planned so as to fall centrally between blood supplies to each

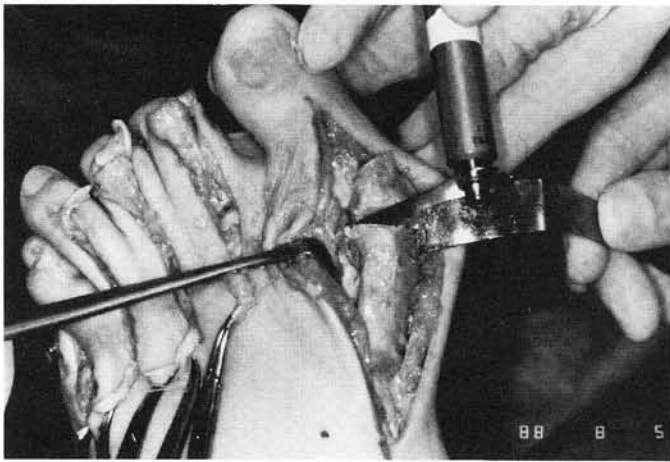


**Fig. 8 A-G.** Diabetic male with severe iatrogenic forefoot deformities.  
**A.** Radiographic appearance when first examined.

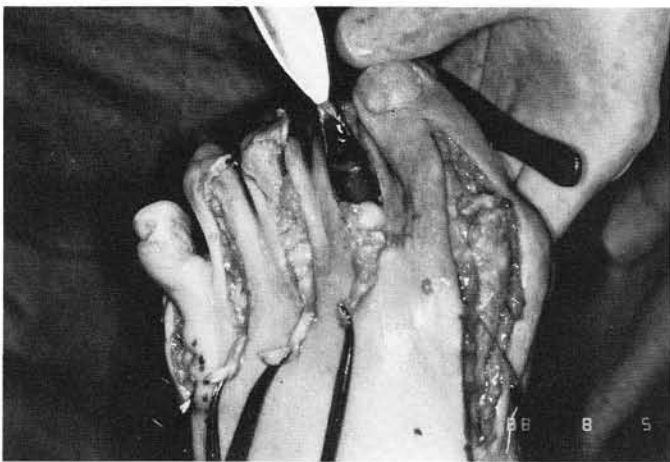


**B.** Skin incisions planned to avoid long peninsulas of tissue which could encourage soft tissue slough.

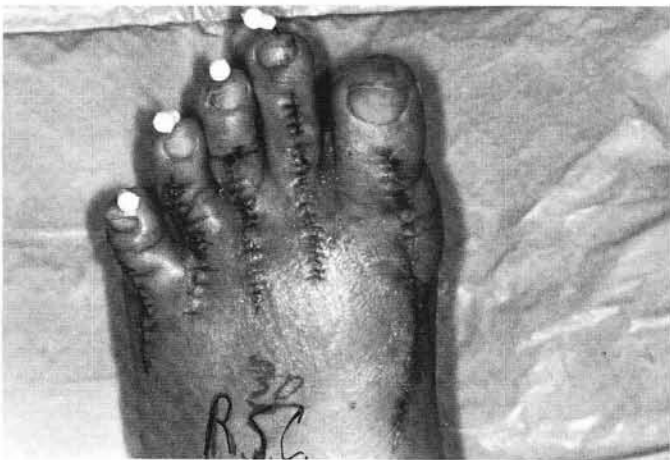individual ray. The first and fifth incisions can be of any length without jeopardizing blood supply. The central three incisions are planned so as to be out over the toes and to end proximally at the junction of the metatarsal head with the neck. This avoids long peninsulas of tissue which could encourage compromise of blood supply (Fig. 8B).



C-D. All incisions are opened at once, all bone degloving done at once, all power instrumentation at once, and all closure at once. This results in greatly limiting surgery time and tissue handling.

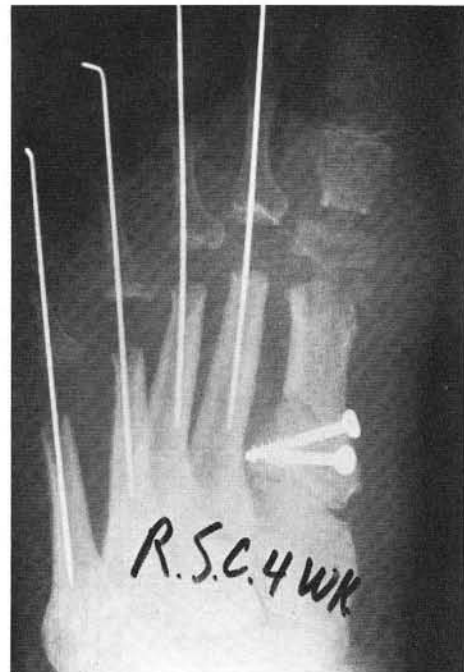

E. Appearance at three days postoperatively shows speed of healing of patients with autonomic neuropathy. Also, planned instrumentation and anatomic dissection contribute to lack of tissue reaction.



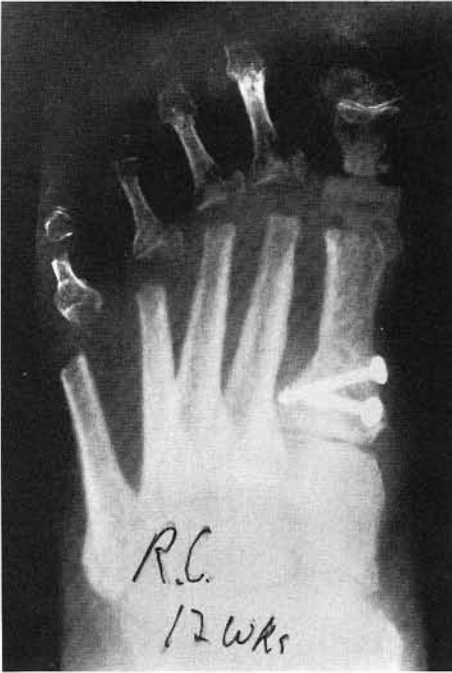Figures 8 C-D illustrate the opening of all incisions at once, degloving of all metatarsal heads at once, opening of all interphalangeal joints at once, using power instruments to make all bone cuts at one time, smoothing of all bony stumps at one time, and then fixating the base wedge osteotomy and placing the implant. By coordinating instruments such reconstruction can be performed in approximately two hours. If such coordination of instruments is not done one could plan on 4-5 hours for the same surgery. At three days post surgery, redressing demonstrates only moderate swelling and no hint of erythema. Part of the benign appearance is related to the presence of autonomic neuropathy and resultant loss of vasomotor tone. This results in very rapid healing. But additional contribution to the appearance comes from coordination of procedures and instrumentation so as to minimize tissue trauma and exposure.

Figures 8 F-G show the post operative appearance at four and twelve weeks. At the twelve week evaluation, the patient returned for surgery on the opposite foot. He was clinically stable and symptom free on the left foot. The toes had fused solidly as had the base wedge osteotomy. The result was excellent weight distribution across the ball of the foot with no hint of pressure point. The patient was advised to wear an accommodative orthotic device for life to minimize stress.



F. Postoperative appearance at 4 weeks.





G. Appearance at 12 weeks when patient returned for surgery on opposite foot.

4. McGlamry ED, Martin DE: Pan metatarsal head resection/causalgia. *Update '89, Reconstructive Surgery of the Foot and Leg*. Tucker, Podiatric Education and Research Institute, 1989

## SUMMARY

Pan metatarsal head resections are, by themselves, a solution to nothing. But with proper incisional planning, proper length planning, appropriate related procedures such as digital arthrodesis, and appropriate realignment of the first ray, the pan resection approach can contribute greatly to re-establishment of a functional forefoot. We have found the procedure to have wide application in treating the rheumatoid foot, the diabetic Charcot foot, the iatrogenically deformed forefoot, and the foot with multiple forefoot nerve entrapments or traction neuropathies. The procedure is technically demanding and if not properly executed will be a disappointment to doctor and patient alike. Proper patient compliance and attention to aftercare detail are essential if a satisfactory result is to be experienced.

## References

1. Hoffman P: An operation for severe grades of contracted or clawed toes. *Am J Orthop Surg* 9:441-449, 1911.
2. Jacobs RL: Hoffman procedure in the ulcerated diabetic foot. *Foot Ankle* 3:3, 1982.
3. Banks AS, McGlamry ED: Diabetic and diabetic Charcot foot reconstruction. *Update '89, Reconstructive Surgery of the Foot and Leg*. Tucker, Podiatric Education and Research Institute, 1989