

LESSER METATARSOPHALANGEAL JOINT IMPLANT ARTHROPLASTY

Thomas F. Smith, D.P.M.

INTRODUCTION

The indications and techniques employed in the total lesser metatarsophalangeal joint (MTP) implant arthroplasty have not received nearly the attention as the first metatarsophalangeal joint counterpart. The former technique cannot be considered merely a smaller version of the great toe implant, although many principles do overlap. There are specific areas where lesser implants are very useful, and other areas that may be inadequate. An appreciation for the surrounding ray anatomy and function is critical. Careful insight into knowledge gained from the past and experiences of use and abuse can aid the practitioner in considering this procedure in cases of forefoot reconstruction.

Strict preoperative criteria will be reviewed as a prelude for lesser implants. The current indications and contraindications will be discussed as well as an update on application and the technique for insertion. Finally, several cases will be used to demonstrate successful as well as unsuccessful applications of these implants to help illustrate the necessary cautions. Lesser metatarsophalangeal implant arthroplasty has a place in foot surgery, and strict adherence to known guidelines will help avoid complications. The techniques discussed employ only the Swanson total lesser metatarsophalangeal implant arthroplasty.

INDICATIONS

The lesser metatarsophalangeal implant functions as an internal splint for the joint. Postoperatively, fibrosis eventually envelopes the implant and acts as an external lattice of support (Fig. 1A,B). A stable space is created which will permit some degree of digital metatarsophalangeal motion within the lesser ray. The implant alone is by no means the stabilizing factor. The fibrous tissues surrounding the implant provide the majority of strength to support this pseudo-joint. Likewise, the implant alone does not provide the mobility for joint motion. The flexible nature of the materials used in its construction promote mobility of the scar while enhancing flexibility of the scar-implant complex. The implant can, therefore, be visualized as a flexible fixation device permitting a stable yet mobile healing process.

The lesser metatarsophalangeal implant is no substitute for a poorly functioning ray or imbalances of a static or dynamic nature within the forefoot. Any compromise of ray function must be addressed by other reconstructive measures. Each metatarsal must assume a specific weight bearing role. Appropriate osteotomies are utilized, not the insertion of lesser implants, to create metatarsal balance. Adequate flexor and extensor power should be present or possible about the implant. The lesser metatarsophalangeal implant

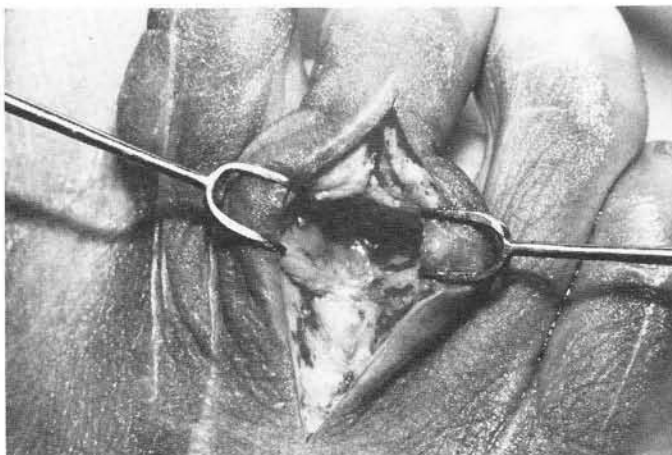


Fig. 1A. Case of reimplantation following implant fracture. Note fibrosis of periarticular soft tissues.

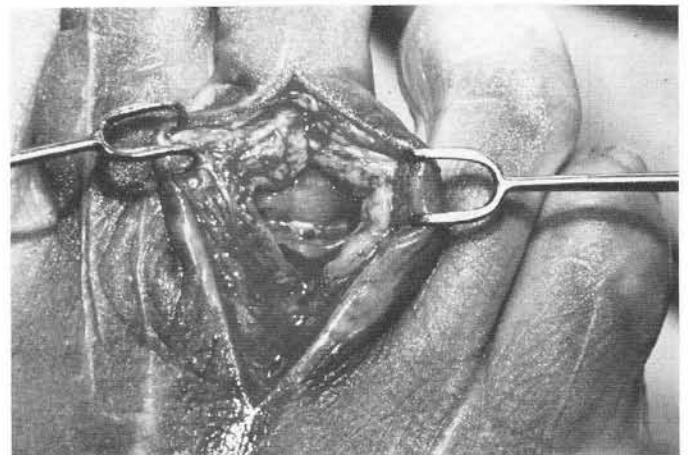

Fig. 1B. Closure of soft tissue envelope over implant.

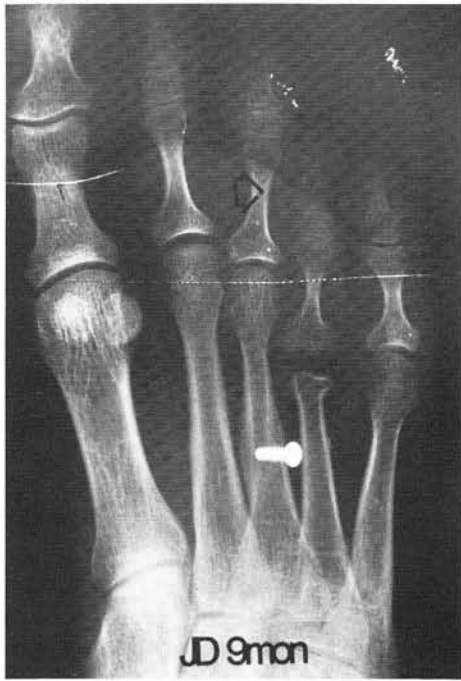

Fig. 2A. Proximal phalangeal disuse atrophy and narrowing.

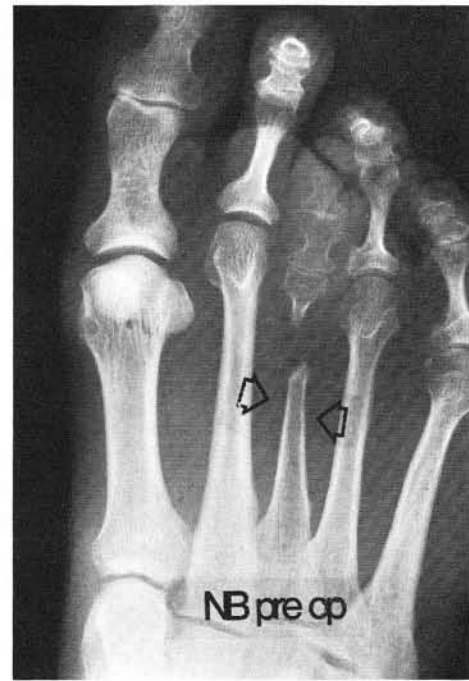

Fig. 2B. Metatarsal disuse atrophy and narrowing.

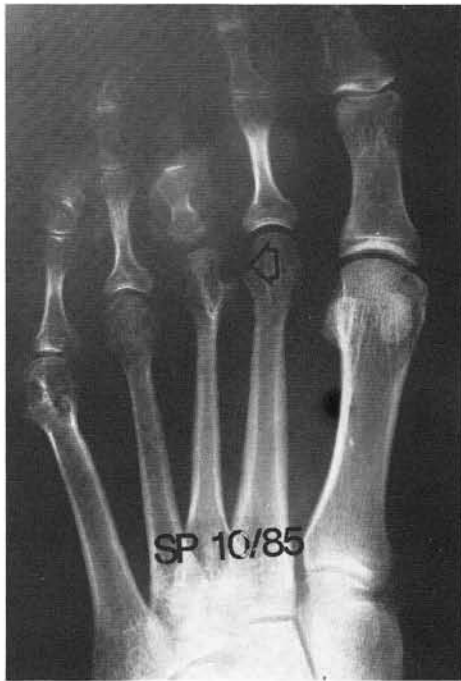

Fig. 3 A, B. Progressive enlargement of cystic and osteoporotic changes in third and fifth metatarsals over two year period in rheumatoid arthritic.

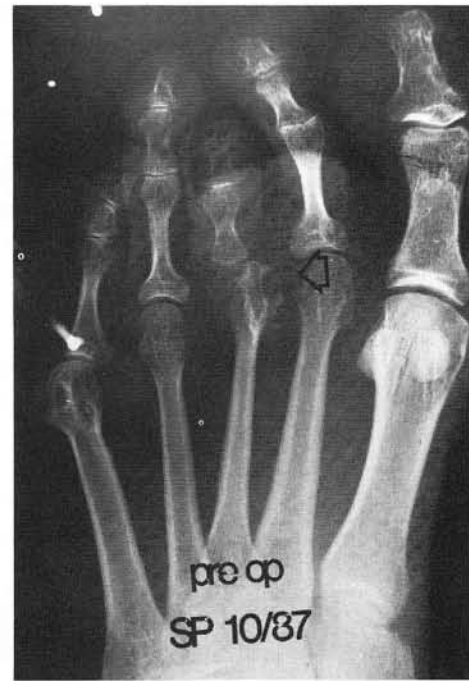

Fig. 3B. Preoperative radiograph.

does not provide any intrinsic power on its own for muscle balance. Adequate bone stock must be present and assured for some time postoperatively to stabilize the implant. By design, the implant stems must be of a given minimal size to provide strength to the implant. Therefore, the bone must be of an adequate width to provide a proper receptacle for the implant stems. (Fig. 2) Weakening of the bone through insertion techniques, vascular compromise of surgery, or

pathological diseases of the bone itself, may all compromise the final result.

Painful joint motion can be relieved by implantation. Angular deformities associated with chronic subluxation and joint adaptation can be alleviated by implantation. Effective spacing or gap filling can be accomplished with implantation, so long as the device is not intended to function as a load bearing part.

CONTRAINDICATIONS

There are certain systemic disease states which for specific reasons are essentially contraindications to implantation. Rheumatoid arthritis is a relative contraindication due to the associated periarticular osteoporosis of the metatarsophalangeal joint area. Even in the presence of relatively good bone stock, the dynamic nature of the disease may later lead to localized osteoporosis or fibular deviation. Therefore, implant failure may eventually occur.(Fig. 3) The neuropathy of diabetes mellitus is also a relative contraindication to implantation. An absence of protective proprioception can affect periarticular tissues through continued microtrauma. The possibility of metatarsophalangeal Charcot joint disease and destructive changes to the periarticular bone would lead to implant failure. Osteoporotic states of a severe nature due to any etiology are likewise a contraindication as the stress at the bone-implant interface may cause loosening, dislocation, or fracture of the osseous tissues.

The contraindications and cautions with any implant technique apply to lesser metatarsophalangeal implants as well. Concerns that would be raised with a history of gout, osteomyelitis, or pyarthrosis and as applied to lesser metatarsophalangeal implantation and will not be fully reviewed here. The age and expected activity level of the patient are other considerations. Although it has not been proven, it is felt that the lesser metatarsophalangeal implant is more protected and less liable to damage from wear. Additionally, the necessary requirement of the lesser metatarsal segments and the degree of motion which is demanded is somewhat less than that of the first ray (Fig. 4A-C).

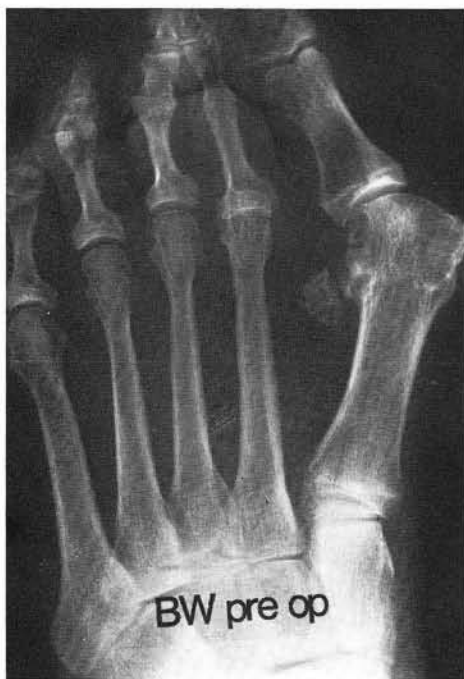

Fig. 4A. Preoperative radiograph.

Lesser metatarsophalangeal implantation should be deferred in the absence of muscle function or in the presence of muscle imbalance about the lesser ray. The implant itself provides no intrinsic joint power. Attempts to "load" the implant in an effort to create flexor power are generally unsuccessful. The constant chronic pressure created at the bone-implant interface results in osseous resorption, implant extrusion, and failure (Fig. 5A,B). A prerequisite to implantation of the lesser metatarsophalangeal joint is muscle balance and power, whether they are evident preoperatively or are surgically attained. In the absence of muscle power, a flail digit is produced where the potential motion created by the implant technique may be more detrimental than

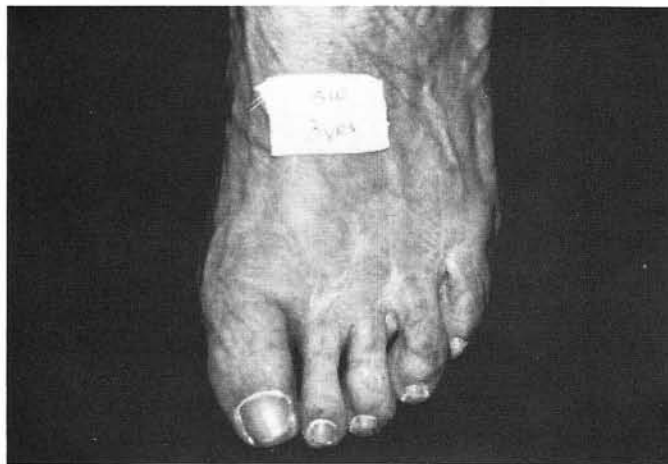

Fig. 4B. 3 year clinical.

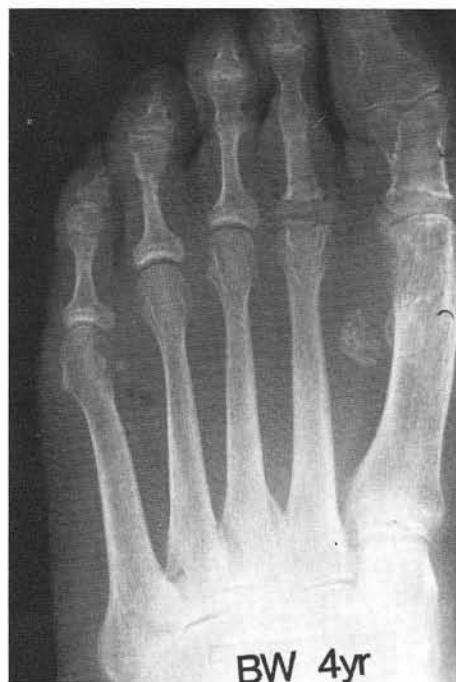

Fig. 4C. 4 year radiographic presentation lesser metatarsophalangeal implant of 2nd metatarsophalangeal joint.

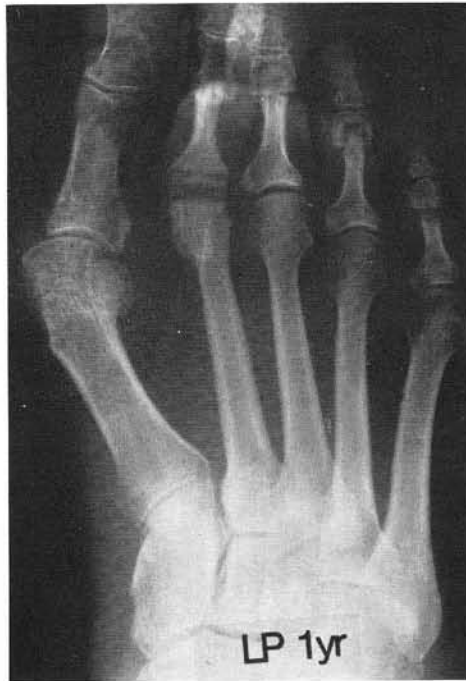

Fig. 5 A, B. Progressive extrusion of implant stem through medial metatarsal shaft over 3 year period.

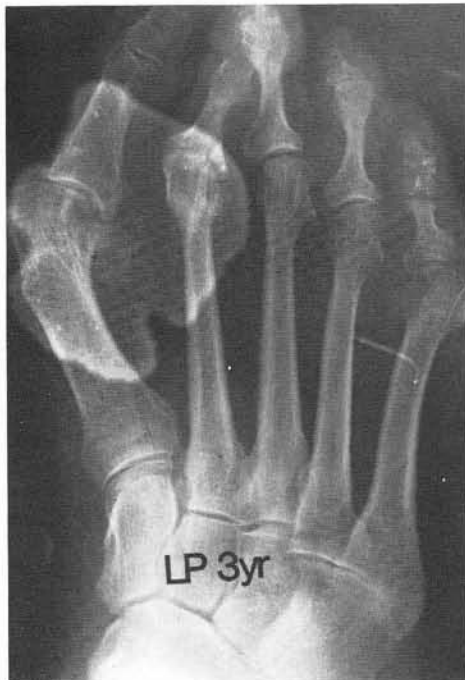

Fig. 5B.

helpful. Positions of deformity are encouraged, not stabilized. The fibrous scar of an arthroplasty may be preferable to implants where there is questionable stability at the joint, provided K-wire fixation is maintained across the joint space.

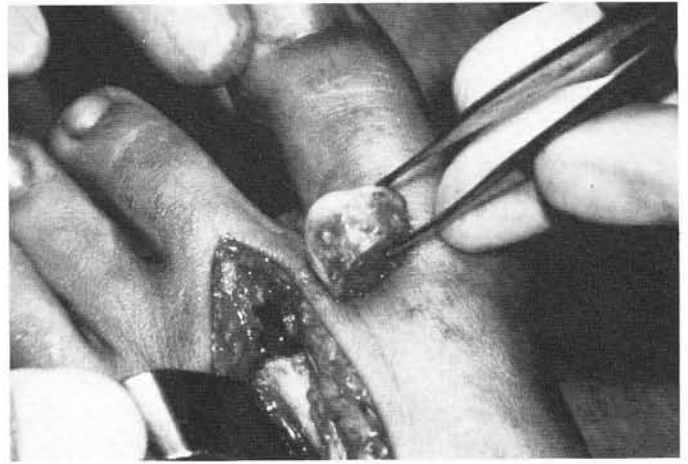

Fig. 6 A, B. Osseous resection of metatarsophalangeal primarily centered on metatarsal.

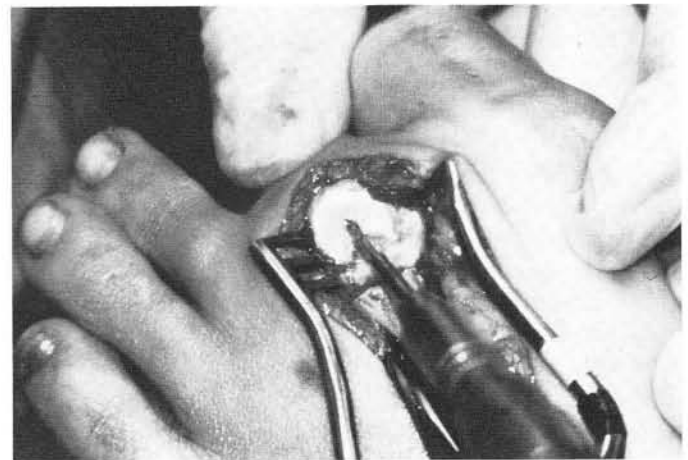


Fig. 6B.

SURGICAL TECHNIQUE PRINCIPLES

There is no known implant capable of assuming the weight bearing function of a metatarsal. The distal and plantar parabola of a metatarsal must be established by other means such as a metatarsal osteotomy. Implantation of the lesser ray must not interfere with the condyles of the metatarsal head. Any disruption of the condylar alignment will disrupt appropriate metatarsal loading and the subsequent ray function. The lesser metatarsophalangeal implant is viewed primarily as a phalangeal "base" replacement as opposed to a metatarsal "head" replacement in terms of osseous resection (Fig. 6A-D). Some intra-articular bone must be removed to permit implantation without excessive joint tension. That bone should be resected primarily from the phalangeal side of the metatarsophalangeal joint. This maneuver protects the weight bearing parabola of the metatarsals. However, it severely compromises the flexor stability of the proximal phalanx. The flexor stability of the proximal phalanx is readily recreated by proximal interphalangeal joint arthrodesis.

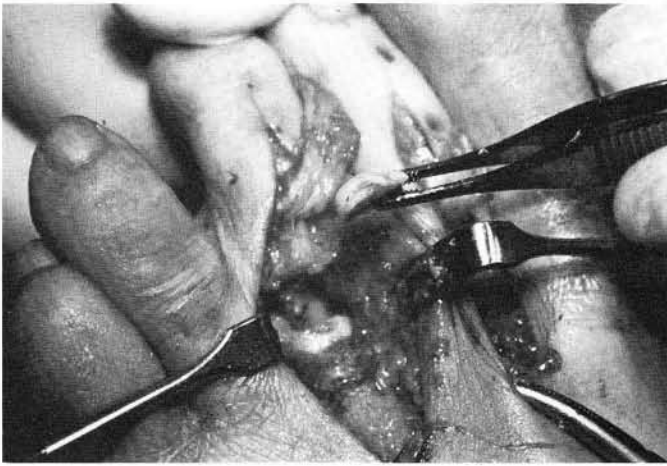


Fig. 6 C, D. Osseous resection primarily centered on proximal phalanx.

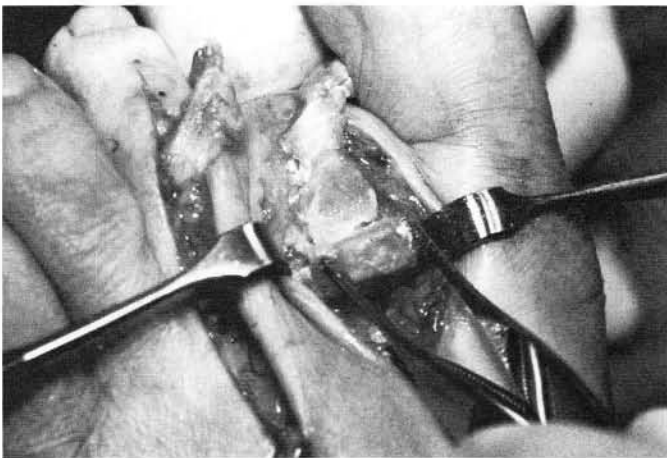


Fig. 6D.

The metatarsophalangeal joint must be adequately released if it is contracted. This is accomplished by a sequential metatarsophalangeal joint release similar to that of any digital deformity. Lengthening of the extensor is performed initially by a Z-plasty maneuver. Persistent extensor contracture is addressed next by extensor hood release. A dilemma may now arise when there exists persistent extensor contracture at the capsular level. An extensor capsular release must be effected and yet an adequate soft tissue coverage for the implant needs to be maintained.

The extensor capsulotomy is generally executed as a transverse linear incision at the joint extending well inferiorly, medially, and laterally below the axis of the metatarsophalangeal joint. All contracture superior to the axis of motion of the joint must be released. Relocation of the metatarsophalangeal joint in plantar flexion causes the capsular tissues to gap dorsally. The capsule is subsequently permitted to heal by fibrosis. This is not preferred in implantation surgery of the lesser metatarsophalangeal joint. An adequate deep soft tissue cover must be created if at all possible.

Three capsular maneuvers are employed that help meet

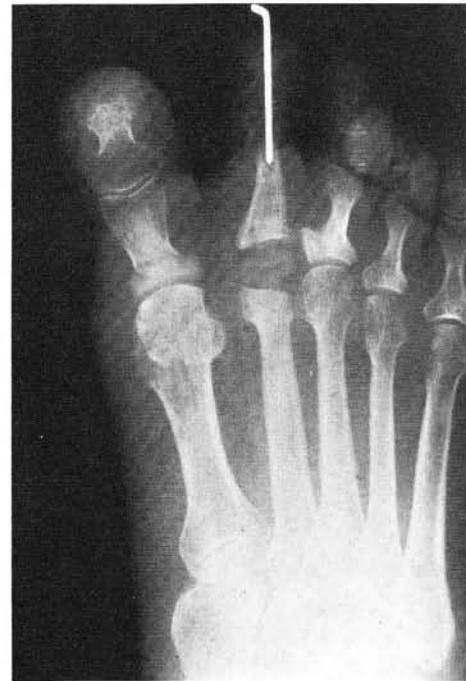

Fig. 7A. PIPJ arthrodesis fixation techniques with Longitudinal K-wire.

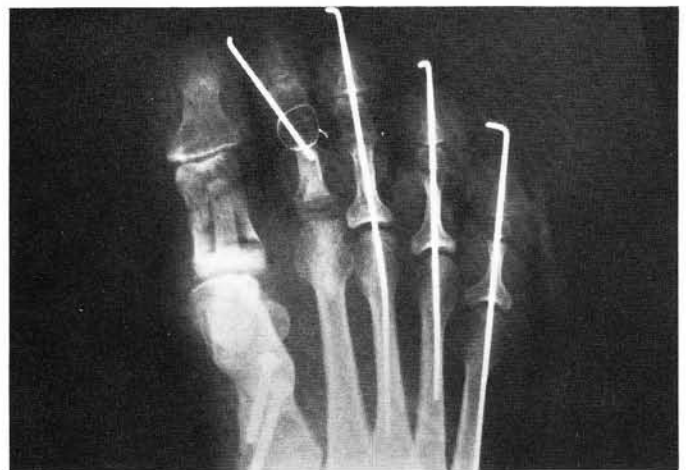

Fig. 7B. With oblique K-Wire.

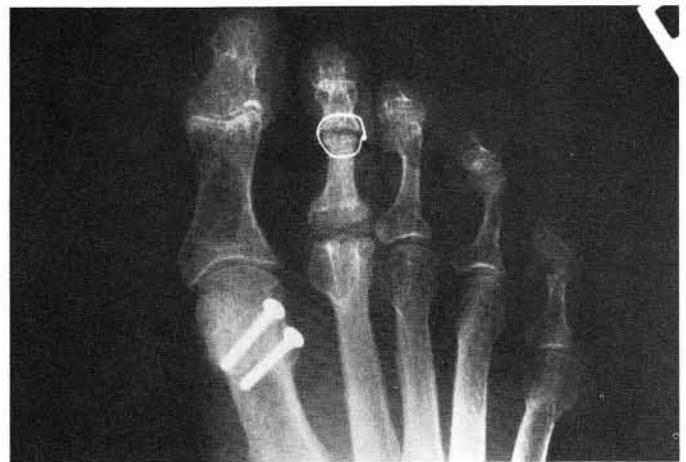

Fig. 7C. With horizontal Wire Loop.

the goals of extensor capsular release and yet still preserve a deep tissue envelope for the implant. The first maneuver is basically a linear proximal-distal capsular incision with no medial or lateral capsular release. Dorsal contracture of the extensor structures is accomplished strictly through the removal of intra-articular osseous joint volume. More bone must be removed than the width of the implant spacer-hinge. Trial seating of the implant sizer assures adequate extensor capsular release indirectly through osseous joint resection. This technique is utilized where minimal extensor contracture is present. It is also helpful in cases where no extensor contracture exists, but implantation is indicated due to arthritic degenerations or joint malalignment type adaptation. No bridges are burned with respect to the deep soft tissues. A transverse medial to lateral extensor capsulotomy may be performed subsequently if needed.

The second capsular approach takes advantage of the first technique described. A longitudinal approach to the lesser metatarsophalangeal joint is employed. If further extensor release is needed, a transverse medial-lateral extension of

the above incision is created. This transverse component is not carried out at the joint line, but well proximal to the metatarsal head and neck area. An envelope is created medially and laterally at the joint-implant level with the extensor gapping occurring well onto the metatarsal. Significant dissection is needed to permit the medial and lateral capsuloperiosteal flaps to slide and permit extensor release.

The third maneuver is to create a dorsal tongue of capsuloperiosteal tissue which is distally based and attached to the proximal phalanx. The proximal tongue originates well onto the metatarsal. This strap of tissue is raised and then following implantation is replaced and secured in a relaxed position. The tissue gap is again directed more proximally on the metatarsal. With this approach, care must be taken to ensure adequate medial and lateral capsulotomy beyond the axis of motion of the lesser metatarsophalangeal joint. Adjunctive incisions may also be necessary.

The proximal interphalangeal joint (PIPJ) arthrodesis is a vital adjunct to lesser metatarsophalangeal implant arthro-

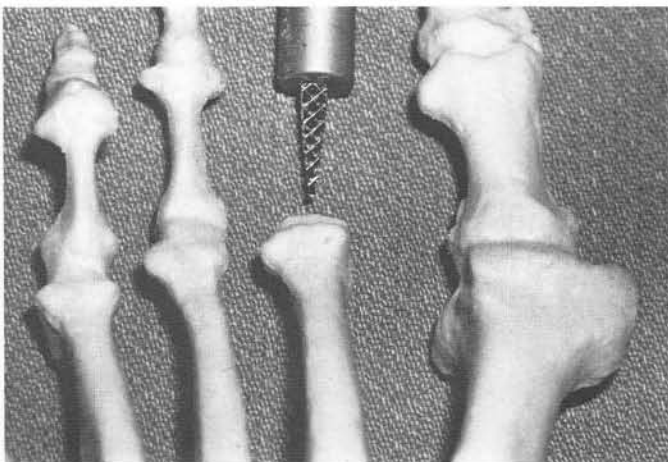


Fig. 8A. Appropriate reamer metatarsal alignment on transverse plane.

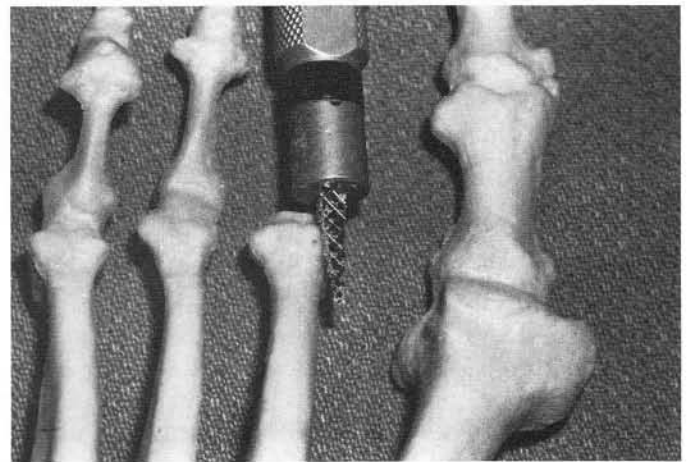


Fig. 8B. Inappropriate alignment as may occur if a degree of metatarsal adductus is present.

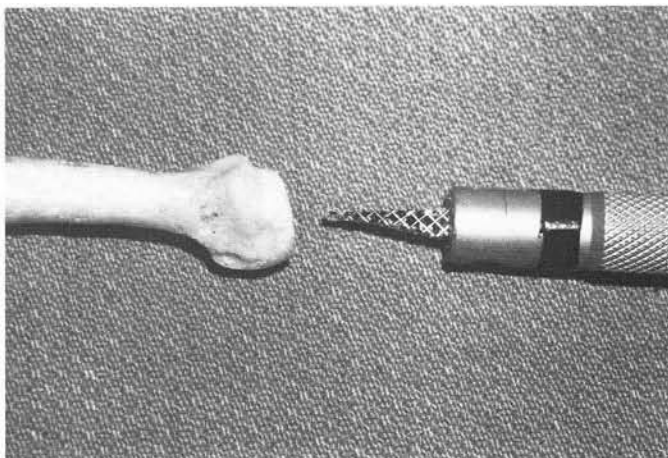


Fig. 8C. Appropriate alignment on sagittal plane.

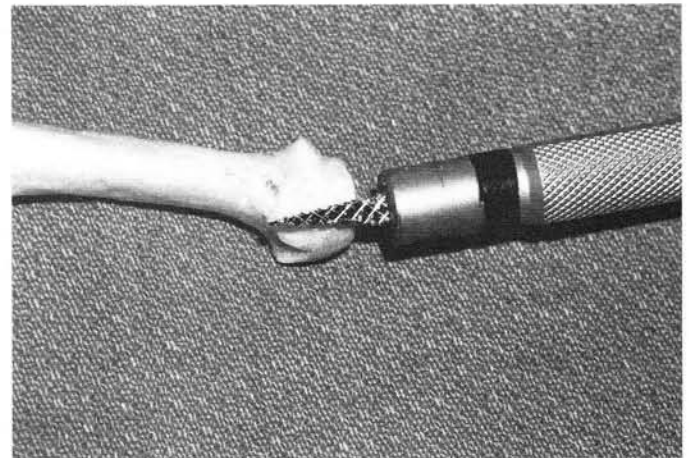


Fig. 8D. Inappropriate alignment not considering plantar metatarsal declination angle.

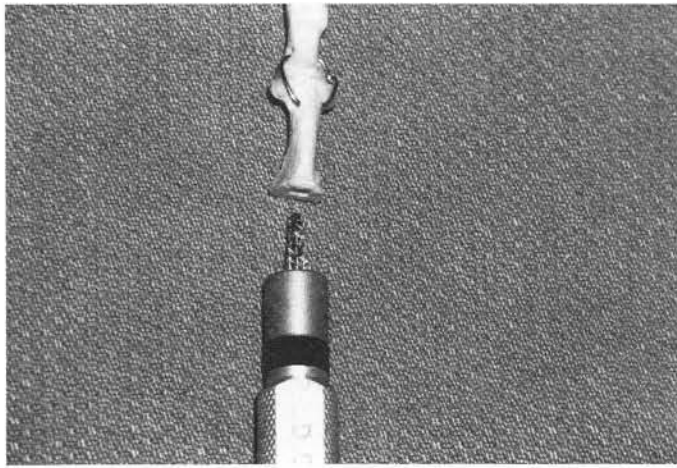


Fig. 9A. Appropriate transverse plane.

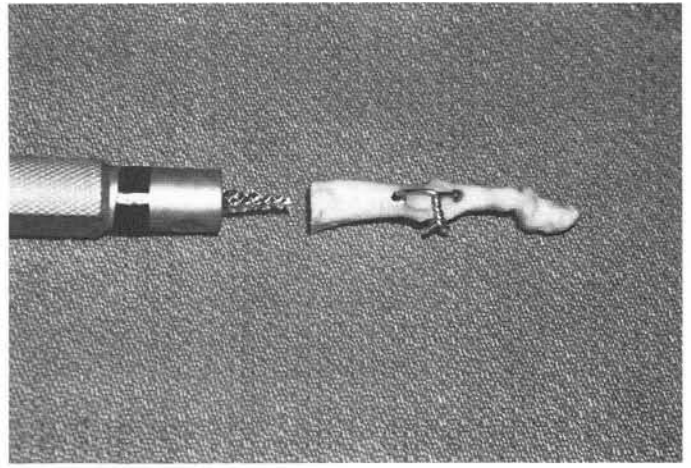


Fig. 9B. Sagittal plane reamer-phalangeal alignment.

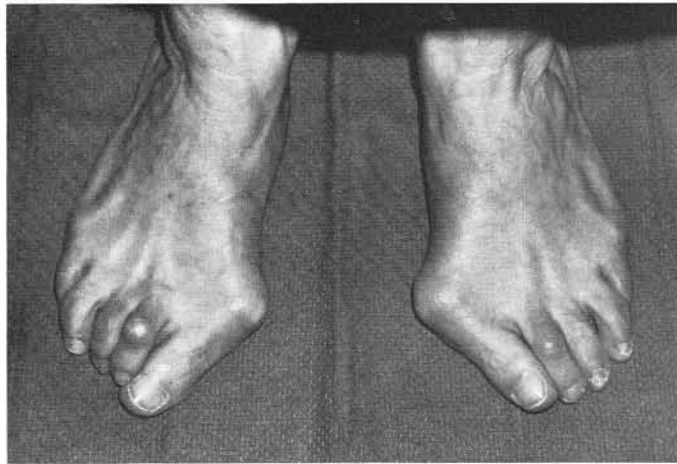


Fig. 10A. Preoperative clinical.

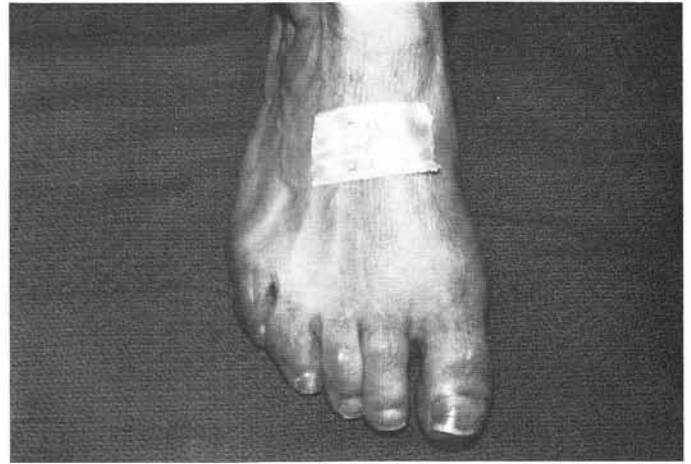

Fig. 10B. 2 year postoperative clinical lesser metatarsophalangeal implant 2nd.

plasty. The long flexor is converted to a plantar flexory stabilizer of the metatarsophalangeal joint. This plantar flexory stability is essential to compensate for the loss of intrinsic function following the proximal phalangeal base resection. The insertion of the plantar fascia is also lost and must be taken into account.

The primary difficulty in PIPJ arthrodesis and lesser metatarsophalangeal implantation is fixation (Fig. 7A-C). Orienting the K-wires longitudinally is difficult due to the presence of the stem of the implant within the small proximal phalangeal stump. Oblique pins may be an alternative. Most effective has been a horizontal wire loop of 24 or 28 gauge monofilament wire. Transverse drills are placed in the distal aspect of the proximal phalangeal stump and in the proximal aspect of the middle phalangeal stump. A significant degree of internal stability is obtained by weaving the wire through the drill holes in a horizontal mattress fashion. Capsuloperiosteal sutures on the medial and lateral aspect of the PIPJ arthrodesis site can serve as a further reinforcement of the internal fixation.

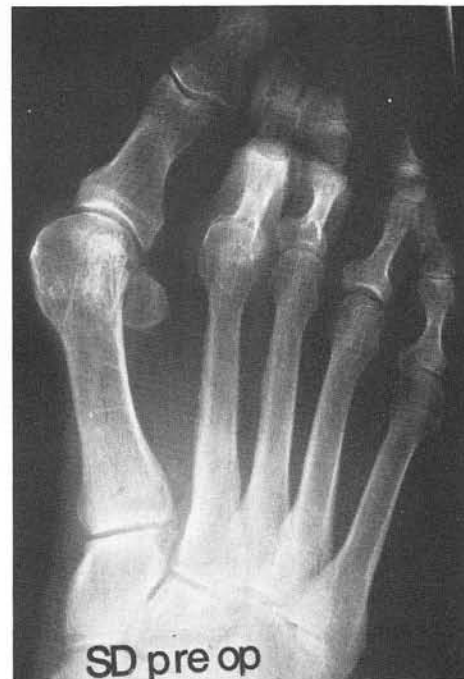

Fig. 10C. Corresponding preoperative.

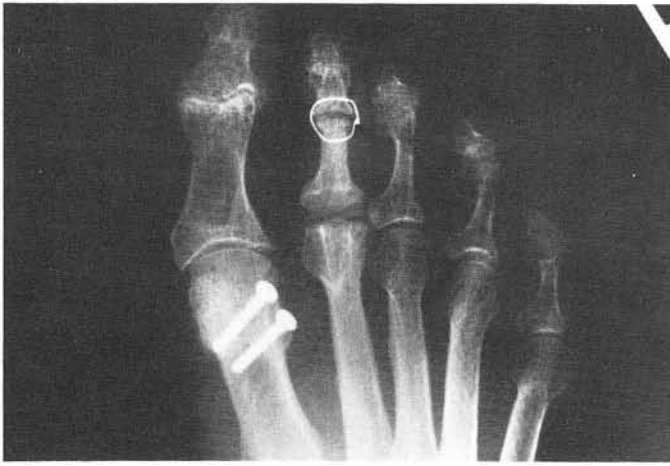

Fig. 10D. Postoperative radiographs.

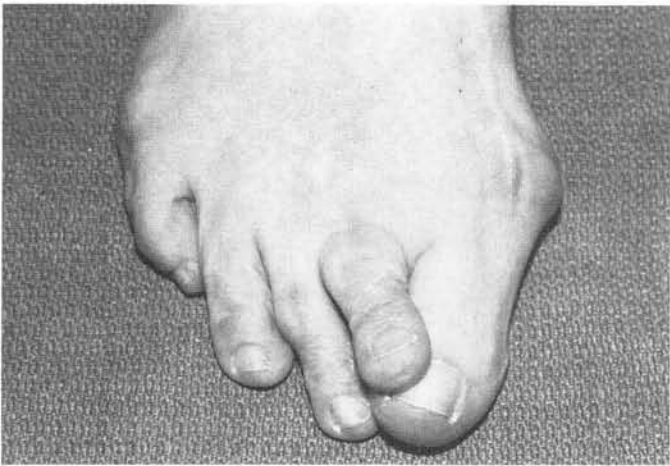


Fig. 11A. Preoperative clinical.

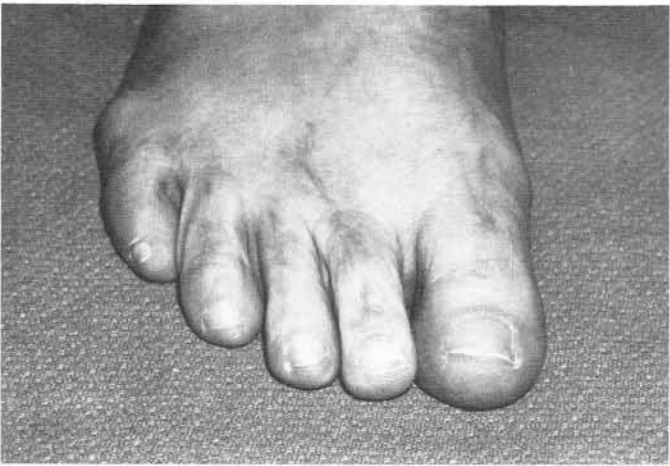

Fig. 11B. 18 month postoperative lesser metatarsophalangeal implant second.

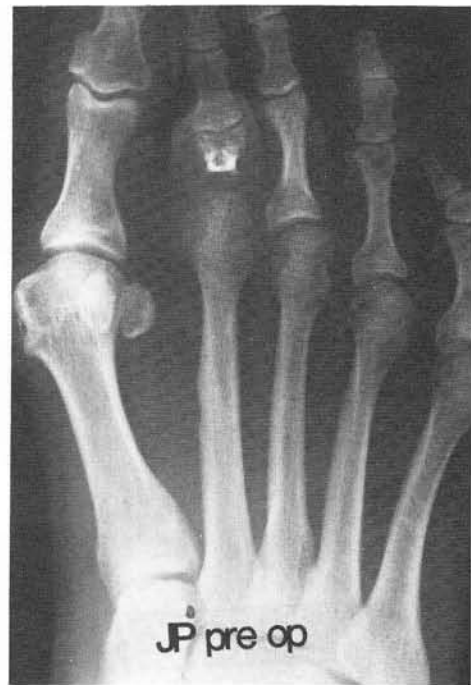

Fig. 11C. Corresponding preoperative.

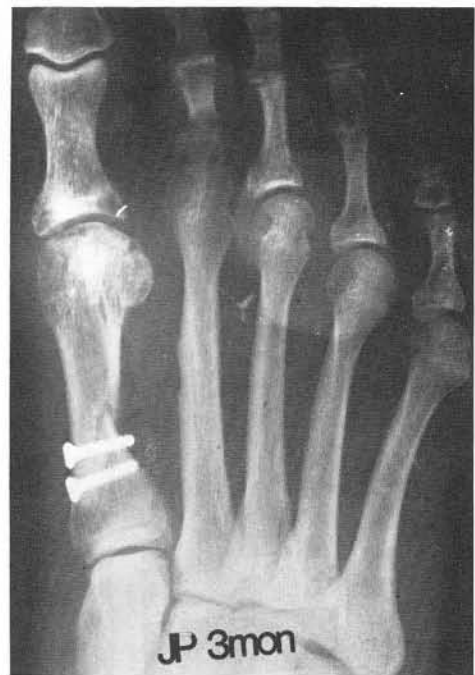

Fig. 11D. Postoperative radiographs.

The figures and legends will graphically detail the reaming process for implantation (Fig. 8A-D, 9A, B). Careful attention to the angular alignments of the osseous components of the lesser ray is critical. Trial seating must ensure adequate soft tissue release. The absence of any loading forces on the

implant is critical. If digital abductus at the metatarsophalangeal level is of a severe nature and is not alleviated through osseous resection then loading or angular forces will eventually destroy the implant, the bone, or both.

CONCLUSION

The lesser metatarsophalangeal implant arthroplasty can be an important consideration in the patient undergoing forefoot reconstruction. Strict adherence to the known principles of lesser ray function and the knowledge of procedural indications is mandatory. Lesser metatarsophalangeal implant arthroplasty can be a rewarding adjunctive procedure to both the surgeon and patient (Fig. 10A-D, 11A-D).

Suggested Reading

1. Frisch EE: Biomaterials in foot surgery, *Clin Podiatry* 1:11-27, 1984.
2. Seeburger R: Surgical implants of alloyed metal in joints of the feet. *J Am Podiatry Assoc* 54:391-396, 1964.
3. Albin RL, Weil LA: Flexible implant arthroplasty of the great toe: An evaluation. *J Am Podiatry Assoc* 64:967-975, 1974.
4. Kalish SR, McGlamry ED: The modified Keller hallux valgus repair utilizing Silastic implants. *J Am Podiatry Assoc* 64:761-773, 1974.
5. LaPorta GA, Pilla P, Richter KP: Keller implant procedure: a report of 536 procedures utilizing a Silastic intramedullary stemmed implant. *J Am Podiatry Assoc* 66:126-146, 1976.
6. Kaplan BR, Cohen SJ: The use of the Calnan-Nicolle prosthesis for metatarsophalangeal joint replacement. A preliminary study. *J Am Podiatry Assoc* 66:165-172, 1976.
7. McGlamry ED, Ruch JA: Status of implant arthroplasty of the lesser metatarsophalangeal joints. *J Am Podiatry Assoc* 66:155-164, 1976.
8. Downey MA: A ball and socket metal prosthetic joint replacement, as applied to the foot. *J Am Podiatry Assoc* 55:343-346, 1965.
9. Krause LE: A technical failure with Durallium prosthesis. *Am Coll Foot Sur J* 5:139-141, 1966.
10. Myers MM: A four-year observation of Freiberg's infraction. *J Foot Surg* 6:185-188, 1967.
11. Scioli ER: Metal prosthetic implantation for deformed lesser M. P. Joint. *J Foot Surg* 6:105-106, 1967.
12. Feder JA, Feder HJ: Metatarsal head replacement with ulnar implant. *J Foot Surg* 13:145-146, 1974.
13. Karp NE: Silastic implant: case history. *J Foot Surg* 13:29-30, 1974.
14. Freed JB: Alternative approaches to replacement of lesser metatarsal heads. *J Foot Surg* 18:26-30, 1979.
15. Aeby CH, Leon PD: Utilization of Calnan-Nicolle implant. *J Am Podiatry Assoc* 68:167-171, 1978.
16. Hill J, Jimenez AL, Langford JH: Osteochondritis dissecans treated by joint replacement. *J Am Podiatry Assoc* 69:556-561, 1979.
17. Tintocalis CA: Nicolle finger joint prosthesis: a preliminary study of total joint replacement for lesser metatarsophalangeal joints. *J Foot Surg* 21:57-60, 1982.
18. Lawrence BR, Papier MJ: Implant arthroplasty of the lesser metatarsophalangeal joint — a modified technique. *J Foot Surg* 19:16-19, 1980.
19. Sgarlato T: A new implant for the metatarsophalangeal joint. *Clinics Podiatry* 1:69-77, 1984.
20. Fenton CF, Gilman RD, Yu GV: Criteria for joint replacement surgery in the foot. *J Am Podiatry Assoc* 72:535-539, 1982.
21. Vanore JV, O'Keefe RG, Pikscher I: Complications of silicone implants in foot surgery. *Clinics Podiatry* 1:175-198, 1984.
22. Swanson AB: Evolution and testing of flexible implants. In Swanson AB (ed): *Flexible Implant Resection Arthroplasty in the Hand and Extremities*. St. Louis, CV Mosby, 1973, p. 32.