

# ACHILLES PERITENDINITIS

Alan S. Banks, D.P.M.

Achilles tendon pathology may be conveniently divided into either acute or chronic manifestations, although the two are probably more related than is currently appreciated. Chronic inflammation about the achilles is a source of pain and disability for an increasing number of patients. In many instances symptoms may prove recalcitrant to a multitude of conservative modalities and eventually require surgical intervention. Today, there are a number of papers which discuss the chronic forms of achilles pathology. However, very little has been published in podiatric literature. The purpose of this presentation is to discuss this timely subject and to enhance the awareness of those within the profession regarding the condition.

## ANATOMY

The achilles tendon does not possess a synovial sheath, but is surrounded by a distinct connective tissue envelope known as the paratenon or peritendonous material. The peritendonous structures are highly vascular, and as such, are susceptible to inflammatory processes. Tendon derives its blood supply from four different sources: From muscle proximally, from osseous tissue distally, from peritendonous structures, and mesotendon. Anatomic studies show that very little blood is supplied to the achilles via muscle or osseous anastomoses. Therefore, the majority of the vascular elements are provided by the peritendonous structures. Also of interest is a relatively dysvascular area of the tendon approximately 2-6 cm proximal to its insertion. This was described by Lagergren and Lindholm in their study on the vascular supply of the achilles tendon.<sup>1</sup>

Cummins, et. al. in their classic paper on the anatomy of the tendo achillis, noted that the fibers of the gastrocnemius aponeurosis and the soleus tendon rotated as they converged distally. The gastrocnemius fibers inserted posterolaterally, laterally, and somewhat anteriorly. All the specimens were noted to demonstrate this finding, although the degree of torsion was variable.<sup>2</sup>(Fig. 1 A,B) Sarrafian quotes Testut as describ-

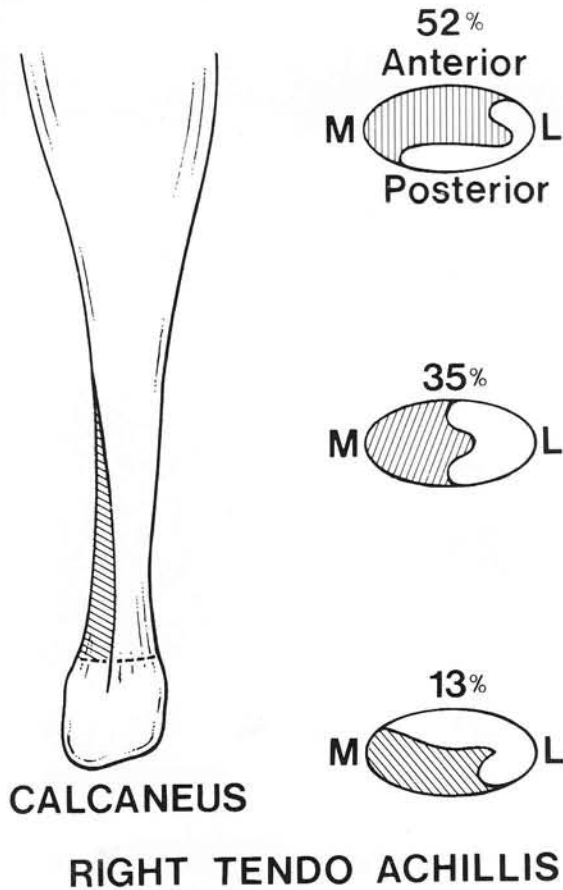


Fig. 1A. Cummins, et.al., described 3 major torsional patterns of the gastrocnemius and soleus fibers. Each are shown above with their relative predominance in the specimens examined.

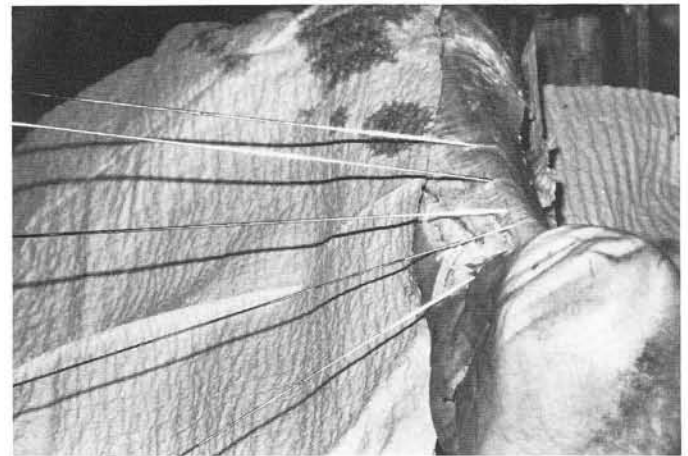


Fig. 1B. Cadaver specimen showing torsion of the Achilles tendon.

ing the torsion of the fibers as being greatest 2 to 5 cm from the tendon insertion.<sup>3</sup> This correlates precisely with the area of minimal vascularity for the achilles. More than likely this occurrence is not consequential.

## NOMENCLATURE

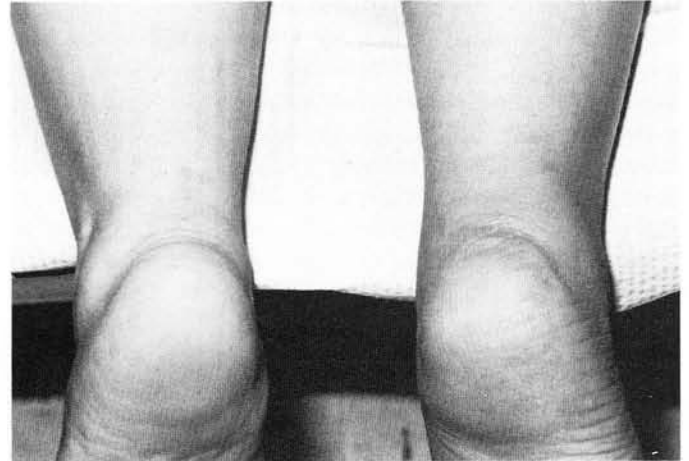
Puddu et.al. felt that the generic term "tendonitis" was inappropriate for this condition.<sup>4</sup> Based upon anatomic and pathologic findings they suggested three different forms of chronic achilles pathology: (a) Inflammation which involves only the surrounding tissues without affecting the tendon itself was termed peritendinitis. (b) Peritendinitis with tendonosis was preferred whenever a concomitant degenerative process within the achilles itself was observed. (c) Tendonosis denoted a pure degenerative process within the tendon which was asymptomatic since the surrounding tissues were not inflamed.

## SOURCES OF INFLAMMATION

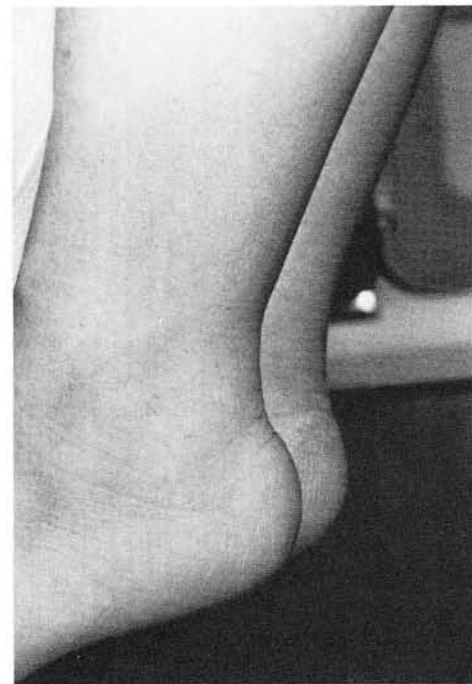As indicated above, it is the peritendonous structures which are capable of eliciting an inflammatory response. Thus direct trauma to these tissues may serve as the stimulus for chronic pathology. In our experience this has most commonly been seen following blunt injury. Hemorrhage involving the peritendonous structures may result in the formation of an organized hematoma and resultant fibrosis, each having the potential to impair normal, smooth function. Chronic inflammation may result if early resolution of this problem is not attained.(Fig. 2A,B) Fortunately, most cases will resolve with vigorous physical therapy measures, but the progress may be slow.

Biomechanical deformities within the foot and leg have also been implicated as contributing factors in the development of achilles peritendinitis. Clement, et.al., felt that patients who pronated excessively subjected the tendon to rapid opposing components of rotation. As the heel is undergoing an excessive range of motion, the knee is also extending. Therefore, the leg and foot are subjected to simultaneous contradictory medial and lateral rotation. This was purported to blanch the vessels within the peritendonous areas and lead to inflammation.<sup>5</sup> Those patients who undergo excessive pronation from a supinated position, or those with a high midtarsal or subtalar joint axis are primarily susceptible. A patient with the latter condition will have a higher proportion of transverse plane motion in the foot for the same degree of overall joint mobility. Therefore, torsional forces are accentuated even further upon the tendinous structures.

Poor flexibility of the achilles (equinus) was also noted to be responsible for a number of cases.<sup>5</sup> Patients with equinus are constantly applying stress to the triceps, especially when the shortage of ankle dorsiflexion is only partially compensated in other anatomic areas. Pathologic pronation is evident in those who are able to fully compensate at times creating the scenario described above. Patients with gastrocnemius equinus who possess normal soleal flexibility would theoretically be more susceptible to inflammatory processes due to the different degrees of tension within the tendon itself.



**Fig. 2A.** This patient sustained an acute blunt traumatic episode to the posterior aspect of the mid-leg. Several months later peritendinitis remains despite conservative measures.



**Fig. 2B.** The swelling surrounding the achilles can be appreciated.

Vascular studies of the achilles tendon have demonstrated an area of relatively poor perfusion 2-6 cm from the insertion of the tendon.<sup>1</sup> As discussed above, this has been considered to be a cause of chronic inflammation and also acute rupture. However, as rotational stress is suggested as a primary factor in developing inflammation, the degree of anatomic torsion present within the tendon may also be a factor to consider. A tendon which already has a high degree of rotation of the gastrocnemius fibers is less likely to withstand the mechanical demands of excess pronation or equinus.

Osseous deformity adjacent to the achilles may also serve to irritate the peritendonous tissues and result in inflammation. Impingement from the posterolateral aspect of the calcaneus (Haglund's deformity) is one such condition.<sup>6</sup> Hypertrophic spurring at the insertion of the tendo achillis may incite inflammation due to mechanical irritation. Those patients with recalcitrant and extensive symptoms associated with insertional spurring may have actually avulsed bone. The persistent irritation due to the loose body is another factor to consider.

Arthritic diseases are also known to manifest at times with peritendinitis. More recently reports have noted an association with the HLA-B27 antigen.<sup>7</sup> Although the achilles does not have a true synovial sheath, arthritic processes should be considered in those patients with recalcitrant symptoms or in those where no other obvious causes can be ascertained.

Two other conditions may be seen in conjunction with peritendinitis with tendonosis. The first is acute tendon rupture. Just as tibialis posterior tendon ruptures are seen following inflammatory processes, the same occurs with the tendo achillis. Several authors have noted evidence of degeneration at the time of surgical repair for acute rupture.<sup>4,8,9</sup> Chronic tendonosis without pain may also be a problem leading to eventual rupture.<sup>4</sup>

Dystrophic calcification within the body of the achilles tendon may also be a direct result of chronic inflammation and/or degeneration.<sup>10,11</sup> This should not be overlooked when a patient presents with radiographic evidence of this finding.

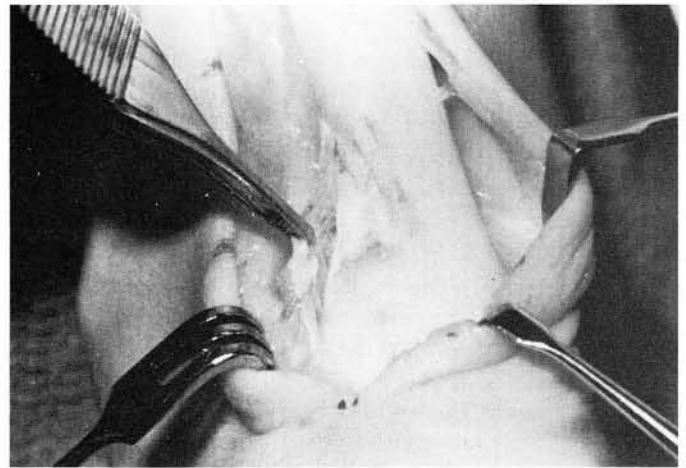
## TREATMENT

Fortunately most patients with symptomatic achilles pathology will respond to aggressive conservative means if implemented early. This consists of various forms of physical therapy (ice massage, ultrasound, stretching/strengthening exercises), casting, NSAIDs, heel raises,

and rest. Orthotic control of inappropriate rearfoot pronation has also proven effective in those with underlying mechanical problems. Steroid injections for any of these three affectations of the achilles are contraindicated.

Patients suffering from prolonged peritendinitis with tendonosis or isolated tendonosis are at risk for rupture of the achilles. Numerous studies have shown that degenerative changes of some form are almost always present at the time of surgical repair. Therefore, most clinicians seem to limit conservative care to approximately a one year duration.

Those cases which are recalcitrant may require surgical intervention. If the primary problem is an osseous deformity, then resection of the spurring or prominence may prove adequate. Patients without osseous involvement may be helped by surgical exploration of the tendon and surrounding tissues. The literature supports this form of intervention, and most agree upon the intraoperative approach. If the paratenonous tissues are fibrotic, inflamed, or adherent, they should be resected. Any degenerative areas of the tendon should similarly be excised.<sup>12,13,14</sup>(Fig. 3) Some authors advocate longitudinal incisions within the tendon to search for occult areas of pathology. This also has the purported benefit of encouraging new vascular ingrowth for the tendon.<sup>4</sup> MRI scans may prove to be of benefit in identifying specific areas of pathology prior to surgery.



**Fig. 3.** Intraoperative photo of a patient treated conservatively for over a year for chronic peritendinitis. Adherence of the paratenon is appreciated distally, as well as degeneration of the tendon representing tendonosis.

Postoperative care generally consists of a below knee cast for approximately four weeks. At two weeks the cast is bivalved and the patient allowed to undergo gentle limited passive range of motion twice daily. At four weeks weight bearing is instituted in a guarded manner, at times with crutch assist and a slight heel raise. Physical therapy may be used to help stretch and strengthen the achilles. Activities progressively advance from walking, to cycling, and finally running.

Generally the results following surgery have been reported as being very successful. One probably is curious as to whether or not the excision of a primary vascular supply such as the peritendon is advantageous. However, to date no later sequela have been published. As mentioned above, it is felt that the vascular ingrowth will later occur from surrounding tissues.

pair of calcifications of the tendo achillis. *Surgery of the Foot and Leg*, 1986, McGlamry ED, (ed.), Podiatry Institute Publishing Co., Tucker, GA, 1986, pp.134-139.

12. Leach RE, James S, Wasilewski S: Achilles tendinitis. *Am J Sports Med*, 9:93-98, 1981.
13. Clancy WG, Neidhart D, Brand RL: Achilles tendonitis in runners: A report of five cases. *Am J Sports Med*, 4:46-57, 1976.
14. Gould N, Korson R: Stenosing tenosynovitis of the pseudosheath of the tendo achilles. *Foot Ankle*, 1:179-187, 1980.

### References

1. Lagergren C, Lindholm A: Vascular distribution on the achilles tendon - an angiographic and microangiographic study. *Acta Chir Scand*, 116:491-495, 1958.
2. Cummins EJ, Anson BJ, Carr BW, Wright RR: The structure of the calcaneal tendon (of achilles) in relation to orthopedic surgery. *Surgery Gynecology Obstetrics*, 83:107, 1946.
3. Sarrafian SK: *Anatomy of the Foot and Ankle*, JB Lippincott Co., Philadelphia, 1983, p. 249.
4. Puddu G, Ippolito E, Postacchini F: A classification of achilles tendon disease. *Am J Sports Med*, 4:145-150, 1976.
5. Clement DB, Taunton JE, Smart GW: Achilles tendinitis and peritendinitis: etiology and treatment. *Am J Sports Med*, 12: 179-184, 1984.
6. Schepsis AA, Leach RE: Surgical management of achilles tendinitis. *Am J Sports Med*, 15:308-315, 1987.
7. Olivieri I, Gemignani G, Gherardi S, Grassi L, Ciompi ML: Isolated HLA-B27 associated achilles tendinitis. *Ann Rheumatic Dis*, 46:626-627, 1987.
8. Fox JM, Blaxina Me, Jobe FW, Kerlan RK, Carter VS, Shields CL, Carlson GJ: Degeneration and rupture of the achilles tendon. *Clin Orthop*, 107:221-224, 1975.
9. Jozsa L, Kvist M, Balint BJ, Reffy A, Jarvined M, Lehto M, Barzo M: The role of recreational sport activity in achilles tendon rupture. *Am J Sports Med*, 17:338-343, 1989.
10. Fiamengo SA, Warren RF, Marshall JL, Vigorita VT, Hersh A: Posterior heel pain associated with a calcaneal step and achilles tendon calcification. *Clin Orthop*, 167:203-211, 1982.
11. Downey MS, Kalish SK: Surgical excision and re-