

THE MAU OSTEOTOMY: SURGICAL TECHNIQUE

Gordon W. Patton, DPM

The Mau osteotomy, first performed in 1915, is used today as an alternative to the closing base wedge osteotomy in correction of the metatarsus primus adductus component of hallux abducto valgus¹. Several modifications have been developed and are described as follows.

A 10 cm dorsolateral incision is made just medial and parallel to the extensor hallucis longus tendon, over the first metatarsophalangeal joint. This incision is deepened with care being taken to maintain hemostasis down to the level of the joint capsule. The wound margins are retracted laterally over the first interspace, carefully identifying all vital structures. The extensor hallucis longus tendon is retracted medially, with care to avoid violation of its tendon sheath. The first interspace is entered by sharp and blunt dissection until the appropriate soft tissue structures have been released.

Attention is then directed medially to the first metatarsophalangeal joint capsule where a linear or inverted *L* capsular incision is performed. Capsular and soft tissue structures are freed with great care to avoid disturbing the dorsal synovial fold of the first metatarsophalangeal joint². The medial eminence is removed with an osteotome and mallet or power instrumentation.

The initial skin incision is extended 3 cm proximally to the first metatarsocuneiform joint. A linear longitudinal periosteal incision is made medial and parallel to the long extensor tendon. Periosteal tissues are reflected as an intact structure, gaining exposure to the osteotomy site.

A through and through osteotomy is performed from medial to lateral using a power sagittal saw. The osteotomy should be made parallel to the weightbearing surface from dorsal distal to plantar proximal through the shaft of the

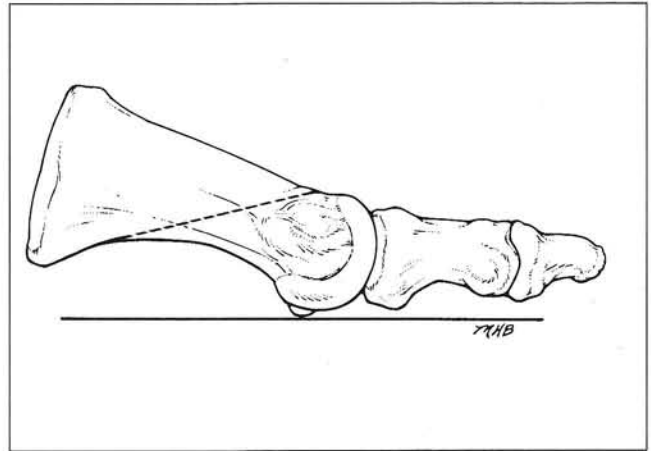


Fig. 1. Mau osteotomy is made approximately parallel to weight-bearing plane. One must exercise care to avoid entering cuneometatarsal joint with cut.

first metatarsal (Fig. 1). The obliquity of the osteotomy is limited by the flare of the proximal plantar base of the first metatarsal shaft. Care should be exercised to avoid entering the first metatarsocuneiform articulation proximally, and the capital articulation distally.

With the osteotomy completed, an axis guide is established at the proximal portion of the osteotomy using a small Kirschner wire (K-wire) (Figs. 2 A, B). The K-wire is angled perpendicular to the osteotomy allowing the distal fragment to pivot laterally, closing down the intermetatarsal angle (Fig. 3). Once the distal segment has been pivoted, the osteotomy is temporarily fixated with a bone clamp centered on the osteotomy.

Intraoperative x-rays are obtained to assure proper alignment. If overcorrection is noted on the intraoperative films, then it is a simple matter of repositioning the bone clamp to the correct angle without any further bone resection.

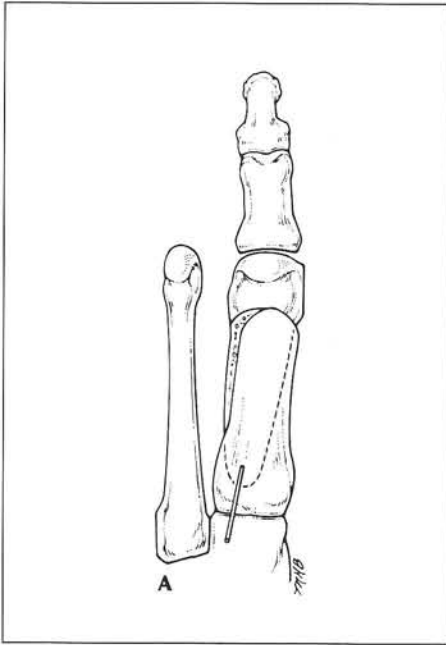


Fig. 2A. Dorsal view of Kirschner wire axis around which pivoting occurs.

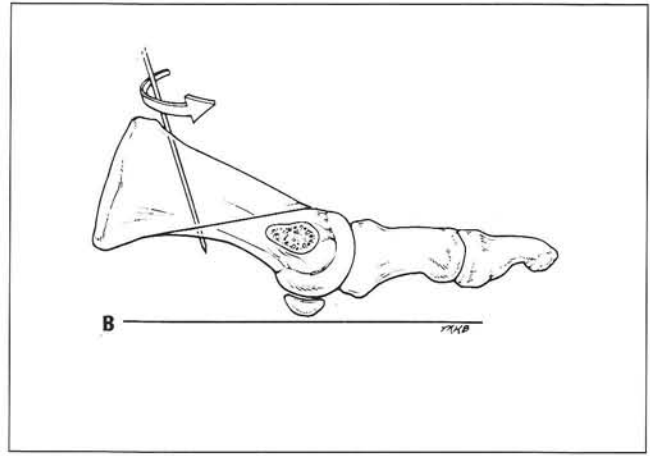


Fig. 2B. Medial view of Kirschner wire axis.

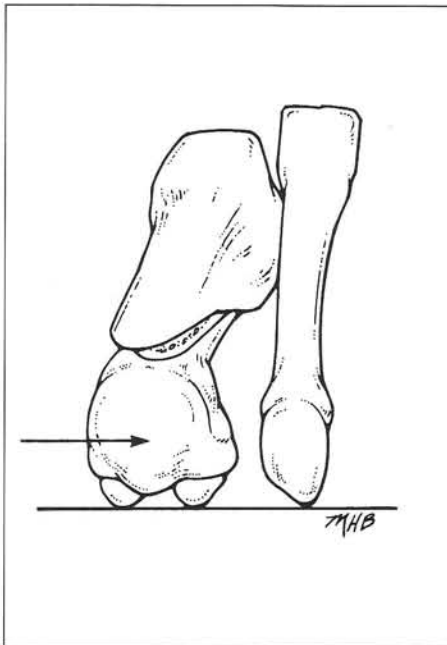


Fig. 3. Distal view after pivoting distal fragment to desired position of correction.

Fixation of the osteotomy is most frequently accomplished using two 2.0-mm cortical screws. The axis wire is then removed, and the medial cortical overlap reduced with power equipment. The wound is irrigated, and the medial capsule of the first metatarsophalangeal joint is repaired using simple interrupted sutures of 2-0 Dexon. The periosteum is closed with 3-0 Dexon and the subcutaneous tissues are reapproximated and closed with 4-0 Dexon sutures. The skin is closed with suture material of the surgeon's choice. The wound is bandaged so that the hallux is maintained in the corrected physiologic position.

REFERENCES

1. Patton GW, Tursi FJ, Zelichowski JE: The dorsal synovial fold of the first metatarsophalangeal joint. *J Foot Surg* 26:210, 1987.
2. Mau C, Lauber HT: Die operative behandlung des hallux valgus. *Dtsch Z Chir* 197:363, 1926.