

Retrocalcaneal Exostectomy With Reattachment Of Tendo Achillis

Michael S. Downey, D.P.M.

INTRODUCTION

The management of posterior heel pain can be a perplexing diagnostic and therapeutic problem. The differential diagnosis is quite extensive, and the skilled clinician can experience difficulty establishing an accurate diagnosis. Of the challenging conditions affecting the back of the heel, the retrocalcaneal exostosis may be the most onerous to treat. Unlike the Haglund's deformity, which is generally a posterior-superior or posterior-superior-lateral prominence, the "true" retrocalcaneal exostosis involves an intratendinous component. Thus, the surgical approach must include incision through at least a portion of the tendinous substance of the Achilles tendon. It is the author's intent to provide the surgeon treating the lower extremity with a technically simplified, reproducible method for treating this most arduous condition.

PATHOPHYSIOLOGY/ETIOLOGY

The Achilles tendon is subject to significant stresses during everyday walking and activity. During periods of intense physical activity, such as fast running, forces up to 900 kg may be exerted on the tendon. Cumulative stress over a period of years, or after even a relatively short period of time in the athlete, can result in pathological changes at the insertional area of the Achilles tendon. Pathologic changes within the tendon and at the tendon's insertion are similar in character to those seen at the plantar aspect of the calcaneus in a patient with heel spur syndrome. Microscopic changes include fibrinoid and myxomatous degeneration, fibrosis, and eventual calcification within the tendon¹. Black and Kanat² described three distinct types of calcification—metastatic, calcinosis, and dystrophic. In most cases of calcifications of the tendo Achillis, these calcifications are of the dystrophic type, as they occur in the presence of normal

metabolism in damaged or devitalized tissues. Unusual distal tears of the Achilles tendon have also been implicated as a possible cause of the retrocalcaneal exostosis pain, as the posterosuperior calcaneal prominence may repeatedly irritate the tendon upon ankle joint dorsiflexion³.

CLINICAL PRESENTATION

The clinical presentation of the patient with a retrocalcaneal exostosis or spurring within the tendo Achillis is very similar to that of the patient suffering from a Haglund's deformity. The patient may complain of pain, tenderness, erythema, and edema which may be increased with activity or certain types of shoes. Typically, the patient experiences a dull, aching pain with localized tenderness near the insertion of the Achilles tendon. Occasionally, a palpable "hardness" or "thickening" may be noted in the Achilles tendon just proximal to its insertion into the calcaneus. This might represent concomitant calcification of the tendon itself. Patient ages range from the early twenties to the seventies, but the presentation is more common in middle-aged or older patients. When seen in younger patients, they are usually involved in athletics or are obese. The condition is more commonly seen in women, most likely secondary to the shoe styles they tend to wear^{4,5}.

The retrocalcaneal exostosis or spurring within the insertion of the Achilles tendon can occur concomitantly with a Haglund's deformity, retrocalcaneal bursitis, Achilles tendinitis, or plantar heel spur syndrome, and care should be taken to distinguish between these conditions. This differentiation is best accomplished by assiduous clinical palpation and radiographic evaluation. The painful retrocalcaneal exostosis will be identified with direct palpation of the insertional area of the tendo Achillis. Generally, this will be the point of maximum tenderness, although the patient may have pain which extends around this area. The

pain may be aggravated by passive and active ankle joint range of motion, especially dorsiflexion. Radiographically, a standard lateral view will demonstrate the retrocalcaneal exostosis, posterior calcaneal step, or intratendinous spur. Occasionally, the exostosis and/or spur will be accompanied by soft tissue calcifications within the Achilles tendon. If desired, radiographs taken with soft tissue attenuation or xeroradiography may be utilized to further assess these calcifications.

SURGICAL CONSIDERATIONS

Surgical approaches to the retrocalcaneal exostosis and spur vary depending upon the extent of the deformity and the size of the intratendinous spur. If the spur is small and asymptomatic, then procedures similar to those used for a Haglund's deformity can be utilized to resect the retrocalcaneal exostosis. However, when the spur is large and/or symptomatic, or if the retrocalcaneal exostosis or posterior calcaneal step closely approximates the tendo Achillis, an intratendinous approach will be necessary. In this case, several surgical approaches are available. The first involves a lateral or medial approach where the corresponding border of the Achilles tendon is gradually incised until the prominent bone and spur are appropriately exposed. This results in release of only one border of the tendon, and is a viable approach when the retrocalcaneal exostosis and/or spur are primarily located underneath the lateral or medial aspects of the tendon.

A second, more aggressive approach, involves complete release of the Achilles tendon from its insertion, thereby exposing the entire retrocalcaneal exostosis and spur. This approach is considered when the exostosis or spur involves the entire posterior aspect of the calcaneus. In either of these approaches, once the exostosis or spur is resected, the tendon is repaired by reattaching it to itself and/or the calcaneus.

Both of these approaches, and particularly the complete release, can suffer from difficulty in recreating proper physiologic tension on the tendo Achillis during closure. Further, both can be prone to rupture of the tenotomized segment. For this reason, a third approach involving a midline incision through the tendo Achillis has become popular. This approach permits the medial and lateral insertional expansions of the Achilles tendon

to remain intact. Thus, after appropriate bone has been resected, the tendon can be closed side-to-side and physiologic tension is maintained. This side-to-side closure can be reinforced with reattachment to the calcaneus if substantial amounts of bone have been removed and the central portion of the tendon has been weakened from its insertion⁶. This tendon-splitting approach can also allow exposure to any intratendinous calcifications that might be present. This approach can result in postoperative tendon rupture, but the natural tension and more normal anatomic contour diminish the likelihood of this possibility.

The author has been performing a modified Fowler-Philip approach to the retrocalcaneal exostosis and spur since 1987. Fowler and Philip⁷ first described an inverted "Y" incision through the tendon in 1945. They described their rationale for this approach based upon their observations of the anatomic insertion of the Achilles tendon:

"The central portion of the tendon is inserted into the middle area on the posterior surface of the bone, while the lateral parts of the tendon sweep on to the medial and lateral surfaces of the os calcis, so that the central part of the tendon can be divided transversely, avoiding the lateral expansions, and when the central portion is resutured, there is little risk of permanently weakening the tendo Achillis."

The author advocates either an inverted "V" or "Y" approach through the Achilles tendon in this fashion. This approach allows removal of any retrocalcaneal exostosis or spur, and any intratendinous calcifications present.

SURGICAL TECHNIQUE

The surgical technique for the modified Fowler-Philip approach is best performed with the patient in a prone position (Fig. 1A-B). Typically, general inhalation or spinal anesthesia is utilized with a mid-thigh pneumatic tourniquet. If desired or medically necessary, the procedure can be performed with the patient in the lateral or supine position, under local anesthesia, and without a tourniquet.

The surgical approach is usually either through a midline, longitudinal incision or a lazy "S"-shaped incision (Fig. 2). These approaches are different from that advocated by Fowler and Philip.

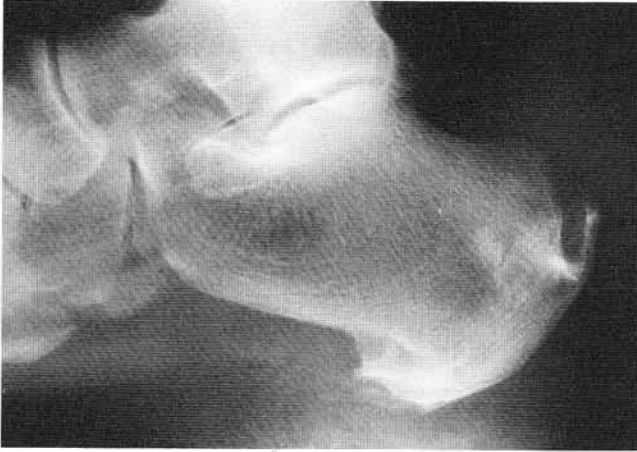

Figure 1A. Preoperative radiographic appearance of a patient with a large retrocalcaneal exostosis and spur.

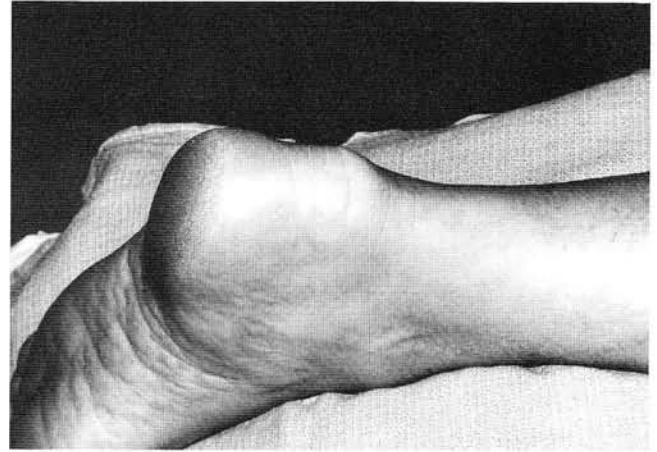


Figure 1B. Preoperative clinical appearance. Note the prominence extends across the entire posterior aspect of the heel.

Fowler and Philip⁷ utilized a curved transverse incision with the convexity of the incision directed upwards. The author has not utilized this approach as the longitudinal approaches provide better exposure of the Achilles tendon.

Dissection is then carried bluntly through the subcutaneous tissue until the deep fascia is visualized. Care is taken to avoid the sural nerve and the lesser saphenous vein during this dissection (Fig. 3). With the subcutaneous tissues retracted, a single inverted "V" or "Y" incision is then made through the deep fascia, paratenon, and tendon (Fig. 4). The apex of the "V" is centered at the dorsal aspect of the spur which can be easily palpated through the tendon. The arms of the "V" or "Y" are then carried medially and laterally to the distal extent of the exostosis or spur. The arms are typ-

ically 1 to 1.5 cm in length. If no intratendinous calcifications are noted, the inverted "V" approach is usually sufficient. If calcifications are present, the inverted "V" is converted into an inverted "Y" and the tendon is split more proximally in its midline to excise the calcifications. Once the tendon has been incised, the "V" flap created is reflected distally with care paid to preserve its distal attachment. The retrocalcaneal spur, step, and/or exostosis is then exposed (Fig. 5).

Resection of the exostosis and spur is then accomplished with osteotomes or power instrumentation (Fig. 6). The author generally prefers curved osteotomes to remove the bulk of the bone, followed by a power reciprocating rasp to contour the remaining bone. After an appropriate amount of bone has been removed, the tendon is reanchored to bone

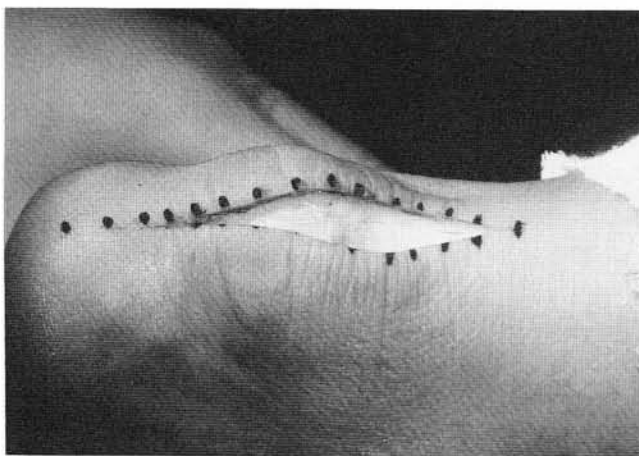


Figure 2. Posterior midline incision for approach to retrocalcaneal exostosis.

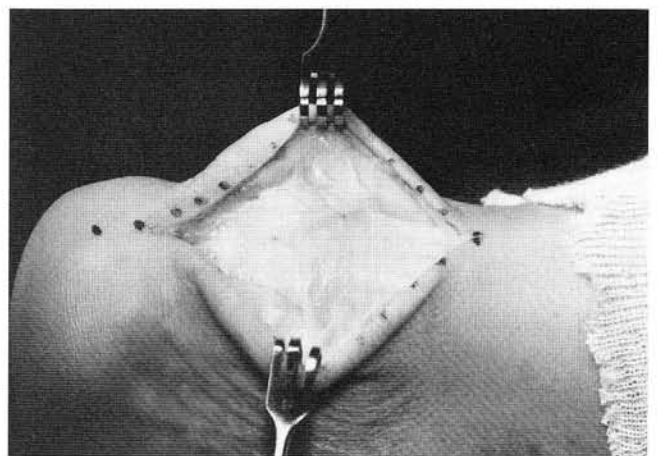


Figure 3. Dissection through the superficial fascia and subcutaneous layer reveals the deep fascia.

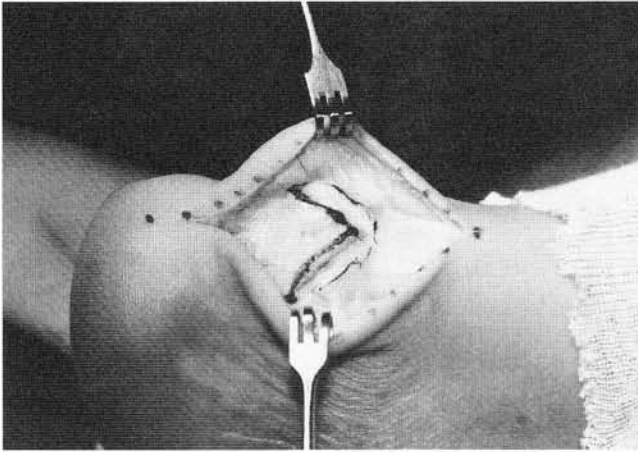


Figure 4. The retrocalcaneal exostosis and spur are palpated, and an inverted "V"-shaped incision is made through the deep fascia, paratenon, and Achilles tendon.

with suture (Fig. 7). This is a modification of the Fowler and Philip procedure, as they did not discuss this reattachment. The author feels the reattachment strengthens the repair. The reattachment can be accomplished by suturing the tendon to bone with nonabsorbable suture through drill holes or by using a soft tissue-bone anchor system (Figs. 8A-D).

Once the tendon has been reattached to bone, the "V" or "Y" incision through deep fascia, paratenon, and tendon is repaired as one layer with 2-0 absorbable or nonabsorbable suture (Fig. 9). The subcutaneous tissue is approximated with 4-0 absorbable suture, and skin is closed with 5-0 absorbable suture in subcuticular fashion (Fig. 10). Adhesive wound strips, a saline moistened sponge, a dry sterile dressing, and a below-knee Jones'

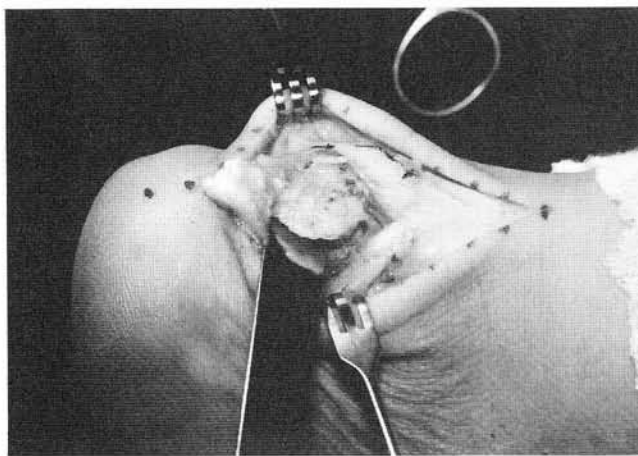


Figure 6. An osteotome is used to resect the retrocalcaneal exostosis and spur.

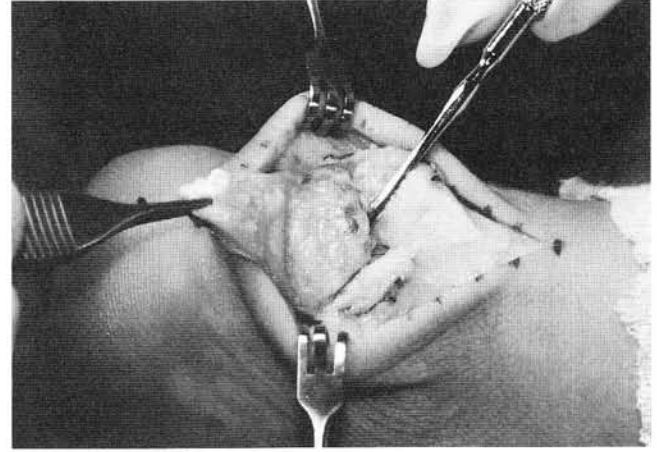


Figure 5. The "V"-shaped flap is then reflected distally exposing the prominent bone. Note the Freer elevator is identifying the retrocalcaneal spur.

compression dressing are applied. Postoperative radiographs are taken on the day of surgery or within the first postoperative week (Fig. 11).

POSTOPERATIVE CARE

In the immediate postoperative period, a below-knee Jones' compression dressing is utilized to minimize edema and associated postoperative pain. A dressing change is usually performed in the first 3 to 5 days postoperative, and if the edema is controlled, a below-knee synthetic cast is applied. The cast is applied with the ankle and subtalar joints in their neutral position. The patient is kept non-weight-bearing for 4 to 8 weeks in the cast. If the patient is continuing to demonstrate edema, pain, or is obese, the cast may be maintained for

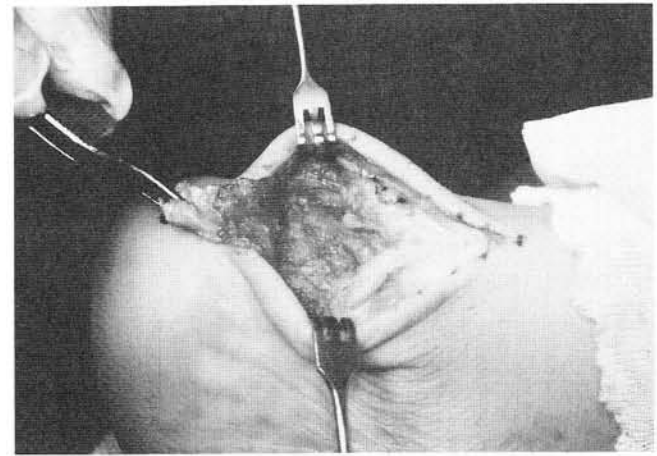


Figure 7. Appearance of retrocalcaneal area after bone resection and contouring, and prior to closure.

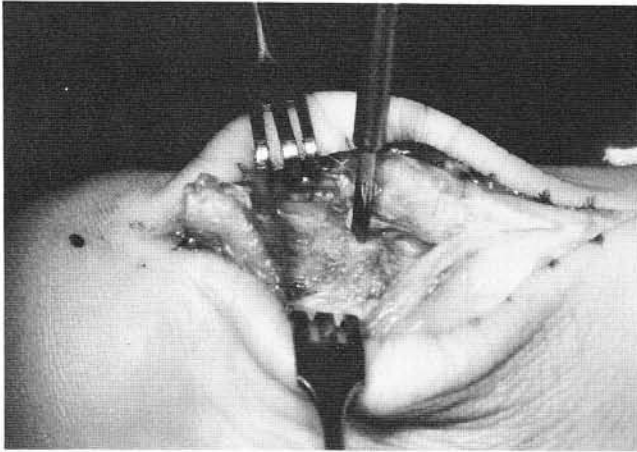


Figure 8A. Reattachment of tendo Achillis with a Mitek soft tissue-bone anchor system. A drill hole is made into the calcaneus for insertion of the bone anchor.

a longer period. After the period of non-weight-bearing immobilization, the patient is gradually returned to weight bearing. This is typically accomplished with a walking synthetic or soft cast, or a Cam-walker type cast for an additional 3 to 6 weeks.

Following cast removal, appropriate rehabilitation is started including range of motion exercises for the ankle and subtalar joints, and strengthening exercises of the calf musculature. Compression with supportive material or an ankle brace is continued until most of the edema has resolved, and the patient is able to ambulate with minimal difficulty. Long-term, orthoses and appropriate shoes are advised.

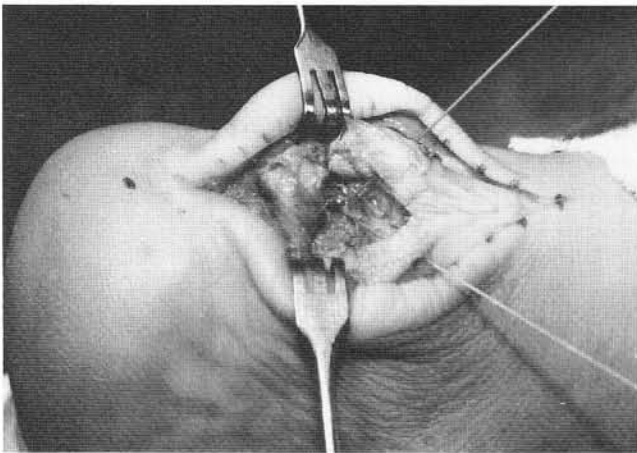


Figure 8C. Anchor in place, and the suture is passed through the tendon.

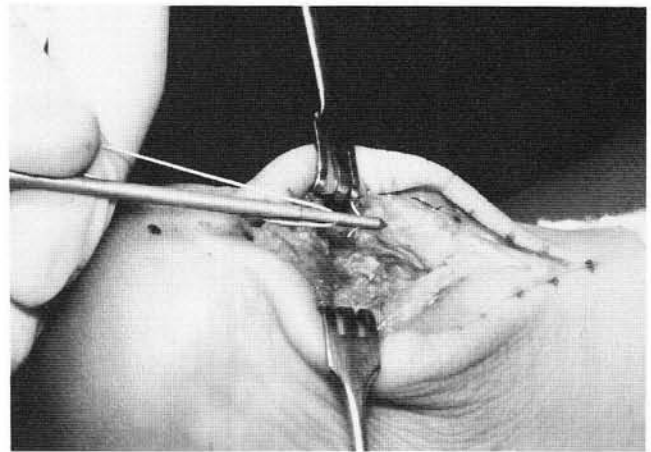


Figure 8B. G2 bone anchor ready to be inserted into the drill hole.

COMPLICATIONS

The primary complications associated with this approach are related to the Achilles tendon. Rupture of the tendon is always a possibility in any surgical approach involving temporary detachment of the tendo Achillis. However, this is unusual if proper postoperative treatment and care are provided. More common is postoperative tendinitis of the Achilles tendon. If this occurs, it typically starts when the patient begins unsupported weight bearing, and gradually resolves over the next 2 to 3 months. If the tendinitis does not resolve, appropriate treatment similar to that for any Achilles tendinitis is instituted. If the pain continues, the clinician should reassess the posterior heel area to rule-out any other conditions which might be

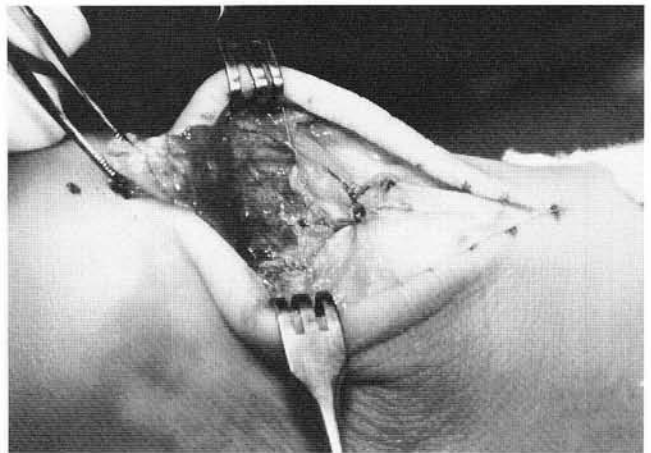


Figure 8D. The suture is tied and tendon reapproximated to bone. Two Mitek G2 bone anchors were used in this case.

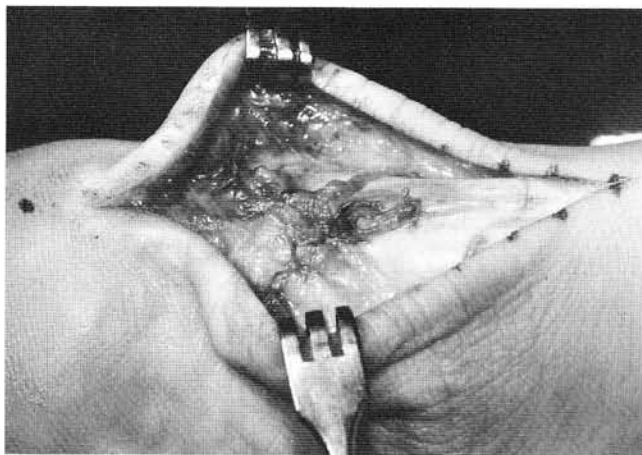


Figure 9. Closure of "V" flap of tendon along with paratenon and deep fascia.

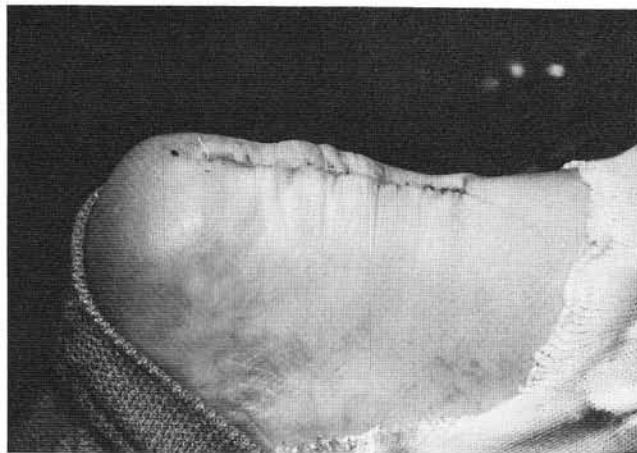

Figure 10. Final skin closure of wound.

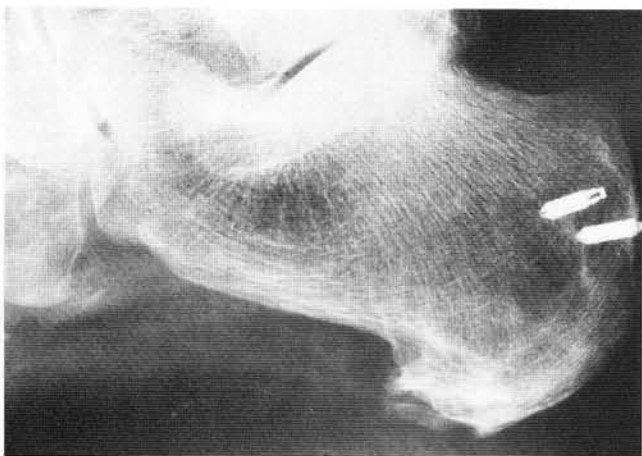


Figure 11. Postoperative radiographic appearance demonstrates adequate resection of retrocalcaneal exostosis and spur with good position of bone anchors.

contributing to the ongoing pain syndrome.

Sundberg and Johnson⁸ state that "excessive subcutaneous scarring" is a drawback of the classic Fowler-Philip surgical approach. However, the classic Fowler-Philip approach utilized a curved transverse incision through both the skin and deeper structures. In the author's experience, the posterior longitudinal skin incision combined with the inverted "V" or "Y" extension through the deeper structures has rarely led to any significant scarring problems. However, handling of the soft tissues in a meticulous fashion and the use of anatomic dissection cannot be under-emphasized. If a postoperative wound dehiscence or painful cicatrix develops, they should be treated in an appropriate fashion.

CONCLUSIONS

The decision to perform a retrocalcaneal exostectomy with reflection and reattachment of the tendo Achillis should not be made hurriedly. The procedure requires a significant postoperative recovery period and is associated with several dreaded postoperative complications. When indicated, the author has found the modified Fowler-Philip approach to be a simple, reproducible, and reliable surgical procedure.

REFERENCES

1. Malay DS: Heel surgery. In McGlamry ED, Banks AS, Downey MS (eds.): *Comprehensive Textbook of Foot Surgery*, 2nd ed. Baltimore, Williams & Wilkins, 1992, pp. 431-455.
2. Black AS, Kanat IO: A review of soft tissue calcifications. *J Foot Surg* 24:243-250, 1985.
3. Fiamengo SA, Warren RF, Marshall JL, Vigorita VT, Hersh A: Posterior heel pain associated with a calcaneal step and Achilles tendon calcification. *Clin Orthop* 167:203-211, 1982.
4. Downey MS, Kalish S: Surgical excision and repair of calcifications of the tendo Achillis. In McGlamry ED (ed): *Doctors Hospital Podiatric Education and Research Institute Surgery of the Foot and Leg 1986*. Tucker, Georgia, Podiatry Institute Publishing Company, 1986, pp. 134-139.
5. Downey MS, Kalish S: Surgical excision and repair of calcifications of the tendo Achillis. In Ruch JA, Vickers NS (eds.): *Reconstructive Surgery of the Foot and Leg - Update '92*. Tucker, Georgia, Podiatry Institute Publishing Company, 1993, pp. 275-282.
6. Smith TF: Calcification of the tendo Achillis: dissection and repair. In Camasta CA, Vickers NS, Ruch JA (eds.): *Reconstructive Surgery of the Foot and Leg - Update '93*. Tucker, Georgia, Podiatry Institute Publishing Company, 1993, pp. 275-282.
7. Fowler A, Philip JF: Abnormality of the calcaneus as a cause of painful heel: its diagnosis and operative treatment. *Br J Surg* 32:494-498, 1945.
8. Sundberg SB, Johnson KA: Painful conditions of the heel. In Jahss MH (ed.): *Disorders of the Foot and Ankle - Medical and Surgical Management*, 2nd ed., Vol. 2. Philadelphia, WB Saunders, 1991, pp. 1382-1395.