

The Modified Evans Ankle Stabilization For Correction Of Lateral Ankle Instability

James L. Bouchard, D.P.M.

INTRODUCTION

One of the most common injuries of the lower extremity is the lateral ankle ligamentous disruption. In recent years, with greater emphasis on physical fitness, the chronically painful and unstable lateral ankle is an increasing common clinical finding presenting to the podiatrist's office. In many cases, these potentially disabling injuries are commonly dismissed as a benign condition or minor ankle sprain, and treated with a supportive elastic bandage or splint. Early diagnosis and appropriate treatment are essential in preventing sequelae such as chronic instability, pain, swelling, and degenerative joint changes commonly seen in the chronically painful and unstable ankle. Most lateral ankle ligamentous injuries may be considered a stage one supination-adduction injury by the Lauge-Hansen classification. Subsequent inversion injuries to an unstable ankle face the risk of a stage two supination-adduction injury, with associated medial malleolar fracture and increased incidence of degenerative joint disease or post traumatic arthritis.

Historically, ankle stabilization surgical techniques have primarily been devised to correct either a single ligamentous repair involving the anterior talofibular ligament, or a double ligamentous repair involving both the anterior talofibular ligament and the calcaneofibular ligament.

The split peroneus brevis lateral ankle stabilization (SPBLAS) has proven to be a dependable surgical technique for stabilization of the unstable ankle by the members of the Podiatry Institute over the past twenty years. The SPBLAS is a modification of many other previously described lateral ankle stabilization techniques utilizing the peroneus brevis tendon as tendon graft to replace the weakened or injured anterior talofibular ligament and calcaneofibular ligament. This is usually accomplished through a single curvilinear hockey

stick incision on the lateral aspect of the ankle. Due to the amount of dissection and necessity of securing the transferred tendon graft to the body of the calcaneus in a trephine hole, prolonged immobilization and postoperative rehabilitation, is necessary which complicates the postoperative course by prolonging the patient's return to normal daily activities.

Figure 1 demonstrates the single skin incision for the SPBLAS procedure. Essentially the entire portion of the peroneus brevis tendon is used proximally, which represents approximately one half of the peroneus brevis at the insertion of the 5th metatarsal, as the tendon becomes more tendinous at its distal insertion. Due to the extensive dissection and rehabilitation time with the conventional SPBLAS technique, members of the Podiatry Institute have modified the procedure in recent years to combine the deep fascia incisions at

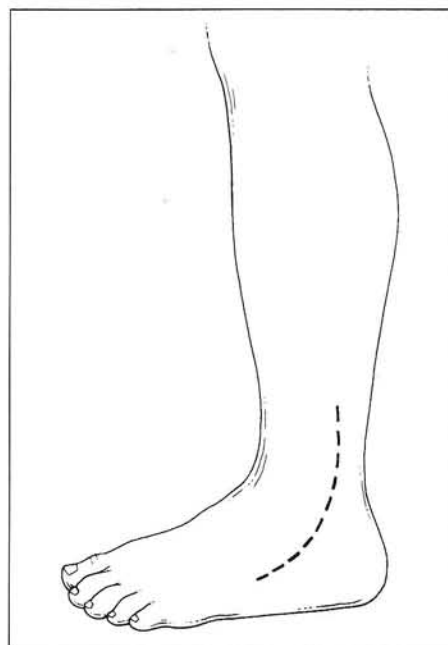


Figure 1. The single skin incision for the SPBLAS procedure.

selected areas for transfer of the peroneus brevis tendon, utilizing smaller incisions in the deep fascia rather than complete dissection through its entire length. This has resulted in decreased postoperative pain and swelling, but no significant effect on the patient's early return to normal activity. A consistent drawback to the procedure has been the arthrotomy of the ankle, with inspection of the joint surface and examination of the lateral collateral ligaments of the ankle, which is required during the excessive dissection and exposure.

The author has used with success, over the last seventeen years, a modified three skin incision approach, avoiding the long hockey stick incision characterized by extensive lateral dissection of the ankle. The three incision approach includes a distal incision over the base of the 5th metatarsal at the insertion of the peroneus brevis tendon. This is performed in a linear fashion following the tendon's insertion, approximately 2.5 cm to 3.0 cm in length. The second incision is an oblique incision following the skin lines at the level of the anterior inferior aspect of the head of the fibular. This is used to isolate the tip of the fibula, which is required for transfer of the tendon through a trephine hole in the fibula. This incision is approximately 4.0 cm in length, and can be extended inferiorly if reattachment of the peroneus brevis tendon graft to the body of the calcaneus is necessary, as is often required with more severe ligamentous disruptions. The third incision is a linear incision following the posterior course of the fibula. Figure 2 demonstrates the placement of the three incision technique, particularly when combined with the modified Evans procedure. Patients typically have decreased pain and swelling, and quicker rehabilitation due to the decreased amount of surgical dissection.

HISTORICAL REVIEW OF THE SURGICAL TECHNIQUES

Double Ligamentous Lateral Ankle Repairs

Figure 3 demonstrates the SPBLAS procedure, with transfer of one half of the peroneus brevis tendon through the fibula, and then attachment to the body of the calcaneus through a trephine hole at the calcaneofibular ligament insertion site. Elmslie utilized a double-ligament repair through a similar long hockey stick incision, transferring the tendon

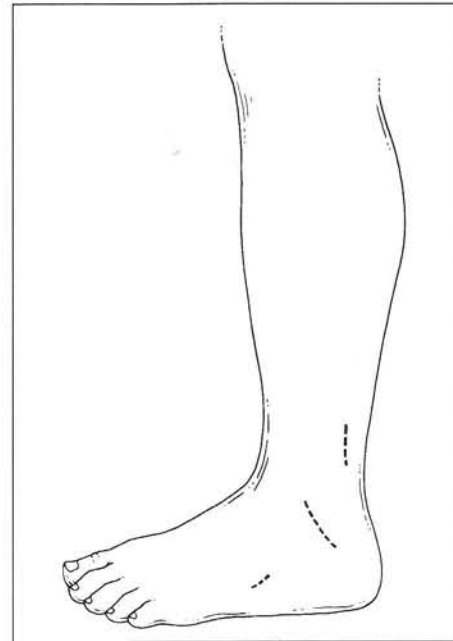


Figure 2. Skin incision for modified Evans.

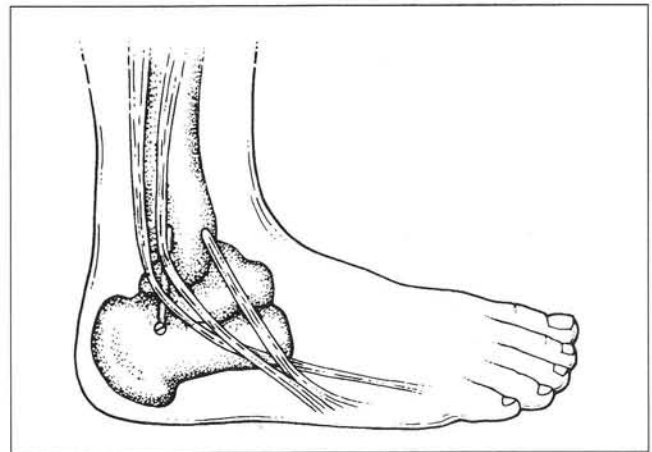


Figure 3. Split peroneus brevis lateral ankle stabilizing procedure.

graft through a canal in the fibula, then through the calcaneus and lateral aspect of the talus. A strip of fascia is utilized covering the double ligament repair (Fig. 4). Christman and Shook used half of the peroneus brevis tendon as a modification of the Elmslie procedure leaving the half of the peroneus brevis tendon intact. The peroneus brevis tendon is transferred through a canal in the fibula, reattached to the lateral aspect of the calcaneus, and then to the peroneus brevis tendon (Fig. 5).

Hambly modified the procedure by splitting the peroneus longus rather than the peroneus

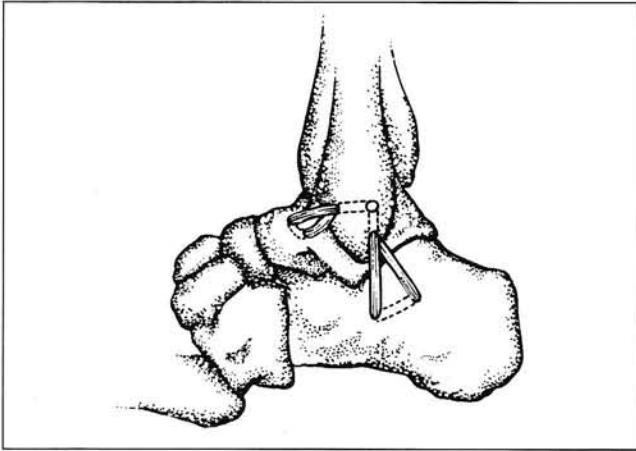


Figure 4. Elmslie double-ligament reconstruction.

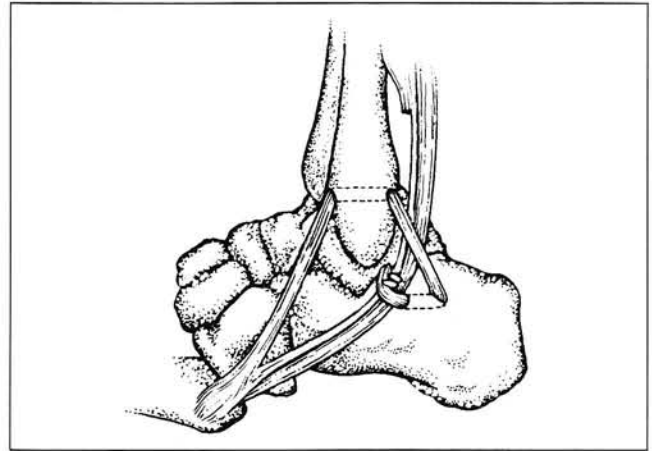


Figure 5. Christman and Shook lateral ankle stabilization.

brevis. The tendon is passed through the fibula, sutured through the lateral aspect of the talus, and then inserted into the calcaneofibular ligament. This modification also utilized a long hockey stick incision to expose the lateral aspect of the ankle (Fig. 6).

Whinfield described a procedure for lateral ankle stabilization similar to that of Hambly, however, the peroneus brevis is used instead of the peroneus longus tendon. The double ligament ankle stabilization, described by Whinfield, is illustrated in Figure 7.

There have been various other double ligament lateral ankle repairs reported in the literature. The skin incision and dissection necessary for exposure, in most of these cases, is characterized by postoperative pain, swelling, and increased rehabilitation.

Single Ligamentous Lateral Ankle Repair

Watson-Jones utilized the entire peroneus brevis tendon, leaving its distal insertion intact. The tendon is passed through a canal in the fibula, into the neck of the talus, back through the fibula, and then attached to itself posteriorly at the level of the fibula. Figure 8 demonstrates the transfer of the entire peroneus brevis tendon, which requires extensive dissection to obtain exposure for transfer of the tendon.

Lee modified the Watson-Jones procedure due to the technical difficulty in obtaining adequate tendon length for transfer. The Lee modification utilizes the entire peroneus brevis tendon, passing it posterior to anterior through a canal in the fibula,

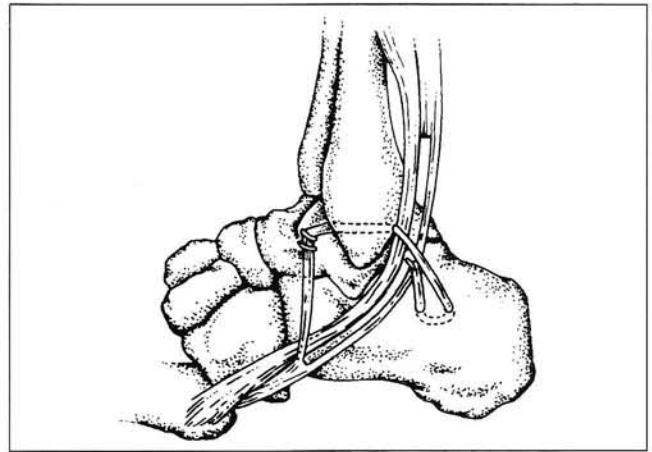


Figure 6. Hambly's lateral ligament reconstruction procedure.

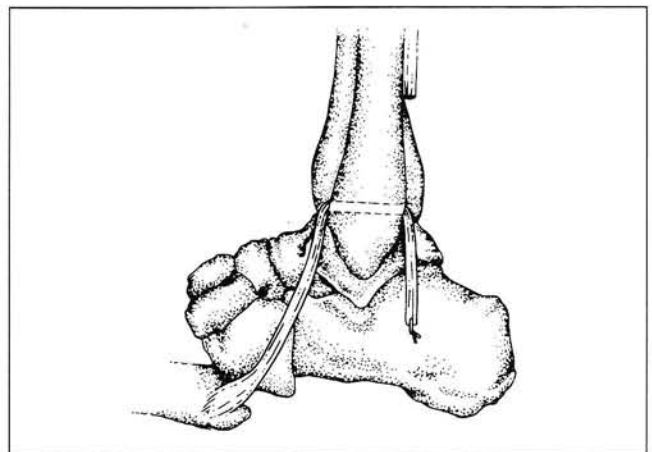


Figure 7. Whinfield double-ligament lateral ankle stabilization.

and suturing the peroneus brevis tendon distally and inferiorly upon itself (Fig. 9).

Nilsonne detached the peroneus brevis at the musculotendinous junction, passed the tendon through a canal in the fibula, and reattached it into a subperiosteal groove in the lateral aspect of the fibula. The remaining proximal portion of the peroneus brevis muscle is attached to the peroneus longus tendon, as outlined in Figure 10.

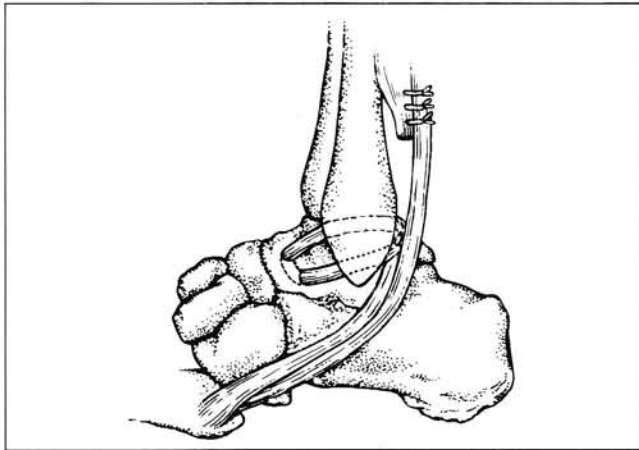


Figure 8. Watson-Jones lateral ankle ligament repair.

In addition to the peroneus brevis and peroneus longus tendon transfer, many investigators have utilized portions of the Achilles and plantaris tendons for stabilization of the ankle. These procedures require additional extensive dissection and postoperative rehabilitation.

Evans, after detaching the peroneus brevis tendon from the musculotendinous junction proximally, sutured the remaining muscle belly of the peroneus brevis to the peroneus longus tendon. With the peroneus brevis tendon insertion intact, the tendon was then passed through a canal in the fibula, attaching the transferred tendon to the posterior aspect of the distal fibula (Fig. 11). The Evans procedure has been modified by members of the Podiatry Institute utilizing one half of the peroneus brevis tendon transferred through a canal in the distal fibular and inserted into the lateral calcaneus. The author has modified the conventional Evans procedure, utilizing three separate skin and deep fascia incisions, thus decreasing the amount of surgical dissection, postoperative edema, pain, and rehabilitation.

PREOPERATIVE CONSIDERATION

A thorough history of the nature of the ankle injury is essential for proper diagnosis and treatment of lateral ankle instability. Patients with complaints of daily ankle pain, swelling, or instability which interferes with daily activity or athletic performance are candidates for lateral ankle ligamentous surgical correction. In most cases, surgical correc-

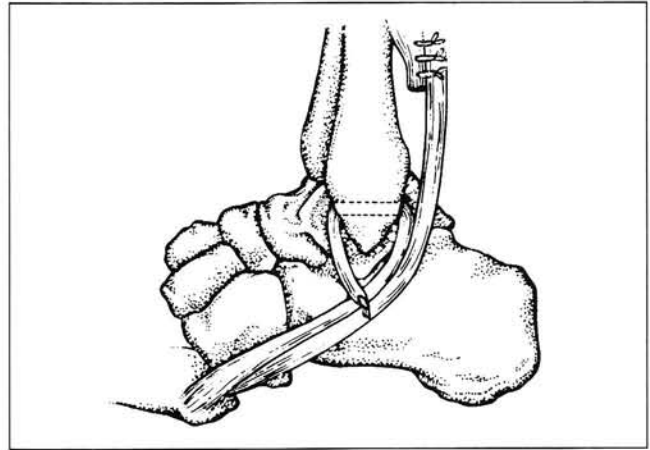


Figure 9. Lee lateral ankle stabilization.

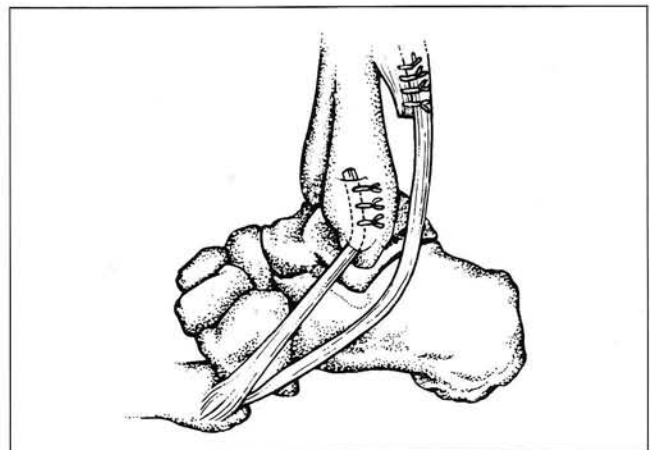


Figure 10. Nilsonne lateral ankle ligament repair.

tion is reserved for patients with disabling recurrent instability, where conservative therapy has failed.

Patients with a chronically injured lateral ankle will usually present with a palpable dell or spongy area along the course of the anterior talofibular ligament and calcaneofibular ligament, with associated pain and tenderness. Pain on inver-

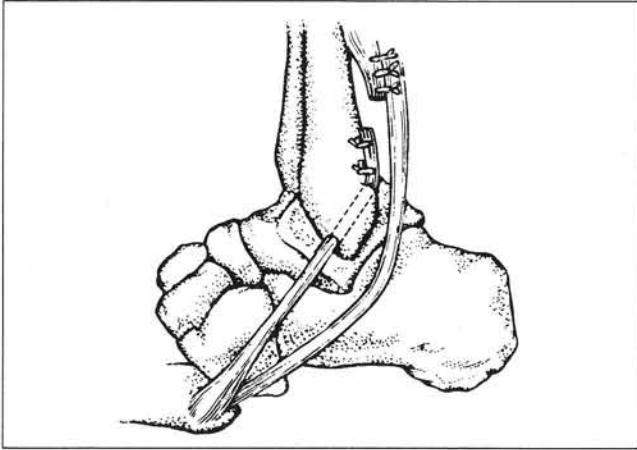


Figure 11. Evans lateral ankle stabilization.

sion of the ankle and subtalar joints is a frequent finding with associated lateral instability. Subluxation or dislocation of the peroneal tendons must also be suspected in severe injuries. Typically, conventional ankle radiographic findings are negative, except for occasional osteoarthritic changes. A small loose osseous body, from ligamentous avulsions, is often noted on radiographic evaluation.

Stress radiographs are often the greatest aid in determining the degree of chronic lateral ankle instability. Stressed radiographs of the ankle conventionally include the stress inversion and anterior drawer tests. Stress radiographs may be performed bilaterally for comparison purposes, as patients with ligamentous laxity may normally present with excessive inversion of the ankle, sometimes in excess of 18-20 degrees. Thus, a patient with no history of ankle injury may have a talar tilt of 18-20 degrees secondary to ligamentous laxity. Most investigators agree that a talar tilt difference of 18 degrees or more is indicative of double ligamentous injury to the lateral ankle (Fig. 12). The stress inversion view is relied upon as a more accurate diagnostic test, in comparison to the anterior drawer, for assessment of ankle stability. The anterior drawer test is not relied upon as much as the stress inversion test. Anterior displacement of the talus greater than 4.0 mm is considered to be a positive result, indicating lateral ligamentous injury (Fig. 13). Occasionally, stress testing of the ankle may be negative, despite the patient's continued instability and need for ankle stabilization. Therefore, a negative stress radiographic examina-

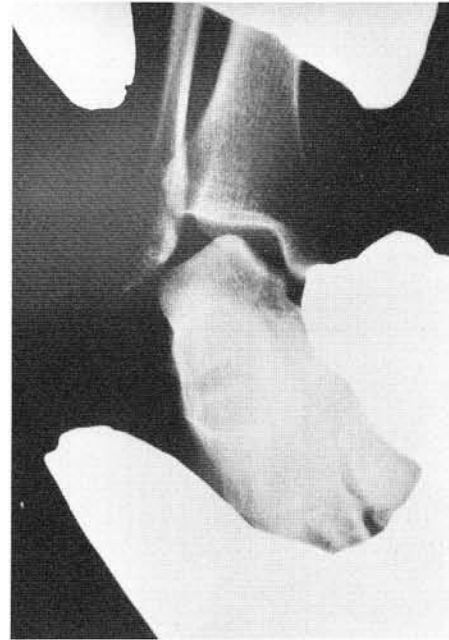


Figure 12. A positive stress inversion radiograph.

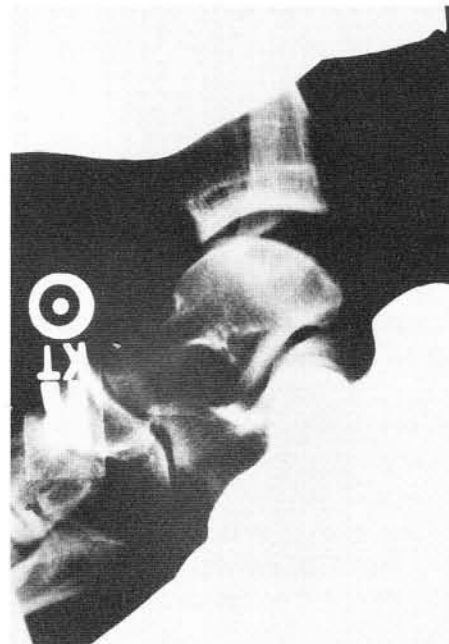

Figure 13. A positive anterior-drawer sign.

tion should not be considered an absolute contraindication to stabilization.

In more recent years, magnetic resonance imaging (MRI), has been of great benefit in determining the extent of ligamentous injury to the lateral ankle. Prior to the development of MRI,

ankle arthrograms have been used to demonstrate the extent of lateral ankle injury, especially when ankle capsule rupture or peroneal tendon subluxation/dislocation is present.

SURGICAL TECHNIQUE

The patient is placed on the operating room table in a lateral position with the use of a vacuum pack. A pneumatic thigh tourniquet is often used to facilitate hemostasis, however, the infiltration of a local anesthetic with epinephrine (1 to 200,000) may be utilized as an alternative to the tourniquet. The proper positioning of the patient facilitates dissection and decreases surgical time. Care must be taken in positioning the patient to avoid compression at the head of the fibula (common peroneal nerve) and lateral malleolus by using appropriate padding.

The surgical approach to the modified Evans procedure is performed through three separate skin incisions rather than the conventional 15-17 cm hockey stick incision which extends from the base of the 5th metatarsal to above the ankle joint. The anatomic landmarks for the three incisions are outlined with a skin scribe, and include the base of the 5th metatarsal, distal 1/3 of the fibula, and the anterior lateral ankle joint and calcaneus. The proposed length of the peroneus brevis tendon graft can be estimated with the use of sterile umbilical tape to outline its course. Accurate placement of the skin incisions is necessary to provide adequate exposure to the underlying structures.

The incisions are deepened through the subcutaneous layers to the level of the deep fascia utilizing the conventional concepts of anatomical dissection. Hemostasis is achieved with either suture ligation of larger vessels or electric cautery. The sural nerve is protected throughout the procedure, and is usually encountered when the middle incision is extended distally and inferiorly towards the calcaneus. Deep fascia remains intact except for the areas of potential transfer, including splitting of the tendon distally at the insertion at the base of the 5th metatarsal, rerouting of the tendon at the anterior inferior aspect of the lateral malleolus, and securing of the tendon to the posterior aspect of the fibula following the transfer through the osseous canal.

Kalish and DiNapoli (1989) described the SPBLAS procedure utilizing three small deep fascia

incisions after performing the conventional long hockey stick incision. Although findings suggest decreased swelling and edema, the modified Evans procedure is less traumatic since it does not involve transfer of the peroneus tendon to a trephine hole in the body of the calcaneus. Typically, the deep fascia is incised along the complete course of the lateral hockey stick incision.

The peroneal retinaculum is also preserved during dissection to avoid complications such as postoperative peroneal tendosynovitis. At the proximal incision posterior to the fibula, the myotendinous junction of the peroneus brevis tendon is identified and retracted. Approximately 3/4 of the myotendinous junction at this level is incised and prepared for splitting of the peroneus brevis tendon into two portions. The released end of the tendon is then secured with a 2-0 absorbable suture. Attention is then directed to the distal incision where a tendon passer or double braided stainless steel wire is introduced under the tendon sheath of the peroneus brevis tendon, extending proximally around the lateral ankle to the posterior aspect of the distal 1/3 of the fibula. At this point, the suture-tagged peroneus brevis myotendon is secured to the wireloop or tendon passer, and withdrawn distally, thereby dividing the peroneus brevis tendon into two portions. The superior portion of the tendon is passed sub-periosteally to the level of the inferior margin of the fibula, where an osseous canal is made with a small 4.0 mm trephine. Care is taken to direct the trephine hole in the center of the lateral malleolus to avoid injury to the ankle joint, exiting posteriorly in the middle portion of the distal fibula. The angle of the osseous channel is intended to approximate the position of the anterior talofibular ligament. Occasionally an arthrotomy will be performed in conjunction with the procedure, to inspect the articular surface of the talofibular joint, and to reinforce the ankle joint capsule during closure of the middle incision. In the modified Evans procedure, half of the peroneus brevis tendon is attached to the posterior aspect of the fibula, and then reattached proximally to the remaining myotendinous junction of the peroneus brevis. With this technique, there are three points of fixation of the tendon graft. The first anchor point is at the anterior inferior margin of the distal aspect of the fibula, which is secured with 2-0 non-absorbable suture. The second point of attachment is at the

posterior fibula, following transfer of the tendon through the osseous canal, also with 2-0 non absorbable suture. Finally, proximal reattachment of the peroneus brevis tendon to the myotendinous junction is performed with 2-0 non- absorbable suture. During this procedure, care is taken to hold the foot in slight eversion to allow for an appropriate amount of correction. After securing the transferred tendon graft, stability of the rearfoot and ankle can be appreciated. However, securing of the tendon graft under extreme tension can lead to subtalar joint pain, stiffness, and eventual arthritis.

A modification of the SPBLAS procedure is often employed to reinforce a weakened or ruptured calcaneofibular ligament. This entails transfer of the tendon into the lateral body of the calcaneus and requires lengthening of the middle incision inferiorly to the level of the calcaneus. In this case, a trephine is used to remove a corticocancellous plug of bone from the lateral body of the calcaneus, approximately 1.5-2.5 cm in depth. The free end of the tendon is inserted into the trephine hole, and the bone is packed around the tendon's new insertion in the lateral calcaneus. Thus, the peroneus brevis tendon is used for reconstruction of the calcaneo fibular ligament. The surgeon must anticipate the need for additional length of the peroneal brevis tendon by lengthening the proximal incision. During surgery, sterile saline is used to moisten the tissues, particularly the tendons, to avoid dehydration of these structures. Care is also taken to avoid contact of the tendinous structures with the skin, thus reducing the chance of a postoperative infection. A unique characteristic of both the SPBLAS and modified Evans procedures is that the split tendon is routed in a subperiosteal-subcapsular fashion, extending from the base of the 5th metatarsal along the lateral aspect of the talus, and exiting at the anterior inferior margin of the fibula, at the site of the trephine hole.

The deep fascia incisions are then closed using 2-0 or 3-0 absorbable suture. In most cases, a closed section drain is utilized at the middle or second incision, at the level of the ankle joint. Superficial fascia is closed with 3-0 or 4-0 suture, with special care taken to avoid trauma to the sural nerve. Finally, the skin is closed with either 4-0 or 5-0 absorbable or non-absorbable suture, followed by the application of steri-strips. A moist saline dressing is applied, and the ankle is stabilized with a compression dressing and/or cast.

Although the procedure can be performed on an outpatient basis, overnight admission is recommended. Removal of surgical drains and the application of a below the knee weight-bearing cast can be preformed prior to discharge.

The patient is usually casted for 4 to 6 weeks and following cast removal, range of motion exercises are resumed. The patient will benefit from the use of high-top shoes following cast removal for added stability, during the final stages of healing. In many cases, an ankle splint or air cast may be utilized.

COMPLICATIONS

The most common postoperative complication following lateral ankle stabilization is a transient tenosynovitis of the peroneal tendons around the ankle joint. This accounts for 15% of the postoperative complaints. Transient tenosynovitis can be effectively treated with compression, ice, rest and immobilization. On occasion, nonsteroidal anti-inflammatory drugs (NSAIDs) are utilized. In more symptomatic cases of tenosynovitis, local injections of dexamethasone phosphate may be beneficial.

Another frequent postoperative finding is swelling related to the surgical procedure. Post operative swelling and inflammation are normal but excessive swelling and inflammation should be addressed. Excessive swelling and edema may prolong the rehabilitation process. The applications of rest, ice, compression and elevation are important in treating postoperative edema, which may take four to six months to resolve in more severe cases. Other complications include continued ankle instability, hypertrophic scarring, wound dehiscence, infection, and sural nerve entrapment or neuritis. These are rare complications, but the patient should be informed of these potential complications from a risk management concern.

The transferred tendon graft can potentially be placed under too much tension, holding the foot in a position of eversion, causing pain and limitation of subtalar or ankle joint motion. In these cases, a "Z-plasty" lengthening or release of the transferred tendon can relieve symptoms and reverse the condition if treated in the early stages. Although rare, fracture of the fibula or violation of the talofibular articulation has been reported in the literature. This usually occurs during placement of the trephine hole in the fibular canal. Should this

occur, open reduction and internal fixation may be necessary, or in more severe cases, ankle fusion may be necessary. Transient dysesthesias and paraesthesias associated with sural nerve entrapment have been reported, as well as postoperative sural nerve neuroma formation. These conditions can be readily prevented by careful surgical dissection and preservation of the nerve during the surgery.

RESULTS

In a retrospective study of 25 cases involving the modified Evans lateral ankle stabilization over the last 17 years, 95% of the patients reported good to excellent results and their willingness to undergo the surgery if they were given the choice again. These patients were able to resume their normal activity prior to the surgery. There were no patients who had recurrent symptoms of ankle instability, however, it should be noted that the procedure was not performed on patients with a talar tilt greater than 12-15 degrees, or symptoms suggesting calcaneofibular ligament disruption.

Transient tenosynovitis was the most common postoperative finding reported, and three of the patients in the sample responded well to local treatment consisting of rest, ice, compression, and elevation. In addition, one of the cases of transient tenosynovitis required a series of three injections of dexamethasone phosphate. In the retrospective study, there were no cases of sural nerve entrapment or sural neuroma. However, one case of transient neuritis was reported, which responded to conservative treatment consisting of rest, strapping, and the use of ice.

In several of the cases performed, preoperative stress x-rays did not demonstrate ankle instability with the stress inversion and anterior drawer test, however, the patients did have instability of the rear foot and ankle due to a pes cavus foot type with an associated plantar flexed first ray. These patients benefited greatly from the modified Evans ankle stabilization's elimination of excessive subtalar joint supination. These patients did not undergo dorsiflexory wedge osteotomy of the first metatarsal, nor rearfoot arthrodesis, and their symptoms were eliminated with the modified Evans ankle stabilization. The most common finding was decreased swelling, pain, edema, and early return to normal activity when comparing the mod-

ified Evans procedure to the conventional SPBLAS procedure. The postoperative course involved four to six weeks of casting rather than six to eight weeks of casting, with less need for aggressive physical therapy. Patients, in most cases, were able to resume prior activity within twelve to fourteen weeks, and in some cases from eight to twelve weeks.

SUMMARY

The modified three incision approach for performance of the SPBLAS and modified Evans procedure has been successfully utilized by members of the Podiatry Institute over the last 17 years. Through the modified three incision approach, the single ligamentous disruption (talofibular ligament) or the double ligamentous injury (anterior talofibular and calcaneofibular ligaments) can be addressed. In more severe cases of ligamentous disruption involving both ligaments, the modified Evans procedure may prove to be inefficient in controlling ankle instability, thus necessitating similar procedures such as the SPBLAS technique designed for double ligamentous disruption. Early diagnosis and assessment of the ankle injury is essential in determining the optimal surgical results.

BIBLIOGRAPHY

- Abraham E, Stirnaman JE: Neglected rupture of the peroneal tendon causing recurrent sprains of the ankle. *J Bone Joint Surg* 61A:1247-1248, 1979.
- Alm A, Lanske LO, Liljedhal SO: Surgical treatment of dislocation of the peroneal tendons. *Injury* 7:14, 1975.
- Bernstein RH, Bartolomei FJ, McCarthy DJ: Sinus tarsi syndrome: anatomical, clinical and surgical considerations. *J Am Podiatr Med Assoc* 75:475, 1985.
- Bolton CW, Bruchman WC: The Gore-Tex expanded polytetrafluorethylene prosthetic ligament. *Clin Orthop* 196:202-213, 1985.
- Bonnin JG. Cited in Dziob JM: Ligamentous injuries about the ankle-joint. *Am J Surg* 91:692, 1956.
- Borovoy M, Beresh AS: Approaches to lateral ankle repair: recurrent ankle sprains. *J Foot Surg* 21:127-131, 1982.
- Brostrom L: Sprained ankles. III. Clinical observations in recent ligament ruptures. *Acta Chir Scand* 132:537-550, 1965.
- Brown JE: The sinus tarsi syndrome. *Clin Orthop* 18:231-233, 1960.
- Cass JR, Morrey BF, Katoh Y, Chad EYS: Ankle instability: comparison of primary repair and delayed reconstruction after long term follow up study. *Clin Orthop* 198:110-117, 1985.
- Christman OD, Snook GA: Reconstruction of lateral ligament tears of the ankle: an experimental study and clinical evaluation of seven patients treated by a new modification of the Elmslie procedure. *J Bone Joint Surg* 51A:904, 1969.
- D'Ambrosia RD, Shoji H, Van Meter J. Cited in Pierre RK, Rosen J, Shitesides TE, Szczukowski M: The tensile strength of the anterior talofibular ligament. *Foot Ankle* 4:83, 1983.
- DiNapoli RD, Kalish S: Split peroneus brevis lateral ankle stabilization

- 15 years of experience at doctors hospital. In McGlamry Ed (ed) *Reconstructive Surgery of the Foot and Leg*, Update 88. pp. 120-128, 1988.
- Elmslie RC: Recurrent subluxation of the ankle-joint. *Ann Surg* 100: 364-367, 1934.
- Evans Ga, Hardcastle P, Frenyo AD: Acute rupture of the lateral ligament of the ankle. *J Bone Joint Surg* 66B:209-212, 1984.
- Eyring EJ, Guthrie WD: A Surgical approach to the problem of severe lateral instability at the ankle. *Clin Orthop* 206:185-191, 1986.
- Frank C, Amiel D, Woo SL, Akeson W: Normal ligament properties and ligament healing. *Clin Orthop* 196:15-25, 1985.
- Gillespe HS, Boneher P: Watson Jones repair of lateral instability of the ankle. *J Bone Joint Surg* 53A:920-924, 1971.
- Goldstein LA: Tear of the lateral ligament of the ankle. *NY State J Med* 48:199, 1948.
- Gould N, Seligson D, Gassman J: Early and late repair of lateral ligament of the ankle. *Foot Ankle* 1:84-89, 1980.
- Haig H: Repair of ligaments in recurrent subluxation of the ankle joint. *J Bone Joint Surg* 32B:751, 1950.
- Heller AS, Vogler HW: Ankle joint arthroscopy. *J Foot Surg* 21:23-29, 1982.
- Jenkins DHR, McKibbin B: The role of flexible-carbon-fiber implants in tendon and ligament substitutes in clinical practice. *J Bone Joint Surg* 62B:497-499, 1980.
- Johnson EE, Makolf KL: The contribution of the anterior talofibular ligament to ankle laxity. *J Bone Joint Surg* 65A:81-88, 1983.
- Kalish S, Ruch J, Boberg J: Primary repair vs. SPBLAS. In McGlamry ED (ed): *Doctors Hospital Podiatry Institute Surgical Seminar Syllabus-1984*, Tucker, Ga, Podiatry Institute Publishing, 1984, pp62-67.
- Kelikian H, Kelikian AS: Disorders of the Ankle, Philadelphia, WB Saunders, 1985, pp 559-564. Landeros O, Frost HM, Higgins CC: Post-traumatic anterior ankle instability. *Clin Orthop* 56:169-178, 1968.
- Lauge-Hansen N: Ligamentous ankle fractures: diagnosis and treatment. *Acta Chir Scand* 97:544-550, 1949.
- Leach RE, Namki O, Paul GR, Stockel J: Secondary reconstruction of the lateral ligaments of the ankle. *Clin Orthop* 160:201, 1981.
- Leach RE: Acute ankle sprain: treat vigorously for best results. *J Musculoskeletal Med* 83:68, 1983.
- Lowy A, Schilero J, Kanat IO: Sinus tarsi syndrome: a postoperative analysis. *J Foot Surg* 24:108-112, 1985.
- Menelaus MB: Injuries of the anterior inferior tibiofibular ligament. *Aust N Z J Surg* 30:279-287, 1961.
- Moeller FA: The os trigonum syndrome. *J Am Podiatry Assoc* 63:491-501, 1973.
- Nicholas JA: Ankle injuries in athletes. *Orthop Clin North Am* 5:153, 1974.
- Nilsonne H: Making a new ligament in ankle sprain. *J Bone Joint Surg* 14:380-381, 1932.
- Rechtine HF, McCarroll JR, Webster DA: Reconstruction for chronic lateral instability of the ankle: a review of twenty eight surgical patients. *Ortho* 5:46-50, 1982.
- Riegler HF: Reconstruction for lateral instability of the ankle. *J Bone Joint Surg* 66A:336-339, 1984.
- Ruch JA: Comprehensive evaluation and treatment of the lateral ankle sprain. In Schlefman B (ed): *Doctors Hospital Surgical Seminar Syllabus-1982*. Tucker, GA, Podiatry Institute Publishing, 1982, pp.179-186.
- Rosenberg ZS, Cheung Y, Jahss M: Computed tomography scan and magnetic resonance imaging of ankle tendons: an overview. *Foot Ankle* 8:297-307, 1988.
- Rubin G, Witten M: The talar tilt angle and the fibular collateral ligaments. *J Bone Joint Surg* 42A:311, 1960.
- Snook G, Chrisman O, Wilson T: Long-term results of the Chrisman-Snook operation for reconstruction of the lateral ligaments of the ankle. *J Bone Joint Surg* 67A:17, 1985.
- St Pierre R, Andrews L, Allman F Jr, Fleming LL: The Cybex II elevation of lateral ankle ligamentous reconstructions. *Am J Sports Med* 12:52-56, 1984.
- Staples OS: Ruptures of the fibular collateral ligaments of the loaded ankle. *J Bone Joint Surg* 57A:101-107, 1975.
- Turco VJ: Injuries to the ankle and foot in athletics. *Orthop Clin North Am* 8:669-682, 1977.
- Van Der Rut AJ, Evans GA: The long-term results of Watson-Jones tenodesis. *J Bone Joint Surg* 66B:371-375, 1984.
- Visser HJ, Oloff LM, Jacobs AM: Lateral ankle stabilization procedures: criteria and classification. *J Foot Surg* 19:74, 1980.
- Watson-Jones R: Fractures and Other Bone and Joint Injuries Edinburgh, E&S Livingstone, 1940, p. 416.
- Winfield P: Treatment of undue mobility of the ankle joint following severe sprain of the ankle with avulsion of the anterior and middle bands of the external ligament. *Acta Chir Scand* 105:299-304, 1953.
- Zoellner G, Clancey W: Recurrent dislocation of the peroneal tendon. *J Bone Joint Surg* 61A:292, 1979.