

# Current Concepts Of Peripheral Neurectomy

*Michael S. Downey, D.P.M.*

## INTRODUCTION

Resection of a Morton's neuroma is the most common example of surgical neurectomy of a peripheral nerve. The time proven success of this procedure might falsely lead the surgeon to believe that neurectomy for other peripheral nerves of the lower extremity can be met with a similar success rate. Unfortunately, this is not the case. In fact, Morton's neuroma resection is the only frequently performed neurectomy in the entire body. Except for Morton's neuroma extirpation, surgical neurectomy of a peripheral nerve should be avoided whenever possible. External and/or internal neurolysis should be attempted whenever the entrapped nerve or neuroma has a reasonable chance for recovery. Routine performance of peripheral neurectomy for entrapped or damaged nerves will frustrate both the surgeon and the patient. Peripheral neurectomy frequently can result in continuing pain syndromes related to stump neuroma formation, causalgia, bothersome hypoesthesia, or increased compensatory sensation" in surrounding previously unaffected peripheral nerves. However, when the peripheral nerve is damaged to an extent that neurolysis has failed or is unlikely to be beneficial, and conservative measures have failed, peripheral neurectomy may still be the primary option. This paper reviews the author's current recommendations regarding peripheral neurectomies about the foot and ankle.

## DIAGNOSIS

The patient with a painful peripheral nerve entrapment or neuroma will typically present with symptomatology related to the damaged or affected nerve(s). Typically, the pain has a primary sensory component and is described by the patient as "burning, shooting, or lacerating" pain. A thorough history should be taken from the patient with possible peripheral nerve pathology.

Once suspected, a complete physical examination should be performed. This examination

should include observation and palpation of the suspected neuroma or damaged nerve, and sensory testing. Since most peripheral nerve injuries have sensory involvement before motor involvement, sensory testing will often be the "key" to the diagnosis. Reflex examination and skeletal motor testing should also be included in the evaluation. If a peripheral nerve entrapment or neuroma is suspected, the particular nerve or nerves involved may be temporarily anesthetized to help confirm the diagnosis. With the combination of sensory testing and diagnostic nerve blocks, most peripheral neuromas and entrapped nerves can be diagnosed. If larger nerves are involved, electrodiagnostic studies or diagnostic imaging modalities such as MRI may be considered to help confirm or support the diagnosis.

## TREATMENT

Once a peripheral nerve entrapment has been diagnosed, treatment can be instituted. In most cases, conservative measures should be attempted prior to surgical intervention. These conservative measures most often include local steroid or sclerosing injections, oral anti-inflammatories, biomechanical support or control, physical therapy modalities including iontophoresis or phonophoresis and desensitization techniques, and topical medications such as capsaicin. When conservative treatment has failed or been deemed inappropriate, surgical intervention is considered. As stated earlier, external and/or internal neurolysis should be considered initially if there is a reasonable chance for the neurolysis to result in nerve recovery. If there is minimal or no chance that neurolysis can lead to nerve recovery, or if neurolysis has failed, peripheral neurectomy should be considered. Obviously, resection of the typical Morton's neuroma represents the exception to this approach, as neurectomy has proven to be a reliable method for the management of this condition.

Neurectomy involves the excision of a segment of nerve. At times, especially when the nerve

provides critical sensation and the distal nerve and sensory receptors are available, neurectomy combined with nerve reconstruction may be the most viable approach. If function of the entrapped nerve is not critical, or if previous attempts at neurolysis or nerve reconstruction have failed, then resection of the nerve with or without transposition of the remaining nerve stump is indicated.

Neurectomy is performed by isolating the entrapped portion of nerve, neuroma in-continuity, or stump neuroma. Dissection is carried proximally until normal nerve is identified. Once the normal nerve trunk is delineated, sharp sectioning of the nerve is performed as far proximally as possible through this normal nerve tissue. The entrapment or neuroma site may then be excised. Once the entrapped portion of nerve has been resected, numerous operative techniques to inhibit axonal regrowth and transposition away from painful stimuli have been described (Table 1). Each of these methods attempts to diminish stump neuroma formation and/or attempts to transpose the nerve to an area subjected to the least possible amount of mechanical stimulation.

**Table 1**

**SURGICAL TREATMENT FOR  
TRANSECTED NERVE ENDING**

**INHIBITION OF AXONAL REGROWTH**

**Physical Containment**

**Chemical Treatment**

- Alcohol
- Phenol
- Formaldehyde
- Nitrogen mustard
- Pepsin
- Hydrochloric acid
- Iodine
- Gentian violet
- Steroids

**Cautery**

- Electrocoagulation
- Laser
- Radiofrequency current
- Cryosurgery

**Ligation**

**Synthetic Containment**

- Silicone caps
- Rubber
- Plastic
- Lucite
- Polyethylene
- Collodium
- Cellophane
- Metallic foil
- Tantalum
- Glass
- Nerve glue

**Physiologic Containment**

- Epineurorrhaphy
- Nerve grafting

**TRANSLOCATION AWAY FROM  
PAINFUL STIMULI**

- Excision and retraction
- Implantation into muscle
- Implantation into bone
- En bloc translocation

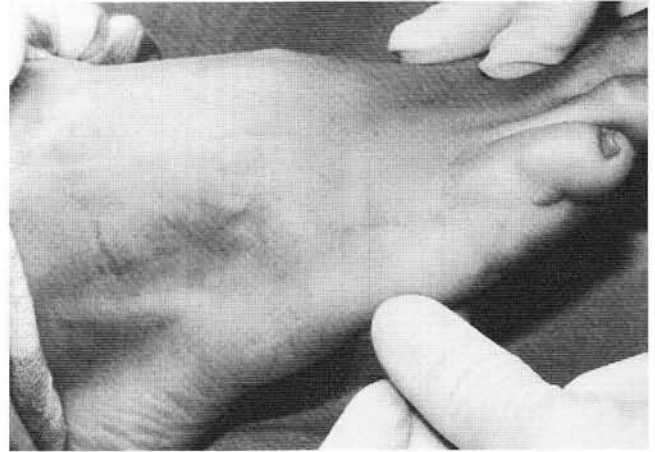
(Adapted from Downey MS: Management of neurologic trauma. In Scurran BL (ed) *Foot and Ankle Trauma* New York, Churchill Livingstone, 1989, p. 245)

Inhibition of axonal regrowth or stump neuroma formation has been attempted via physical containment, synthetic containment, and physiologic containment. Physical containment includes the use of alcohol, phenol, formaldehyde, nitrogen mustard, pepsin, hydrochloric acid, iodine, gentian violet, or insoluble steroids after neurectomy to attempt chemical cautery or inhibition of further neuroma formation. Further, neurectomy with electrocoagulation, laser cautery, radiofrequency current, and cryosurgery attempt thermal cautery of the nerve stump. Synthetic containment includes the use of inert materials such as silicone caps, rubber, plastic, lucite, polyethylene, collodium, cellophane, and gold foil, tantalum, glass, and nerve glues to attempt containment. Physiologic containment with epineurorrhaphy has been used alone or in conjunction with physical or synthetic containment. Although long-term clinical studies with these varying methods are scarce, these approaches have had minimal reported success at diminishing recurrent stump neuroma formation, and some have been associated with foreign body reactions.

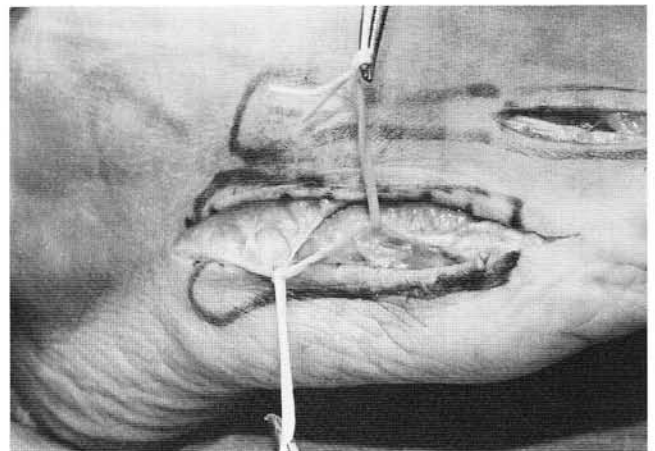
Transposition of a resected nerve end away from potential irritation appears to be preferable to *in situ* containment. Excision of a neuroma and allowing the nerve end to retract proximally may be of benefit, as it allows the nerve ending to rest in a proximal site away from the surgical incision and original site of entrapment. However, if the nerve end comes to rest in a poor soft tissue bed or continues to be irritated, this approach will be doomed to failure. Resection of the classic Morton's neuroma is an example of excision of a portion of nerve with proximal retraction of the nerve stump.

Alternatively, the resected end of the nerve may be transplanted into bone or muscle. The structure used should be in close proximity to the nerve ending, and subject the nerve to the least possible amount of mechanical irritation. Whenever possible, the author generally prefers implantation of the nerve ending into innervated, well-vascularized muscle or bone away from denervated skin and scar tissue. Mackinnon and Dellon<sup>1</sup> coined the term "neurotrop(h)ism" to suggest influences that facilitate both nerve fiber maturation and appropriate direction of regeneration. Recent research suggests that cut nerve endings implanted into innervated muscle are least likely to demonstrate significant "neurotrop(h)ism," thus the nerve is least likely to attempt regeneration in innervated muscle tissue<sup>2,3</sup>. Implantation into muscle is accomplished by suturing the epineurium into the belly of the muscle. If the surgeon prefers or if an appropriate muscle belly is not available, bone may be used<sup>4,5</sup>. A small trephine hole is made into the bone and the epineurium is sutured into the opening created, thus burying the cut end of the nerve into bone (Figs. 1A-1H).

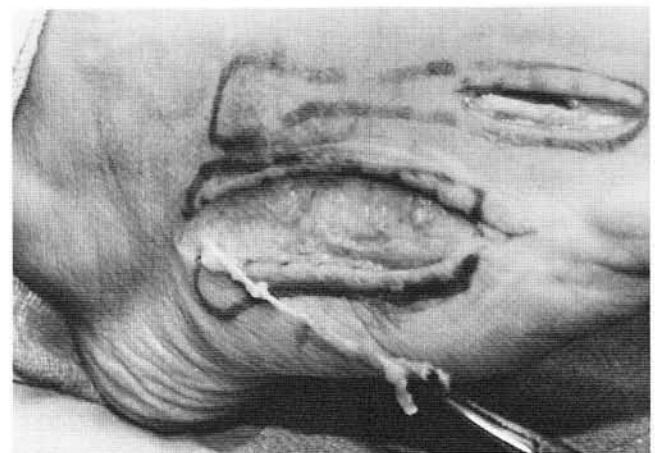
Finally, en bloc transfer of an intact neuroma, or neuroma resection with primary neurorrhaphy or grafting may be considered. Herndon et al.<sup>6</sup> reported 72% minimally painful or tender results following en bloc transfer of intact neuromas with their fibrous scar tissue encapsulation to an adjacent area that was more protective and free from scar tissue. Although these results are promising, en bloc transfer would not appear to offer any advantage over implantation of a freshly cut nerve ending into bone or muscle. Hattrup and Wood<sup>7</sup> reported 77% (10 of 13) of their patients had diminished symptomatology following neurectomy with interfascicular grafting. However, nerve



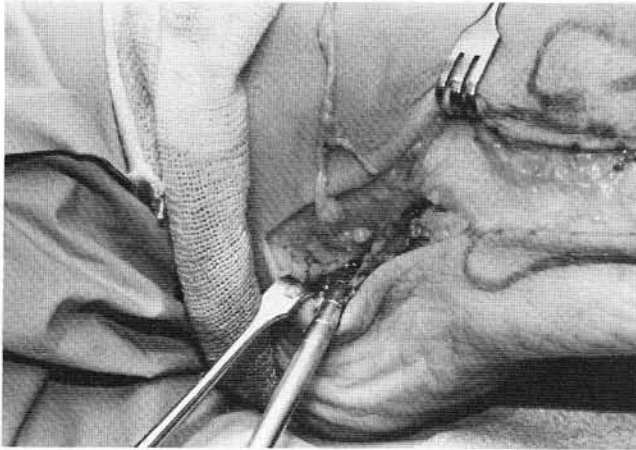
**Figure 1A.** Sural neuroectomy with implantation of nerve stump into lateral calcaneus. Preoperative appearance. Patient developed post-incisional sural nerve entrapment following two previous tailor's bunions procedures.



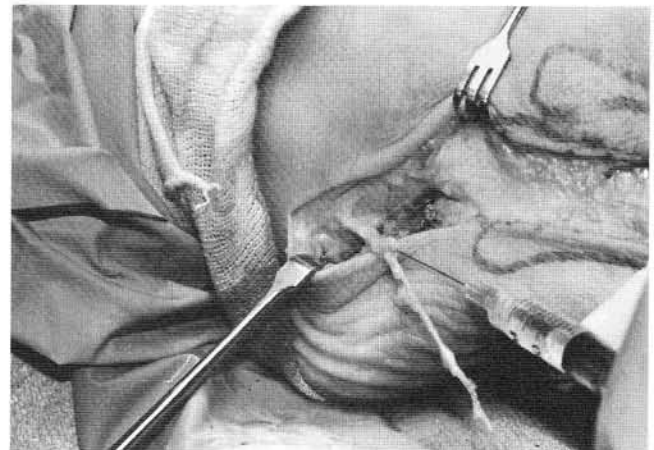
**Figure 1B.** Sural nerve harvested, evaluated, and determined to be extensively damaged.



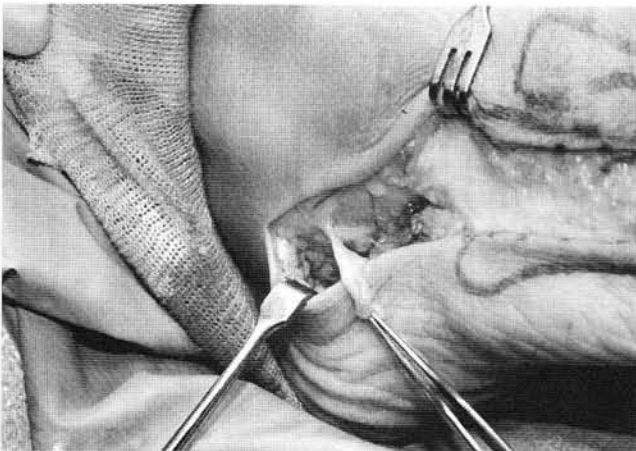
**Figure 1C.** Sural nerve resected distally and then carefully dissected proximally to the lateral calcaneal area.



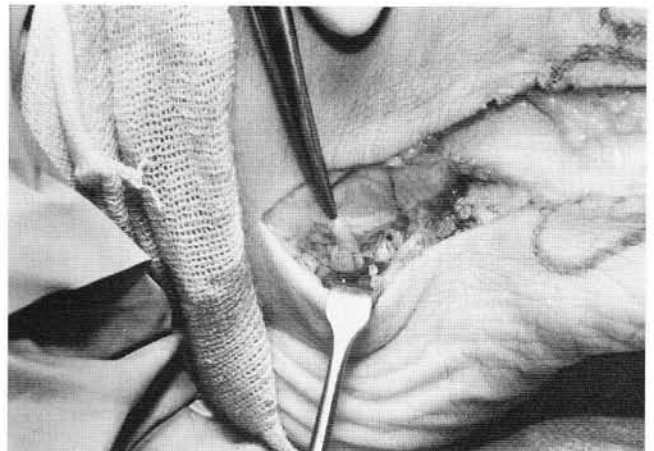
**Figure 1D.** Trephine hole made in the lateral calcaneal wall.




**Figure 1E.** Proximal portion of sural nerve injected with small amount of dexamethasone phosphate.



**Figure 1F.** Sural nerve sharply transected proximally, maintaining just enough length to implant nerve stump into calcaneus.



**Figure 1G.** Epineurium of nerve stump is sutured into trephine hole in the calcaneus. The hemostat points to the implanted nerve stump.



**Figure 1H.** Resected portion of sural nerve sent for pathologic evaluation.

reconstruction is generally reserved for nerves with a major motor component, and when considering the foot and ankle, would be limited to recalcitrant lesions of the posterior tibial nerve.

Following neurectomy, the soft tissues should be closed in anatomic fashion. A compression dressing should be applied and a closed suction drain utilized if necessary. Protected weight bearing or non-weight bearing should be considered for the first 2 to 4 weeks. Range of motion exercises and rehabilitative modalities should be instituted after 7 to 10 days, and accelerated after wound healing.

## COMPLICATIONS

Peripheral nerve surgery can be very rewarding, but just as often can be frustrating for both the surgeon and patient. Even with an accurate preoperative diagnosis, good intraoperative technique, and proper postoperative management, complications can occur. Therefore, the preoperative development of a good patient-physician rapport with a thorough, informed discussion of the procedure, alternatives, potential risks and complications, and postoperative course is critical to the success of the procedure. Aside from the complications inherent to any surgery in the lower extremity, peripheral neurectomy has a unique set of potential complications which include: recurrent entrapment and neuroma formation, sensorimotor alterations as the sensory and motor components of the nerve are altered, and reflex sympathetic dystrophy or causalgia as the sympathetic component of the nerve is irritated. In any particular patient, each of these complications has the potential to cause pain greater than that experienced prior to surgery.

## SUMMARY

With the exception of neurectomy for a classic Morton's neuroma, peripheral neurectomy should be considered a "last resort" for the management of lower extremity nerve entrapments and neuromas. When peripheral neurectomy is necessary, the author advocates implantation of the transected nerve end into either innervated skeletal muscle or bone. In this fashion, many of the complications associated with peripheral neurectomy can be reduced or eliminated.

## REFERENCES

1. Mackinnon SE, Dellon AL: *Surgery of the Peripheral Nerve*, New York, Thieme Medical Publishers, 1988.
2. Dellon AL, Mackinnon SE: Treatment of the painful neuroma by neuroma resection and muscle implantation. *Plast Reconstr Surg* 77:427-436, 1986.
3. Mackinnon SE, Dellon AL, Hudson AR, Hunter DA: Alteration of neuroma formation by manipulation of its microenvironment. *Plast Reconstr Surg* 76:345-352, 1985.
4. Boldrey E: Amputation neuroma in nerves implanted in bone. *Ann Surg* 118:1052-1057, 1943.
5. Goldstein SA, Sturim HS: Intraosseous nerve transposition for treatment of painful neuromas. *J Hand Surg* 10A:270-274, 1985.
6. Herndon JH, Eaton RG, Littler JW: Management of painful neuromas in the hand. *J Bone Joint Surg* 58A:369-373, 1976.
7. Hattrup SJ, Wood MB: Delayed neural reconstruction in the lower extremity: results of interfascicular nerve grafting. *Foot Ankle* 7:105, 1986.

## ADDITIONAL REFERENCES

- Downey MS: Management of neurologic trauma. In Scurran BL (ed) *Foot and Ankle Trauma* New York, Churchill Livingstone, 1989, pp.219-246.
- Holmes GB Jr: Nerve compression syndromes of the foot and ankle. In Gould JS (ed) *Operative Foot Surgery* Philadelphia, WB Saunders, 1994, pp. 184-191.
- Malay DS, McGlamry ED: Acquired neuropathies of the lower extremities. In McGlamry ED, Banks AS, Downey MS (eds) *Comprehensive Textbook of Foot Surgery*, 2nd Ed, Baltimore, WilliamsWilkins, 1992, pp. 1095-1123.
- Merrill TJ: Peripheral nerve entrapment syndromes of the lower extremity. In Marcinko DE (ed) *Medical and Surgical Therapeutics of the Foot and Ankle* Baltimore, Williams & Wilkins, 1992, pp.239-252.