

# THE MODIFIED WATERMANN PROCEDURE: A Preliminary Retrospective Study

*Gregory Laakmann, D.P.M.*

*Richard M. Green, D.P.M.*

*Donald R. Green, D.P.M.*

There are numerous approaches to the surgical treatment of hallux limitus. These range from the relatively benign soft tissue release,<sup>1,2</sup> and cheilectomy,<sup>1,11</sup> to the joint destructive procedures.<sup>12,16-21</sup> Scattered in between these extremes are various phalangeal and metatarsal osteotomies that can be utilized in the treatment of hallux limitus.<sup>13-15</sup> With such a wide variety of procedures to choose from, all having various indications, contraindications, advantages and disadvantages, the decision on the most appropriate procedure for the patient with hallux limitus is quite challenging.

In 1987, Bernbach and McGlamry<sup>22</sup> suggested a step-wise surgical approach to hallux limitus. This began with a cheilectomy, progressed to a Watermann-type or Austin type procedure, then to a plantar-declinator wedge osteotomy, and finally an implant. The following year, Bernbach<sup>23</sup> added an additional procedure to this step-wise approach: the Green-Watermann procedure. He termed this the procedure of choice for hallux limitus. This technique has also been mentioned by Vanore<sup>2</sup> as a treatment for hallux limitus.

This latter technique, the Green-Watermann, or modified Watermann procedure, will be discussed. In order to evaluate its effectiveness in patients with hallux limitus deformity, a retrospective study was performed evaluating specific preoperative and postoperative subjective and objective criteria.

### HALLUX LIMITUS

The minimum amount of hallux dorsiflexion needed for normal gait is 65 degrees at the first metatarsophalangeal joint, as defined by Root, Orien, and Weed.<sup>24</sup> Hallux limitus is a limitation of hallux dorsiflexion at the first metatarsophalangeal joint. Hallux rigidus is a complete lack of range of

motion of this joint. However, in order to choose the most appropriate procedure for hallux limitus correction, one must first understand its etiology.

### Etiology

One of the first to describe hallux rigidus was Davis-Colley<sup>25</sup> in 1887, who suggested an abnormally long hallux in an unyielding and short boot as an etiology. Since then, there have been various theories on the etiology of hallux limitus and rigidus.<sup>26-37</sup>

Cochrane<sup>26</sup> in 1927, felt that hallux rigidus, previously unresponsive to osseous procedures leaving a residual elastic resistance to dorsiflexion, was secondary to shortened and contracted plantar first metatarsophalangeal joint structures. These structures included the contracted plantar fibers of the lateral ligaments as well as the spasm of the intrinsic muscles of the hallux. The importance of soft tissue structures and their relation to hallux limitus was also emphasized by Durrant<sup>27</sup> in 1993. In 1954, Hicks<sup>37</sup> discussed the inter-relationship of the plantar aponeurosis and its effect on extension of the toes at the metatarsophalangeal joint, including the hallux. Any pathology causing an imbalance in this relationship can also affect the motion at the first metatarsophalangeal joint.

Some of the more comprehensive and well-accepted literature on this subject was published by Root, Orien, and Weed.<sup>24</sup> They stated six factors that correlated well with hallux limitus. These were: 1. hypermobility of the first ray with associated foot eversion secondary to abnormal STJ pronation, 2. first ray immobilization, 3. excessively long first metatarsal, 4. metatarsus primus elevatus, 5. degenerative joint disease, and 6. trauma. Of these factors, they felt that hypermobility of the first ray with associated eversion and abnormal STJ pronation was the most common etiology of hallux limitus.

## ADVANTAGES/INDICATIONS

The modified Watermann procedure is a shortening and plantar declinating osteotomy through the first metatarsal head and neck area (Fig. 1A). The dorsal prominence or exostosis of the first metatarsal head is usually resected (Fig. 1B). The modified Watermann procedure addresses the elevated first metatarsal and the other structures that limit first metatarsophalangeal joint range of

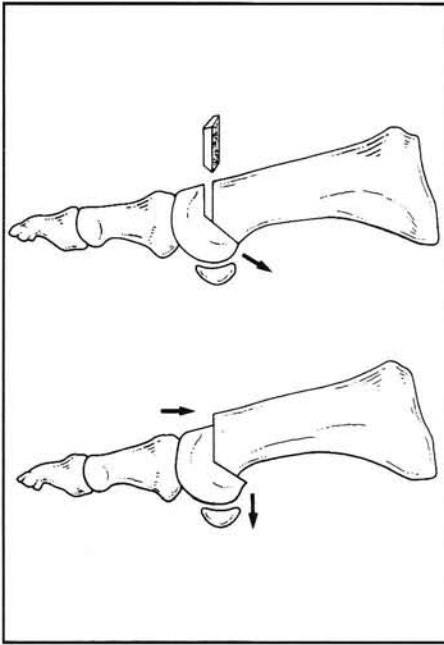


Figure 1A. The modified Watermann procedure shortens and plantar declinates the metatarsal head. An appropriate portion of bone is removed dorsally to allow the desired shortening. The angle of the plantar cut determines the ratio of shortening to plantar declination.

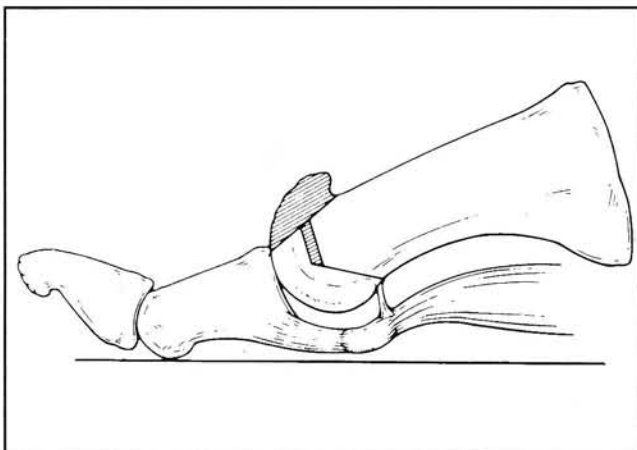


Figure 1B. Resection of the dorsal exostosis (cheilectomy) is usually required.

motion. The shortening osteotomy is created to allow a “slack in the line” to increase the range of motion. Declinating the capital fragment decreases the metatarsus primus elevatus and allows more normal weight bearing under the first metatarsal head. The osteotomy can reduce the intermetatarsal angle as well as correct for any proximal articular set angle deformity if necessary (Fig. 1C). With preservation of the first metatarsophalangeal joint, this procedure also allows for maintenance of a propulsive gait postoperatively. This becomes particularly important in young or active patients. Patients may also bear weight immediately postoperative.

## DISADVANTAGES/ CONTRAINDICATIONS

The main disadvantages of the modified Watermann bunionectomy include the technical difficulty in performing the procedure. This is especially true in the early stages of the learning curve. The inherent design makes fixation of the relatively unstable osteotomy site quite challenging. In addition, good patient compliance should be established prior to surgery because aggressive and persistent range of motion exercises are generally required for good results. The

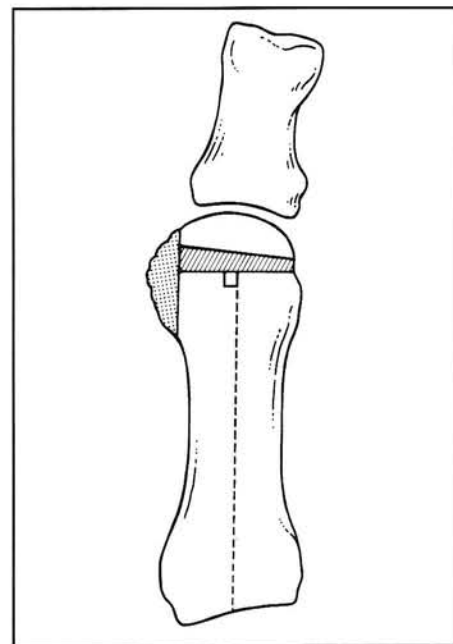


Figure 1C. The medial eminence is resected if needed. The PASA correction can be achieved via a trapezoidal dorsal wedge. The capital fragment can be transposed laterally if necessary.

decision as to which hallux limitus patient would benefit most from this procedure depends on the degree of deformity present. It is particularly problematic deciding which level of first metatarsophalangeal joint degeneration is too excessive to warrant a joint preservation procedure (severe hallux limitus or hallux rigidus).

### SURGICAL TECHNIQUE

The surgical technique used in the modified Watermann procedure has been previously published by Bernbach<sup>23</sup> in 1988, and by Feldman<sup>38</sup> in 1992. The procedure begins with a standard bunion approach with anatomical dissection in layers down to the first metatarsophalangeal joint capsule, which is adequately exposed. An attempt is made to preserve the dorsal metatarsophalangeal joint plica if possible. This is usually sacrificed when the cheilectomy is performed. An adductor

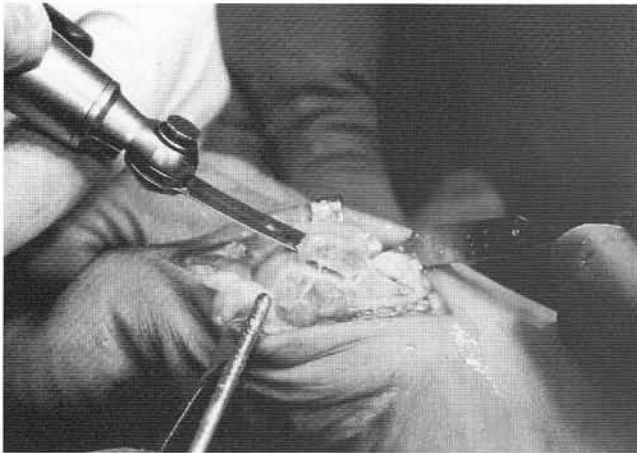


Figure 2A. A cheilectomy is performed level with the dorsal cortex.

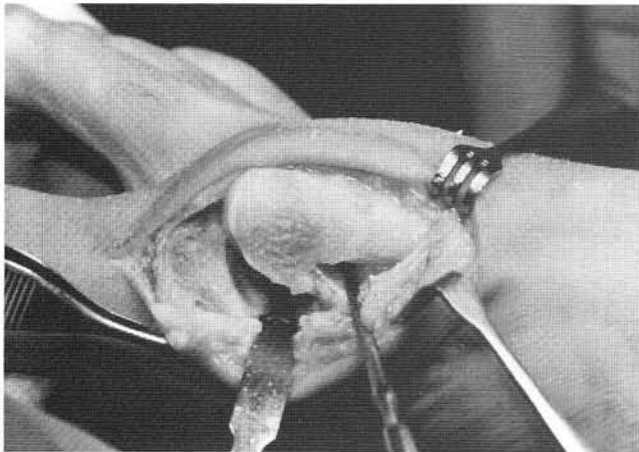


Figure 2B. After medial eminence resection, the plantar plica is identified and preserved. The plantar osteotomy cut should exit proximal to the plantar plica in the area of the freer-elevator.

hallucis tendon transfer or sesamoid release is performed if necessary. Attention is directed to the first intermetatarsal space. The hallux is then manually manipulated toward the midline of the body in order to rupture the lateral collateral ligament of the first metatarsophalangeal joint. Release of any plantar adhesions is accomplished. An "L" or "T" shaped capsulotomy is then performed at the medial aspect, and the capsule reflected to allow exposure of the first metatarsal head. A dorsal cheilectomy, which often sacrifices the dorsal plica, and resection of an appropriate amount of medial eminence are then performed (Fig. 2A).

The first osteotomy involves a through-and-through bone cut from medial to lateral in the lower two-thirds of the metatarsal head and neck. The osteotomy is made from the plantar cortex just proximal to the attachment of the plantar plica and extends dorsally and distally into the metatarsal head (Fig. 2B). The amount that the osteotomy is angled from the weight-bearing surface will determine the ratio of metatarsal shortening to plantar-declination. A standard 45 degree angle will give a 1:1 ratio. A more parallel angle will give greater shortening relative to plantar transposition, while a more vertical angle will give greater plantar transposition relative to metatarsal shortening. The saw blade is then detached from the power equipment and left in the plantar osteotomy to assist in accurate placement of the dorsal osteotomies (Fig. 2C).

The next step involves the creation of two osteotomies in the dorsal one-third of the metatarsal head maintaining a perpendicular

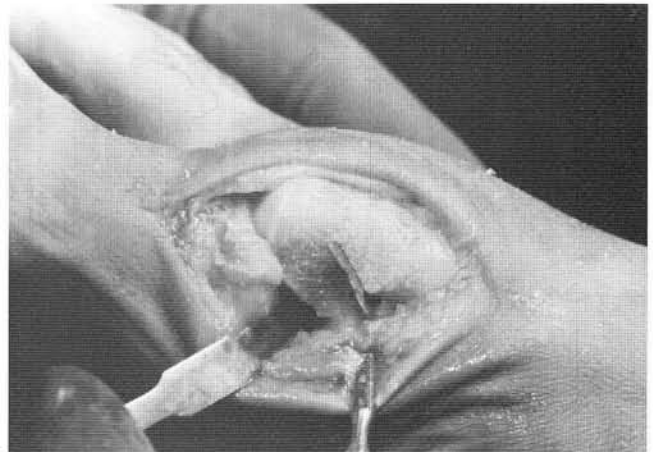


Figure 2C. The plantar osteotomy is performed, and the saw blade left in place for facilitation of the dorsal cuts.

relationship to the weight-bearing surface. The distal osteotomy is performed first, and can be made parallel to the proximal articular set angle (PASA) of the first metatarsal head in order to correct the angle to zero degrees. The inferior aspect of the osteotomy should intersect the distal aspect of the plantar osteotomy utilizing the plantar saw blade as a guide. The proximal osteotomy is performed next, and can be made perpendicular to the long axis of the first metatarsal. This creates a dorsal trapezoidal-shaped wedge of bone with a wider base medial. If no PASA correction is desired, one can also perform the distal osteotomy perpendicular to the longitudinal axis of the first metatarsal creating a dorsal rectangular-shaped wedge of bone (Figs. 2D, 2E).

The created wedge of bone is removed, and the capital fragment is then plantarly declinated, and the metatarsal shortened (Figs. 3A, 3B). Lateral transposition of the capital fragment can also be

performed at this time if a relative reduction of the intermetatarsal angle is desired. Impaction is then carried out, and the osteotomy site is inspected to insure good apposition.

Fixation of the osteotomy site is then accomplished with either a 0.062" threaded K-wire or a 4.0 mm AO cancellous screw (Figs. 4A, 4B). Orientation of the fixation is usually proximal-dorsal to distal-plantar, insuring the fixation is not exposed at the plantar articulating surface. The capital fragment is then inspected for stability and, if necessary, a second threaded K-wire is placed. The K-wire is cut flush with the metatarsal cortex dorsally and adequately countersunk as necessary to prevent dorsal impingement. The practice of penetrating the plantar articular cartilage and then withdrawing until the distal aspect of the K-wire is buried subchondrally should be avoided in order to maintain the integrity of the cartilage as a resisting force in helping to prevent K-wire migration

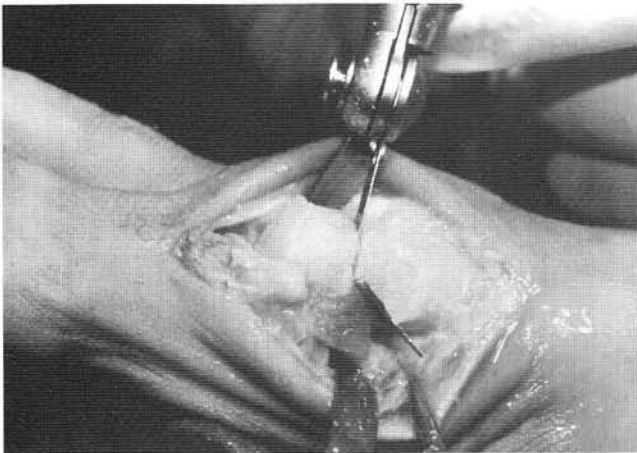


Figure 2D. The distal dorsal osteotomy is undertaken from dorsal to plantar.

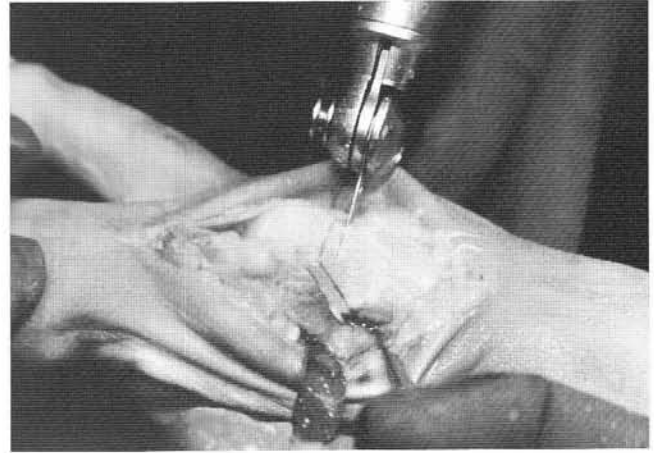


Figure 2E. The second dorsal osteotomy is performed proximal to obtain the desired shortening of the first metatarsal.

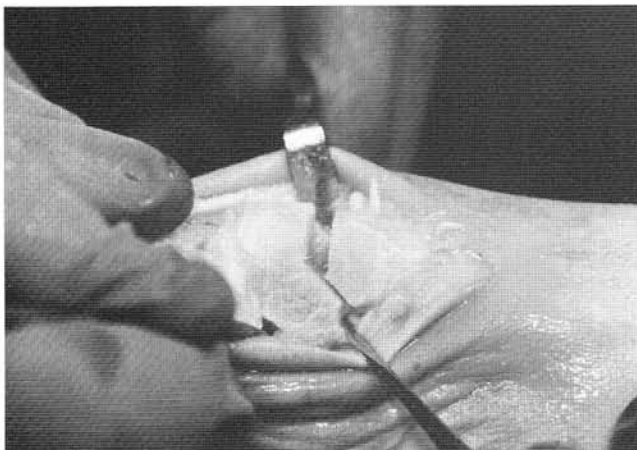

Figure 3A. The dorsal section of bone is removed.

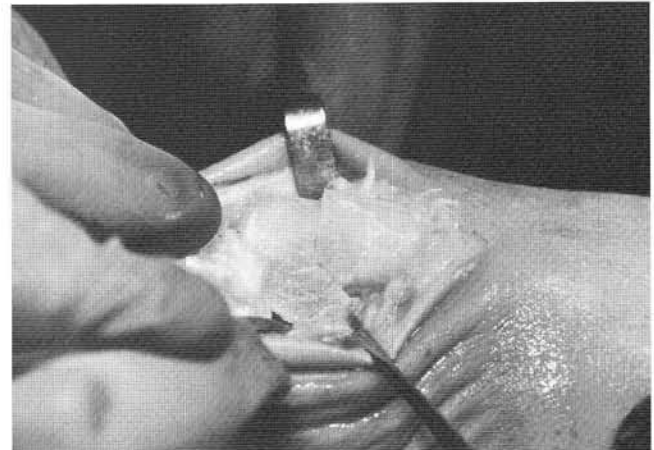


Figure 3B. The osteotomy is closed, shortening and plantar-declination the capital fragment.

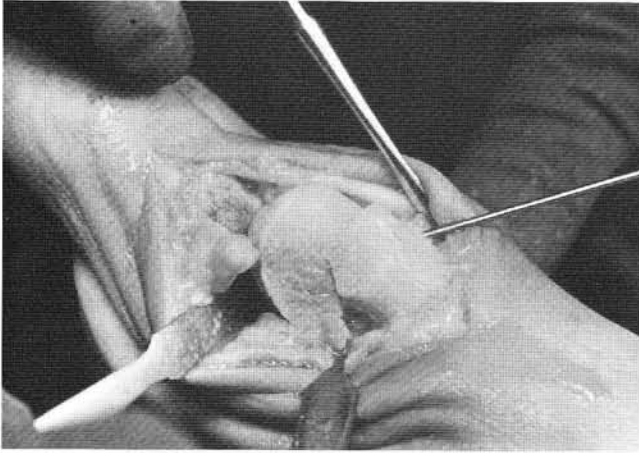


Figure 4A. Fixation can be accomplished with a threaded 0.062" K-wire from proximal-dorsal to distal-proximal.

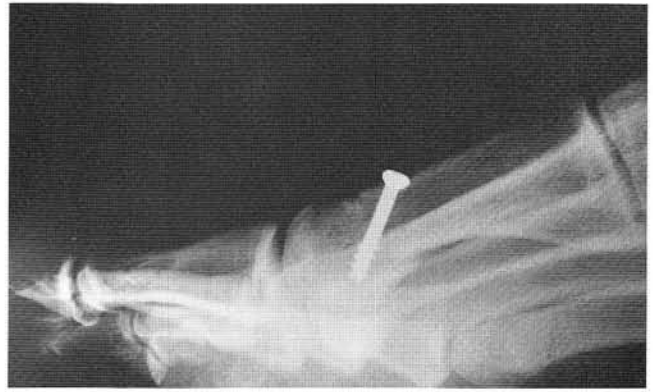

Figure 4B. Fixation can also be accomplished with a cancellous screw.

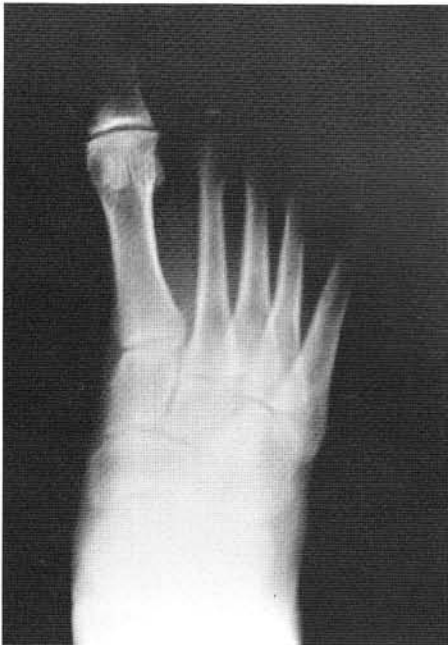

Figure 5A. Preoperative DP weight-bearing radiograph with hallux limitus.

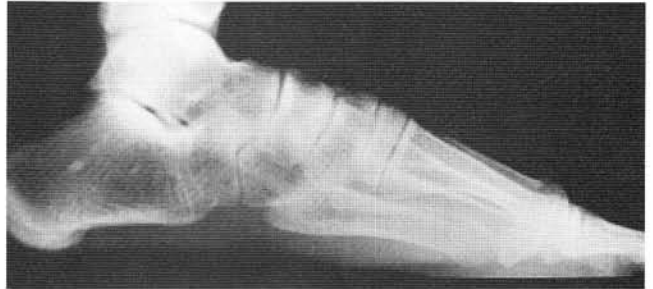

Figure 5B. Preoperative lateral weight-bearing radiograph with hallux limitus and metatarsus primus elevatus.

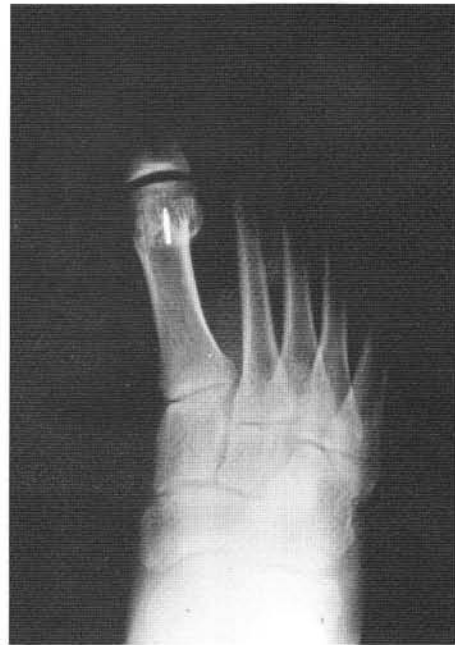

Figure 5C. Postoperative DP weight-bearing radiograph with 0.062" threaded K-wire.

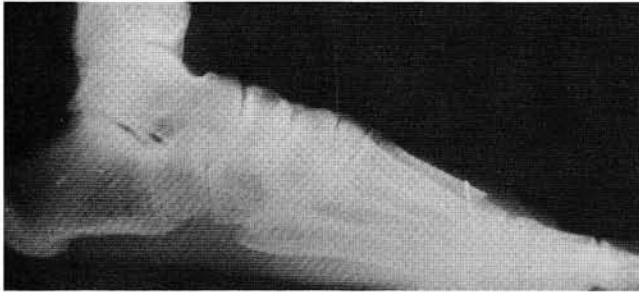


Figure 5D. Postoperative lateral weight-bearing radiograph with 0.062 threaded K-wire.

plantarily. The use of absorbable pin fixation is not recommended due to its inability to provide adequate stabilization (Figs. 5A-D).

Standard layered closure of the soft tissues is then achieved with adjunctive capsulorrhaphy done as determined intra-operatively by the surgeon. The surgical site is then dressed in the standard manner.

### POSTOPERATIVE MANAGEMENT

The patient is discharged in a rigid surgical shoe, and allowed to bear weight as tolerated. Passive range of motion exercises are begun no later than postoperative day three, and then gradually and progressively increased until full motion is achieved. One may also utilize a continuous passive motion machine with the first metatarsophalangeal joint. Orthotic control should be considered as part of the postoperative management once healing has occurred. Potential complications are similar to those experienced with other first metatarsal head osteotomies.

### METHODS

A review of modified Watermann procedures performed by authors DG and RG between 1989 and 1994, were undertaken, totaling 33 patients. Subjective questionnaires were sent to all patients with 21 responses returned, (total of 26 feet). Objective evaluations were performed on 15 patients (8 females, 7 males) with an average age of 50 years, for a total number of 20 feet. Five patients had bilateral hallux limitus deformities. The follow-up time averaged 22.4 months, with a range of 2 to 65 months.

### DISCUSSION

Hallux limitus deformity is a challenging entity for today's surgeon. This is especially true recently as implant arthroplasties are becoming less favorable due to long-term complications developing secondary to the prosthetic material. Joint destructive procedures have shown favorable results for patients not requiring full postoperative propulsion. However, the patient desiring a propulsive gait postoperatively has been a true challenge with regard to surgical correction while attempting to preserve the integrity of the joint. There have been numerous joint preservation procedures attempted that fit in this latter category, with mixed results.

The modified Watermann procedure has been advocated since 1988 as one of the procedures of choice for patients with hallux limitus.<sup>23</sup> Phillips and McGlamry<sup>39</sup> published a case study of a patient having undergone a Watermann-Green procedure for treatment of hallux limitus with good results reported. The authors' current study further supports the role of the modified Watermann procedure in the treatment of hallux limitus.

The subjective results showed a decrease in the patient's mean level of pain. The largest difference was an increase in the patient's mean overall satisfaction when comparing preoperative and postoperative assessments. Almost universally, the patients said they would highly recommend the surgery to patients with similar symptoms. Patients also experienced a mean increase in their level of activity, an improved appearance of the foot, less limitation in the style of shoes that could be tolerated, and an increase in the amount of motion at the big toe joint. It is interesting to note that patients achieved a more substantial improvement in the level of pain rather than in the amount of first metatarsophalangeal joint range of motion.

In contrast, objective biomechanical results revealed a non-statistically significant mean increase in first metatarsophalangeal joint dorsiflexion range of motion. A significant decrease in the mean level of pain with first metatarsophalangeal joint range of motion was revealed after surgery. Crepitus with first metatarsophalangeal joint range of motion decreased. Although patients felt a significant increase in range of motion, objectively only an average increase of approximately six degrees was measured. There was a significant decrease in the

level of pain with range of motion which may have contributed to the sensation of an increased range of motion.

The mean metatarsal protrusion distance was decreased postoperatively as was expected. No change was noted in the intermetatarsal angle. Negligible change was measured between the base of the proximal phalanx and the head of the metatarsal. There was a small reduction involving the hallux abductus angle. The mean Seiberg sagittal plane displacement (the amount of elevation or declination of the first metatarsal with respect to the second metatarsal) was recorded to be less than one millimeter of declination.<sup>40</sup> One needs to appreciate that due to the declination of the metatarsal, any capital fragment shortening will concomitantly elevate it as well. Therefore, the minimal plantar transposition realized postoperatively actually translates into a significant amount of plantar-declination achieved overall.

The modified Watermann procedure has been presented. Its effectiveness in the treatment of patients with hallux limitus was evaluated, and found to be consistent with previous preliminary reports stating good results. The authors believe that the modified Watermann procedure is effective in treating patients with moderate to significant hallux limitus deformity.

## REFERENCES

- Gerbert J: *Textbook of Bunion Surgery* Mt. Kisco, NY: Futura; 1991: 453-492.
- Vanore JV, Corey SV: In Marcinko D, ed., *Comprehensive Textbook of Hallux Valgus* St. Louis, MO: Mosby; 1992: 209-241.
- Drago JL, Oloff L, Jacobs AM: A comprehensive review of hallux limitus. *J Foot Surg* 23(3):213-220, 1984.
- Gould N: Hallux rigidus: Cheilectomy or implant? *Foot Ankle* 1(6):315-320, 1981.
- Mann RA, Clanton TO: Hallux rigidus: Treatment by cheilectomy. *J Bone Joint Surg* 70A(3):400-406, 1988.
- Geldwert JJ, Rock GD, McGrath MP, Mancuso JE: Cheilectomy: Still a useful technique for Grade I and Grade II hallux limitus/rigidus. *J Foot Surg* 31(2):154-159, 1992.
- Hatrup SJ, Johnson KA: Subjective results of hallux rigidus following treatment with cheilectomy. *Clin Ortho Res* 226: 182-191, 1988.
- Feldman RS, Hutter J, Lapow L, Pour B: Cheilectomy and hallux rigidus. *J Foot Surg* 22(2):170-174, 1983.
- DeLauro TM, Positano RG: Surgical management of hallux limitus and rigidus in the young patient. *Clin Pod Med Surg* 6(1):83-92, 1989.
- Mann RA: Hallux rigidus. *Instructional Course Lectures* 39:15-21, 1990.
- Mann RA, Coughlin MJ, DuVries HL: Hallux rigidus-A review of the literature and a method of treatment. *Clin Ortho Rel Res* 142:57-63, 1979.
- Quinn M, Wolf K, Hensley J, Kruljac S: Keller arthroplasty with autogenous bone graft in the treatment of hallux limitus *J Foot Surg* 29(3):284-291, 1990.
- Kessel I, Bonney G: Hallux rigidus in the adolescent *J Bone Joint Surg* 40B: 668, 1958.
- Cavolo DJ, Cavallaro DC, Arrington LE: The Watermann osteotomy for hallux limitus. *J Am Podiatry Assoc* 69(1):52-57, 1979.
- Youngswick F: Modification of the Austin bunionectomy for treatment of metatarsus primus elevatus associated with hallux limitus. *J Foot Surg* 21:114, 1982.
- McKeever DC: Arthrodesis of the first metatarsophalangeal joint for hallux valgus, hallux rigidus and metatarsus primus varus. *J Bone Joint Surg* 34A: 129-134, 1952.
- Fitzgerald JAW: A review of long-term results of arthrodesis of the first metatarsophalangeal joint. *J Bone Joint Surg* 51B(3): 488-493, 1969.
- O'Doherty DP, Lowrie IG, Magnussen PA, Gregg PJ: The management of the painful first metatarsophalangeal joint in the older patient *J Bone Joint Surg* 72B (5):839-842, 1990.
- Blair MP, Brown LA: Hallux limitus/rigidus deformity: A new great toe implant. *J Foot Ankle Surg* 32(3):257-262, 1993.
- Kashuk KB: Hallux rigidus, hallux limitus and other functionally limiting disorders of the great toe joint implant. *J Foot Ankle Surg* 14(2):45-51, 1975.
- Keller WL: The surgical treatment of bunions and hallux valgus. *N Y State J Med* Oct 15:741-742, 1905.
- Bernbach M, McGlamry ED: Hallux limitus. In McGlamry ED, ed., *Reconstructive Surgery of the Foot and Leg, Update '87* Tucker, GA: Doctors Hospital Podiatric Education and Research Institute; 1987: 81-85.
- Bernbach M: Hallux limitus: Follow-up study. In McGlamry ED, ed., *Reconstructive Surgery of the Foot and Leg, Update '88* Tucker, GA: Doctors Hospital Podiatric Education and Research Institute; 1988: 109-111.
- Root ML, Orien WP, Weed JH: *Normal and Abnormal Function of the Foot* Los Angeles, CA: Clinical Biomechanics Corp; 1977.
- Davis-Colley N: Contraction of the metatarsophalangeal joint of the great toe (hallux flexus). *Br Med J* 1:728, 1887.
- Cochrane WA: An operation for hallux rigidus. *Br Med J* 1: 1095-1096, 1927.
- Durrant MN, Siepert KK: Role of soft tissue structures as an etiology of hallux limitus. *J Am Podiatr Med Assoc* 83(4):173-180, 1993.
- Nilsson H: Hallux rigidus and its treatment. *Acta Orthop Scand* 1:295-303, 1930.
- Lambrinudi C: Metatarsus Primus Elevatus. *Proc R Soc Med* 31:1273, 1938.
- Lapidus PW: Dorsal bunion: Its mechanics and operative correction. *J Bone Joint Surg* 22(3):627-637, 1940.
- Bingold AC, Collins DH: Hallux rigidus. *J Bone Joint Surg* 32B(2):214-222, 1950.
- Dananberg HJ: Functional hallux limitus and its relationship to gait efficiency. *J Am Podiatr Med Assoc* 76(11):648-652, 1986.
- Dananberg HJ: Gait style as an etiology to chronic postural pain. Part I. Functional hallux limitus. *J Am Podiatr Med Assoc* 83(8):433-441, 1993.
- Jack EA: The Etiology of hallux rigidus. *Br J Surg* 27(107): 492-497, 1940.
- Goodfellow J: Etiology of hallux rigidus. *Proc Roy Soc Med* 59:821-824, 1966.
- McMaster MJ: The pathogenesis of hallux rigidus. *J Bone Joint Surg* 60B(1):82-87, 1978.
- Hicks JH: The mechanics of the foot II. The plantar aponeurosis and the arch. *J Anat* 88:25, 1954.
- Feldman KA: The Green-Watermann procedure: Geometric analysis and preoperative radiographic template technique. *J Foot Surg* 31(2):182-185, 1992.
- Phillips AJ, McGlamry ED: Hallux limitus: Technique. In McGlamry ED, ed., *Reconstructive Surgery of the Foot and Leg, Update '89* Tucker, GA: Doctors Hospital Podiatric Education and Research Institute; 1989: 34-41.
- Seiberg M, Green R, Green D: Epiphysiodesis in juvenile hallux abducto valgus: A preliminary retrospective study. *J Am Podiatr Med Assoc* 84(5):225-236, 1994.

## ADDITIONAL REFERENCES

- Beiser IH, Kanat IO: Subchondral bone drilling: A treatment for cartilage defects. *J Foot Surg* 29:595-601, 1990.
- Hamerman D: The Biology of osteoarthritis. *N Engl J Med* 320(20):1322-1330, 1989.
- Karasick D, Wapner KL: Hallux rigidus deformity: Radiologic assessment. *Am J Rad* 157:1029-1033, 1991.
- Mahan KT: Repair of iatrogenic hallux limitus. In DiNapoli DR, ed., *Reconstructive Surgery of the Foot and Leg, Update '90* Tucker, GA: Podiatry Institute Publishing; 1990:144-148.
- Marcinko DE, Dollard MD: Physical and mechanical properties of joints (The pathomechanics of articular cartilage degeneration). *J Foot Surg* 25(1):3-12, 1986.
- Meyer JO, Nishon LR, Weiss L, Docks G: Metatarsus Primus elevatus and the etiology of hallux rigidus. *J Foot Surg* 26(3):237-241, 1987.
- Norman GR, Streiner DL: *Biostatistics: The Bare Essentials* St Louis, MO: Mosby Year Book; 1994.
- Radin EL, Paul IL: A consolidated concept of joint lubrication. *J Bone Joint Surg* 54A(3):607-615, 1972.
- Rzonca E, Levitz S, Lue B: Hallux equinus. The stages of hallux limitus and hallux rigidus. *J Am Podiatr Assoc* 74(8):390-392, 1984.
- Smith TF, Malay DS, Ruch JA: Hallux limitus and rigidus. In McGlamry ED, ed., *Comprehensive Textbook of Foot Surgery* Baltimore, MD: Williams & Wilkins; 1987: 238-251.
- Stuck RM, Moore JW, Patwardhan AG, Sartori M: Forces under the hallux rigidus foot with surgical and orthotic intervention. *J Am Podiatr Med Assoc* 78(9):465-468, 1988.
- Sussman RE, Piccora R: The metatarsal sesamoid articulation and the first metatarsophalangeal joint function. *J Am Podiatr Med Assoc* 75(6):327-330, 1985.
- Thomas AP, Dwyer NJP: Osteochondral defects of the first metatarsal head in adolescence: A stage in the development of hallux rigidus. *J Ped Orthop* 9:236-239, 1989.
- Vancil D, Mozena J: Osteochondritis dissecans and the first metatarsophalangeal joint. *J Am Pod Med Assoc* 76(11):645-647, 1986.
- Watermann H: Die arthritis deformans des Grosszehengrundgelenkes als Selbständiges Krankheitsbild. *Z Chir Orthop Chir* 48:346, 1927.