

# REFLECTIONS ON THE REFLEXION™ FIRST METATARSOPHALANGEAL JOINT IMPLANT

*Stephen J. Miller, D.P.M.*

Metallic implants for the great toe joint have made the full circle from the Seeburger single stem endoprosthesis through the recently popular silicone polymers to the current two component systems. These have been designed and modelled after the successful knee and hip joint replacements. Pyrolytic carbon and porous ceramic implants have also been used.<sup>1</sup>

The silastic implants had many advantages including ease of installation, relatively good function (in spite of their constrained hinge design relying on intramedullary stem positioning), and fairly consistent pain relief acting essentially as a spacer.<sup>2-4</sup> Many reports on their success were positive.<sup>5-16</sup> Unfortunately, the silicone polymer could not withstand the rigors of shear and torsion which resulted in its sharding into small & microscopic fragments. These silicone particles then caused an inflammatory reactive synovitis that resulted in osteoproliferation, local osteolysis, and subchondral bone cyst formation.<sup>17-20</sup> Obviously, there are important considerations for great toe joint implant design.<sup>21-23</sup>

There are, as of this date, five different two-component joint implant systems for the first metatarsophalangeal joints (MPJ). They have evolved from 1989 to the present (Table 1). Although each system has specific design features, all of them are made of similar biomaterials. The metatarsal component is formed of a cobalt-chromium alloy, selected for its excellent wear properties. The phalangeal stem with support cup is composed of a titanium alloy and uses an ultra-high molecular weight polyethylene (UHMWPE) material as the phalangeal base to articulate with the metatarsal head.

A term used to describe the functional ability of the two component joint replacement system is "non-constrained," indicating that the two parts can articulate, yet function independently of one another. The components are also known as "endoprostheses" since their stems fit into the intramedullary canals.

## THE TWO-COMPONENT REFLEXION™ IMPLANT

### The Implant

A brief review describing the five different two-component first MPJ implants was presented by Gerbert and Chang in 1995, although they discussed clinical experience with only two systems: the Bio-Action and the Acumed.<sup>24</sup> To date, there has been no publication of clinical experience with the ReFlexion™ First Metatarsophalangeal Joint Reconstruction System (Osteomed, Inc., Irving, Texas).

Each ReFlexion™ total joint replacement system has four components (Figs. 1A, 1B). The intramedullary stems for both the metatarsal and proximal phalanx are constructed of titanium alloy (Ti-6/4) with roughened surfaces to improve tissue adherence. The metatarsal component has a fluted

**Table 1**

### TWO-COMPONENT FIRST METATARSOPHALANGEAL JOINT IMPLANTS

IMPLANT	COMPANY	YEAR
Biomet Total Toe System (Koenig)	Biomet, Inc	1989
Bio-Action Great Toe Implant (Zang)	Microaire	1991
Acumed Great Toe System	Acumed, Inc	1992
Kinetik Great toe Implant System	Kinetikos Medical, Inc. (KMI)	1994
ReFlexion 1st MPJ Implant System	Osteomed Corp.	1994

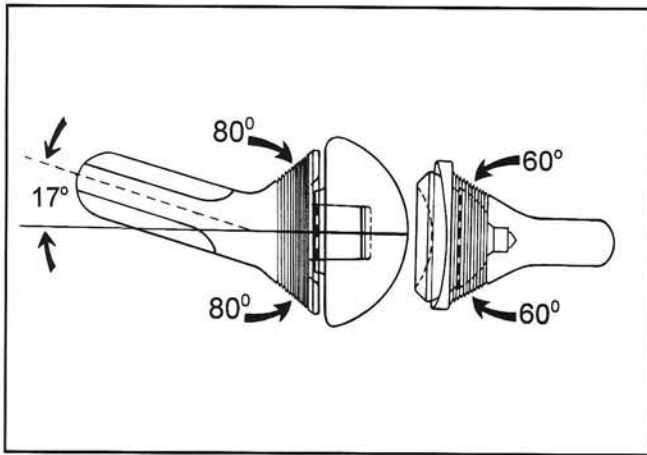


Figure 1A. Lateral view of the four component modular heads of the ReFlexion™ First Metatarsophalangeal Joint Reconstruction System.

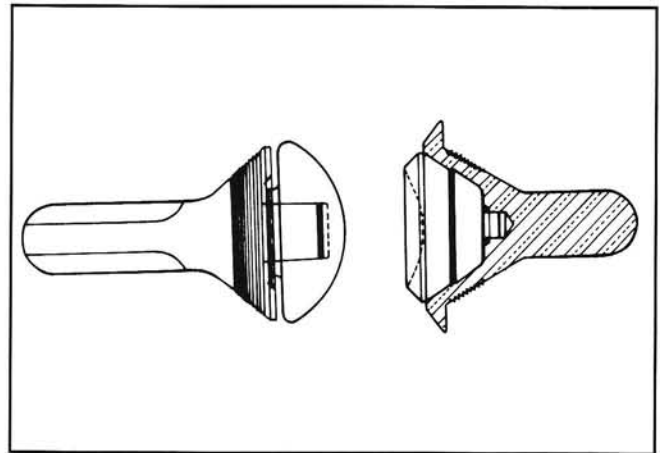


Figure 1B. Dorsal view.

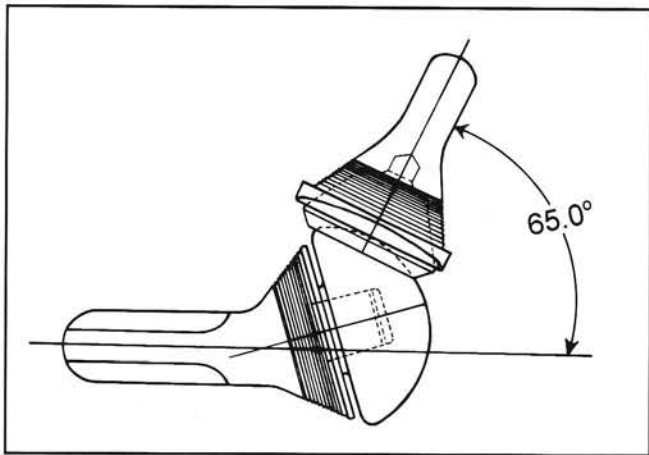


Figure 2. The articular congruency allows for up to 65 degrees of dorsiflexory motion.

stem so that tissue ingrowth will prevent rotation, and an 80 degree metaphyseal cone with circumferential grooves to more evenly transmit the load between the stem and the articulation. There is a 17 degree stem-cone angle to accommodate for metatarsal declination. The second part of the metatarsal component is a modular cobalt-chromium (CoCr) head with a large spherical articulating surface. It connects to the titanium stem using a squared peg-and-hole configuration.

The titanium phalangeal component has a shorter cylindrical stem with flats, again to prevent rotation. It has a 60 degree metatarsal cone, also with circumferential grooves for more even load transmission. There is no angulation between the stem and the metaphyseal cone.

To complete the ReFlexion™ system there is a fourth component which is the concave module that articulates in a congruent fashion with the spherical

metatarsal head prosthesis. It is composed of thick ultra-high molecular weight polyethylene (UHMWPE) and fits into the titanium cone stem, again by means of a squared peg-in-hole configuration.

In spite of its precise congruence, the concave base of the proximal phalanx articulates with only about one-third of the surface of the metatarsal head at any one time. It is this large convex sphere that allows not only for the generous sagittal plane motion (Fig. 2), but will accommodate the proximal articular set angle as well for directing the hallux in the transverse plane (Fig. 3).

The ingenuity of this four-component modular system is that each of the metatarsal and phalangeal articulating modular components comes in three interchangeable sizes. This is made possible by incorporating the same exact arc for a congruent articulation between any size of the components. Thus, if the patient has a small proximal phalanx, but a proportionately larger corresponding metatarsal, the articulation can be made without compromise by mixing the sizes of the components.

### Advantages

There are several advantages of the ReFlexion™ implant system besides interchangeable sizes of the biocompatible modular articulating components. If installed with appropriate angulation, the result is an inherent geometric stability of the implant in the bones. Roughened titanium surfaces allow for osteo-integration of the endoprosthesis stems, which also have an anti-rotational locking configuration. The instruments are designed to provide precision fit and are assisted by cannulated guides.

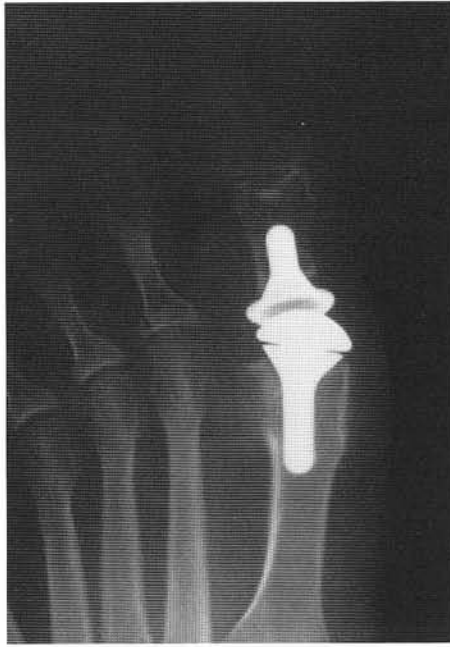

Figure 3. Congruent PASA adaption is accommodated by the articular design.

Articulating surfaces are congruent, allowing for generous dorsiflexion while accommodating any transverse plane PASA that may be necessary. An optimum load transfer is accomplished through the cone-to-bone interface design. Digital function is maintained through the preservation of the load-bearing plantar surface of the first metatarsal head, as well as the attachments of the flexor hallucis brevis tendon to the base of the proximal phalanx. Sesamoid function is thus preserved.

### Disadvantages

This is a challenging implant system to install, requiring specialized instrumentation (Fig. 4). The guide pin alignment device is somewhat awkward (Fig. 5), and does not always allow accuracy for the placement of the crucial first metatarsal guide pin. While the concept of cannulation lends itself to precision placement of the implant components, one frustration is that the guide pins tend to pull out with the cannulated cylindrical intramedullary reamers (drills). Often the pins become quite loose in the soft intramedullary canals, compromising their function (Fig. 6).

The cone reamer guides seem to work quite well in concert with the cannulated cone reamers to achieve the 17 degree angle between the stem and articulating surface of the metatarsal

component (Fig. 7). However, they have to be driven deeper into the intramedullary canals for more cone penetration. Then they have to be retrieved and replaced by the metatarsal stem trials. For some reason, the cone reamer guides are longer and penetrate much further down the metatarsal intramedullary canals than is necessary for fitting the metatarsal stem prostheses. Also, the cone reamer guides can be difficult to push into the intramedullary canals, and even more difficult to remove.

All the reamers have a shaft diameter of one-quarter inch which requires specific instrumentation, not normally a part of micro-power equipment sets. Thus, it is necessary to have available a larger power drill that can accommodate a Jacob's chuck large enough to accommodate the 1/4 inch reamer shafts. One alternative that the author has found quite acceptable is the use of a hand drill with a Jacob's chuck to accomplish the same goal. It is also less traumatic on the bone.

Even though sesamoid function can be preserved, there are frequent instances where degeneration of their articular surfaces is so severe that doing so would leave a painful problem for the patient. When the sesamoids are necessarily removed, the crista ridge can be uncomfortable to walk on (Figs. 8A, 8B).

Restoration of first metatarsophalangeal joint motion is often not achieved, even with sesamoid resection, although the patient is almost always rewarded with resolution of joint pain (Fig. 9). If the metatarsal component is installed too far dorsally, there is a restriction of motion as the articulation is locked or jammed (Figs. 10A 10B). This may also be the result of two problems. First, the 17 degree stem-cone angle is often not appropriate for the patho-anatomy involved. The first metatarsal elevatus that often accompanies hallux limitus would leave the stem-cone angle oriented too far dorsally and result in jamming of the articular component (Fig. 11).

A second problem, also resulting in locking, is that the metatarsal head component is too large, even its smallest size. Without removing sufficient bone the articulation will jam. The resulting protrusion through the skin can be irritating to the patient, and it is often impossible for the capsule to be sewn over the implant (Fig. 12).

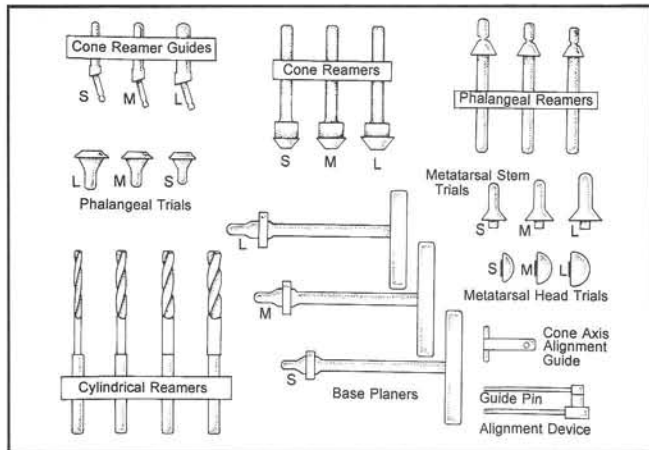


Figure 4. Specialized instruments for implanting the Reflexion™ system.

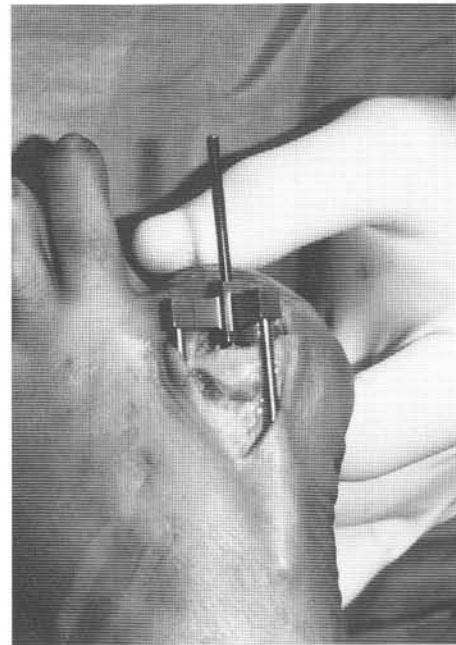


Figure 5. The guide pin alignment device arms require extensive dissection, and ride over the metaphysis.

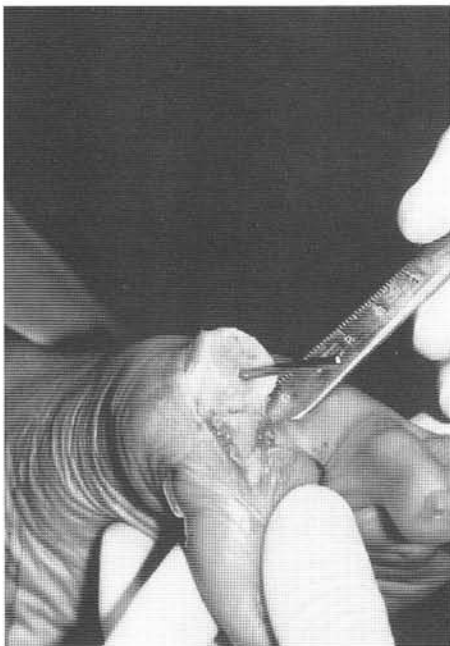

Figure 6. Intramedullary pin placement is a little below center, but lacks stability in the soft center.

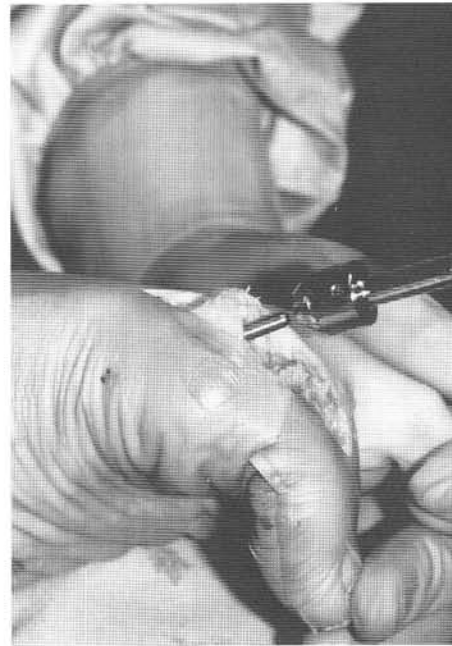

Figure 7. The cone reamer for the metatarsal must be driven very deep.

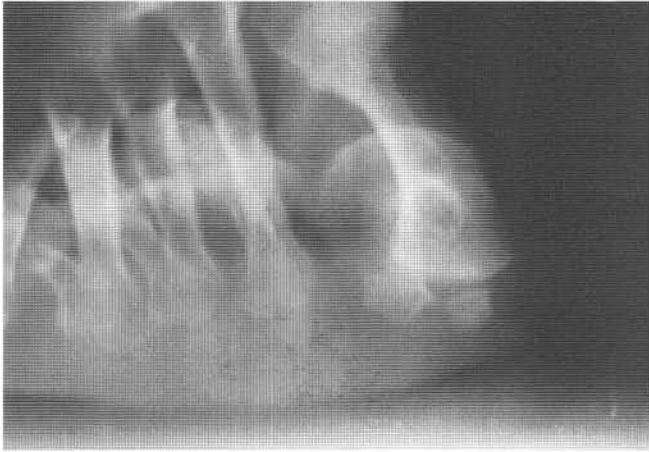


Figure 8A. Preoperative x-ray before sesamoid removal, using the ReFlexion™ implant.

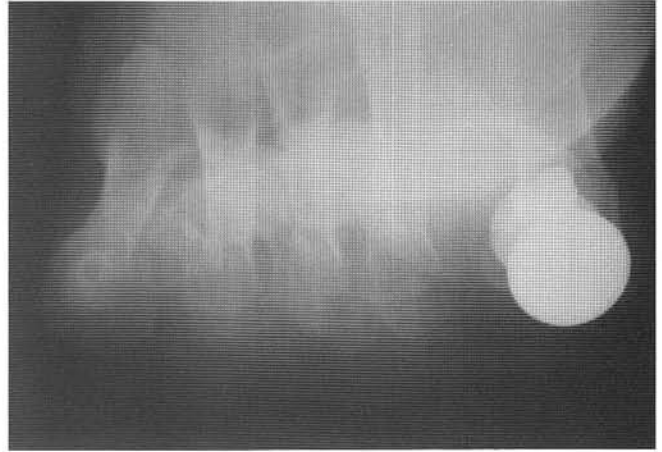


Figure 8B. Postoperative x-ray after sesamoid removal using the ReFlexion™ implant.

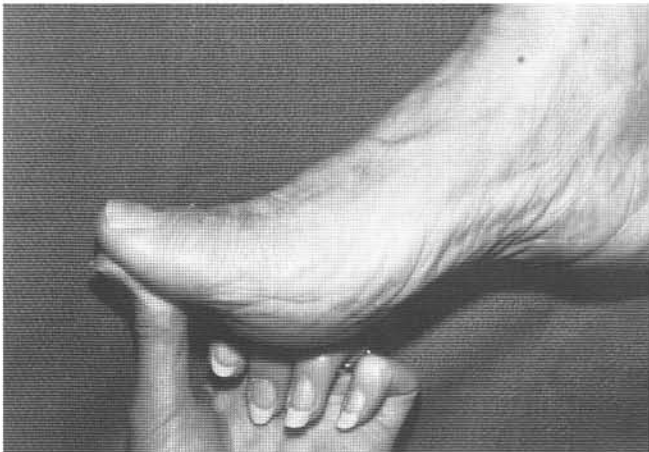


Figure 9. Limited joint motion is demonstrated 8 months after implantation.

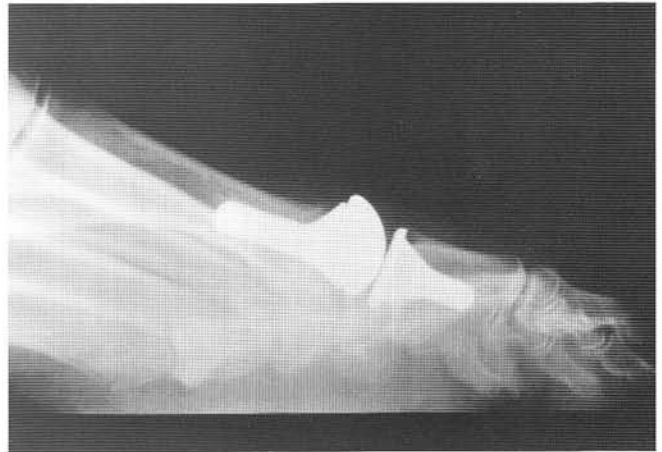

Figure 10A. Laterally x-ray demonstrating the dorsally set position of the implant resulting in restriction of motion.

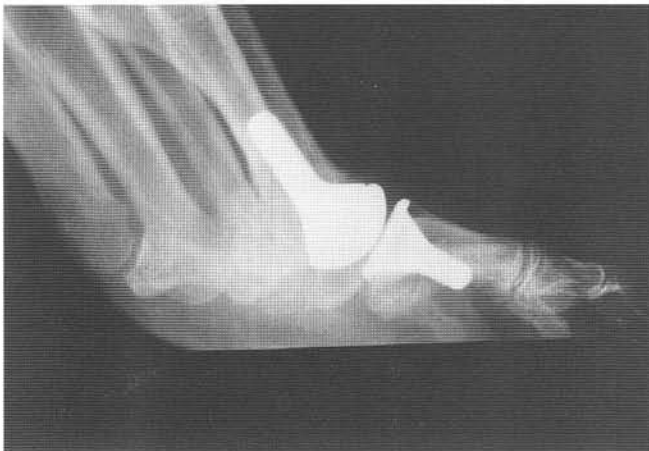

Figure 10B. Stress dorsiflexion view of the same.

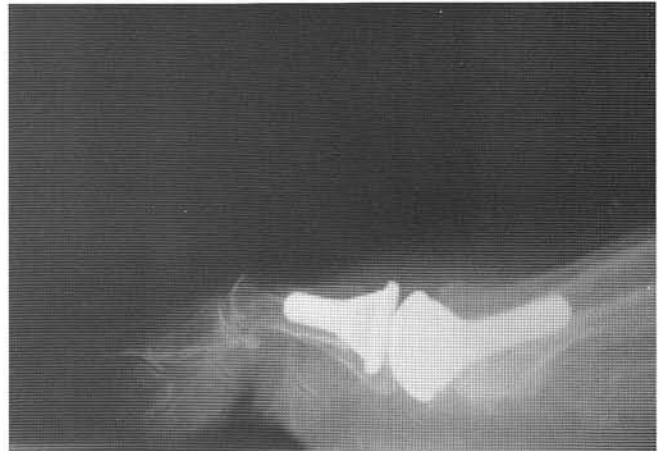

Figure 11. Lateral x-ray demonstrating how the cone angle directs the articular surface too far dorsally.

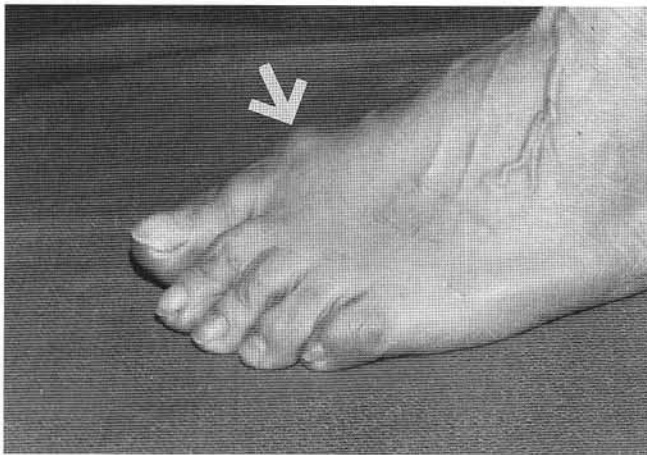


Figure 12. Protrusion of the metatarsal head component under the skin.

Another unresolved problem with this implant system is the restriction of dorsiflexion by contracture, or restriction of the flexor hallucis brevis muscle and/or the plantar fascia (Fig. 13). This is a frustrating postoperative situation, when all other aspects of the surgical implantation have been executed accurately. Releasing plantar capsular adhesions with a McGlamry elevator can be helpful, but unfortunately only partially. Removal of more bone to obtain relative length increase in these plantar structures is difficult. If it is removed from the metatarsal, there is less weight-bearing. If it is removed from the base of the proximal phalanx, there is risk of loss of the attachment for the flexor hallucis brevis tendon. The cone reamers can deepen the setting for the implant components to create space, but the cortical shoulders thin substantially once the bone is reamed away past the metatarsophyseal flare. Even removal of the sesamoid bones, when necessary, fails to provide substantial dorsiflexion. Most frustrating of all is to see the achievement of a good range of motion when the implant is in place at the surgery, only to lose it as tissue healing advances.

### Implantation Technique

The technical aspects for implanting the ReFlexion™ endoprosthesis system can be divided into six stages: 1) soft tissue dissection, 2) removal of the joint surfaces, 3) attention to the sesamoid apparatus, 4) preparation of the metatarsal, 5) preparation of the phalanx, and 6) insertion of the implant components. With some minor modifications, the protocol recommended by the manufacturer is quite

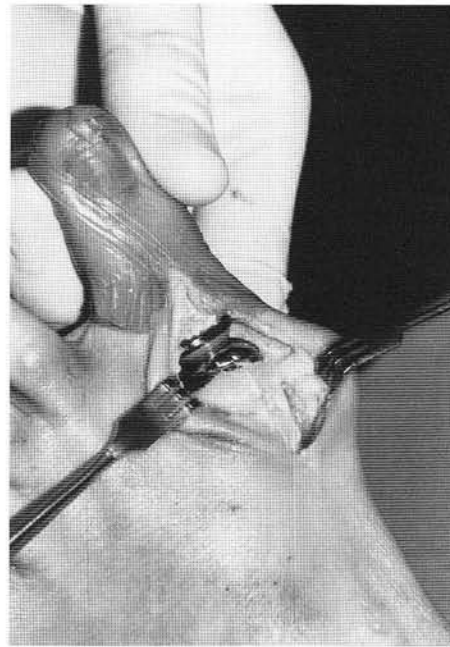


Figure 13. The implant is in place. Soft tissue ingrowth can restrict motion.

appropriate to successfully place the implant components. Each step must be accomplished as directed, and the technique is technically demanding.

Insertion and alignment of the metatarsal guide pin is the most critical part of the procedure, as it determines the position and angle of the metatarsal implant component stem. Proper alignment and function of all other components are dependent upon the position of this modular unit.

### CONCLUSION

The ReFlexion™ First Metatarsophalangeal Joint Implant System is a complex four-component joint replacement that requires serious planning, use of guides and templates, and meticulous surgical technique. Although it uses complex instrumentation, it is necessary to achieve a predictable fit.

Experience thus far is limited to discussing the technical aspects of implanting the four-component prosthetic system and reporting observations during the immediate postoperative period. Pain relief seems to be the primary benefit; limited motion is a disappointment. With attention to some of the problems discussed in this paper, it is a promising replacement for a troublesome joint. The real proof, however, will be found in its success over the longer term.

## REFERENCES

1. Dockery GL: First MPJ implants: Silicone versus other materials. *Br J Podiatr Med Surg* 5:1-5, 1993.
2. Lauf E, McLaughlin B, McLaughlin E: Swanson great toe flexible hinge endoprosthesis. Design, flexibility and function. *J Am Podiatr Med Assoc* 75:393-400, 1985.
3. Swanson AB, Biddulph SI, Hager CG: A Silicone rubber implant to supplement the Keller toe arthroplasty. *NY Univ Inter-Clin Inform Bull* 10:7, 1971.
4. Swanson A, Neester W, Swanson G, et al.: Durability of silicone implants: an in vivo study. *Orthop Clin North Am* 4:1097, 1973.
5. Wegner R, Whalley R: Total replacement of the first metatarsophalangeal joint. *J Bone Joint Surg* 60B:88, 1978.
6. Gundmundsson G, Robertsson K: Silastic arthroplasty of the first metatarsophalangeal joint. *Orthop Scand* 51: 575, 1981.
7. Cracchiolo A, Swanson A, Swanson G: The arthritic great toe metatarsophalangeal joint: a review of flexible silicone implant arthroplasty from two medical centers. *Clin Orthop* 157:64, 1981.
8. Teich L, Frankel J, Lipsman S: Silicone hinge replacement arthroplasty. *J Am Podiatry Assoc* 71:266, 1981.
9. Borovoy M, Gray W, Rinker A: Total replacement of the first metatarsophalangeal joint. *J Foot Surg* 22:159, 1983.
10. Miller R, Rattan N, Sorto L: The geriatric bunion: correction of metatarsus primus varus and hallux valgus with the Swanson total joint implant. *J Foot Surg* 22:263, 1983.
11. Andre' S, Champetier de Ribes P, Sanzieres P, et al.: Swanson silastic arthroplasty in the treatment of disorders of the metatarsophalangeal joint of the great toe. *Rev Chir Orthopedique* 71:95-100, 1984.
12. Brewood AFN, Griffiths JC: The long term results of single stem silastic arthroplasty of the great toe. *J R Coll Surg Edinb* 30:159-161, 1985.
13. Jarvis BD, Moats DB, Burns A, et al.: Lawrence design first metatarsophalangeal joint prosthesis. *J Am Podiatry Med Assoc* 76:617-624, 1986.
14. Farnsworth C, Haggard S, Nahmias MC, et al.: The LaPorta great toe implant. A preliminary study of its efficiency. *J Am Podiatry Med Assoc* 76:625-630, 1986.
15. Kampner S: Long-term experience with total joint prosthetic replacement for the arthritic great toe. *Bull Hosp Jt Dis Orthop Inst* 47: 153-177, 1987.
16. Ris HB, Mettler M, Engeloch F: Long term follow up of Swanson's silastic implant in great toes: Discrepancy between clinical results and radiologic findings. *Z Orthop* 126:526-529, 1988.
17. Arenson D, Proner S: A clinical evaluation of the first metatarsophalangeal joint prosthesis: the use of footprints in assessing foot contact. *J Foot Surg* 20:117, 1981.
18. Yamashina M, Moatamed F: Peri-articular reactions to microscopic erosion of silicone-polymer implants. Light-and scanning electron-microscopic studies with energy-dispersive x-ray analysis. *Am J Surg Path* 9:215-219, 1985.
19. Rogers LA, Longtime JA, Garnick MB, et al.: Silicone lymphadenopathy in a long distance runner: Complications of a silastic prosthesis. *Hum Pathol* 19:1237-1239, 1988.
20. Papagelopoulos PJ, Kitaoka HB, Ilstrup DM: Survivorship analysis of implant arthroplasty for the first metatarsophalangeal joint. *Clin Orthop Rel Res* 302:164-172, 1994.
21. Frisch E: Functional considerations in implant design. *J Med Device Diagnostic Indus* 3:299, 1981.
22. Yoshioka Y, Siu DW, Cooke DV, et al.: Geometry of the first metatarsophalangeal joint. *J Orthop Res* 6:878-885, 1988.
23. Hetherington VJ, Carnett J, Patterson BA: Motion of the first metatarsophalangeal joint. *J Foot Surg* 28:13-19, 1989.
24. Gerbert J, Chang T: Clinical experience with two-component first metatarsal phalangeal joint implants. *Clin Podiatr Med Surg* 12:403-413, 1995.

## ADDITIONAL REFERENCES

- Boberg JS: Koenig total toe implant arthroplasty. In Vickers NS, ed. *Reconstructive Surgery of the Foot and Leg, Update 96* Tucker, Ga: Podiatry Institute Publishing; 1996:136.
- Koenig RD: Koenig total great toe implant. Preliminary report. *J Am Podiatr Med Assoc* 80:462-468, 1990.
- Koenig RD: Revision arthroplasty utilizing the Biomet total toe system for failed silicone elastomer implants. *J Foot Ankle Surg* 33:222-227, 1994.
- Koenig RD, Horwitz LR: The Biomet total toe system utilizing the Koenig score: A five-year review. *J Foot Ankle Surg* 35:23-26, 1996.
- Scott J, Huskisson EC: Graphic representation of pain. *Pain* 2:175, 1976.