

MANAGEMENT OF SURGICAL WOUND COMPLICATIONS

James L. Bouchard, DPM

Wound healing in the foot and ankle is similar to healing occurring elsewhere in the body. The foot and ankle as a weight-bearing distal extremity is often prone to increased exposure to injury. A thorough understanding of the normal processes of wound healing is essential in obtaining optimal surgical results. Clinical investigators and research has identified three basic phases of wound healing: Inflammatory Phase (Substrate); Fibroblastic Phase (Proliferation); Maturation Phase (Remodeling).

INFLAMMATORY PHASE

The inflammatory phase (Substrate) of wound healing occurs during the first 1-5 days following surgery or traumatic injury. The word inflammation is often considered as a negative or undesirable effect. In reality inflammation during healing is essential for the healing process to occur normally. As a surgeon the goal is to prevent excessive inflammation during surgery which is undesirable and may cause increased post-op pain, swelling, redness, infection, dehiscence, and other complications. Capillaries dilate and porous cell walls are characteristic of this phase as the capillaries dilate and their walls become porous causing fluid to exude into the wounded tissue. Fibrin like glue coagulates and seals the edges of the wound together. The strength of the wound is due to the fibrin glue and sutures holding the wound together.

Fibroblastic Phase

The fibroblastic phase (Proliferation) of wound healing occurs during 1-3 weeks following surgery or traumatic injury. This phase is the second phase characterized by rapid growth. Fibroblasts move into the fibrin clot at the wound and begin to synthesize large amounts of collagen, which gives strength to the wound. Thickening of the wound during this phase is evident because of the exuberant synthesis of new collagen.

Maturation Phase

The maturation phase (Remodeling of wound healing occurs 6-12 months following surgery or a traumatic injury. The nodular thick scars and fibrosis of in the second phase of wound healing gradually soften. The process of simultaneous collagen synthesis and degradation occur at a slower rate than during the fibroblastic phase.

This article will present effective management of wound complications with emphasis on phases of wound healing, healing mechanism with skin loss, natural wound healing, healing in compromised tissue. The healing mechanism with skin loss is by wound contraction or epithelialization. Wound contraction may be a very effective process with satisfactory wound closure if the surrounding tissue is relatively mobile. If the surrounding tissue is relatively rigid epithelialization is the major healing mechanism. If the wound edges cannot be readily apposed together then it is unlikely that wound contraction will produce satisfactory closure.

Without skin loss and the processes of wound contraction and epithelialization the three phases of wound healing provide the mechanism of normal wound closure and healing. This natural healing process is the major goal of the surgeon by controlling local and systemic factors.

The foot and ankle are susceptible to many conditions and factors that can inhibit normal wound healing. Many of these conditions and factors if recognized can be managed and controlled to provide an optimal surgical result. Healing in compromised tissues include the following:

1. Arterial insufficiency
2. Diabetes mellitus
3. Venous stasis
4. Smoking
5. Steroids (Glucocorticoids)
6. Vasculitis
7. Hematoma
8. Radiation
9. Pressure ulcers
10. Sickle cell disease
11. Factitious wounds

The foot and ankle are especially susceptible to many conditions causing delayed healing in compromised tissues. Figure 1 illustrates delayed wound healing in an athlete following severe inversion ankle injury without fracture complicated by hematoma formation.

Post injury or post surgery edema is a common condition, which may cause delayed wound healing. Edema may also be caused by many other factors including systemic disorders, venous stasis, arterial insufficiency, and many other conditions. Rest, ice, compression, and elevation are important in treating edema when first recognized to assure a desirable result. Pitting edema when treated early responds rapidly often preventing more serious complications (Figure 2). Non-pitting long standing edema is often more difficult to treat and

commonly associated with other systemic disorders or chronic venous insufficiency. Early effective treatment can prevent pitting edema from leading to chronic edema and fibrosis (Figure 3).

The foot and ankle are often susceptible to hematoma formation following injury or surgery. Deep hematoma must be treated effectively early to prevent infection, which may often cause necrosis and wound dehiscence. Deep hematoma in most cases should be evacuated and the wound left open in the presence of infection to assure proper wound healing (Figure 4). Superficial hematomas are common and readily treated by simple incision and drainage followed by rest, ice, compression and elevation (Figure 5).

Infection following surgery or traumatic injury

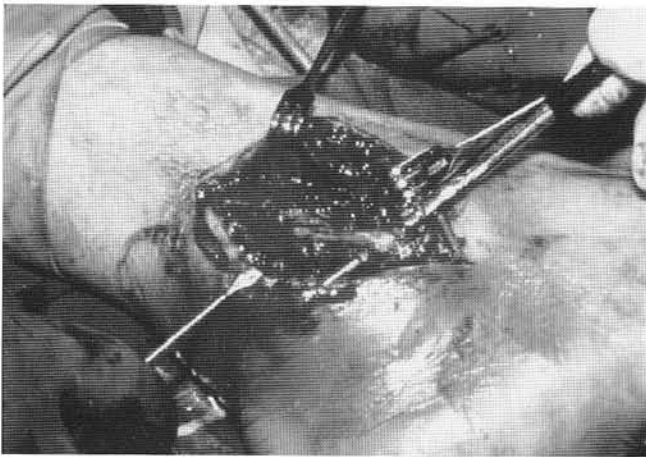


Figure 1. Healing in compromised tissue.

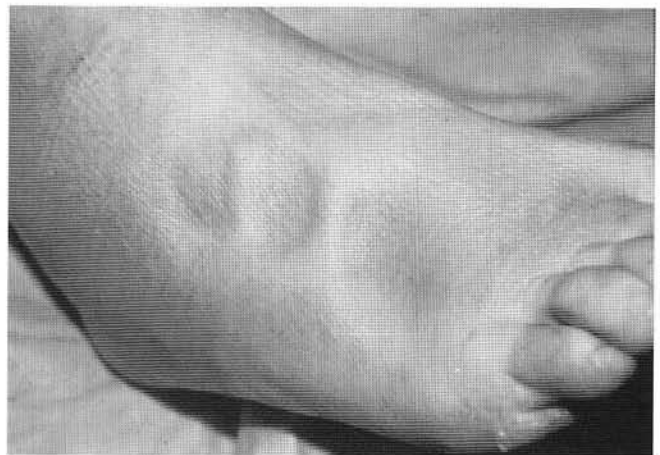

Figure 2. Wound complications: pitting edema.

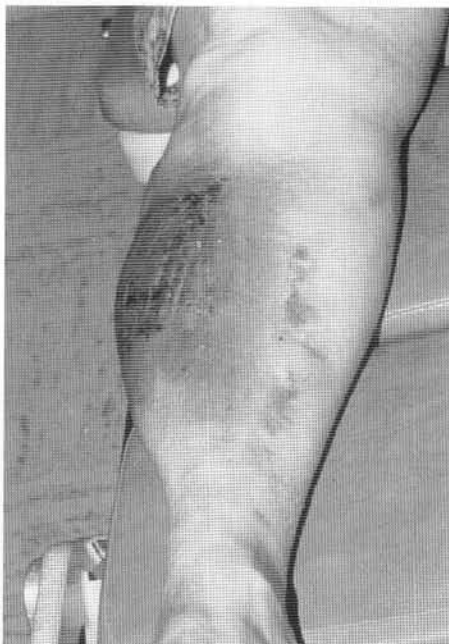

Figure 3. Wound complications: non-pitting edema.

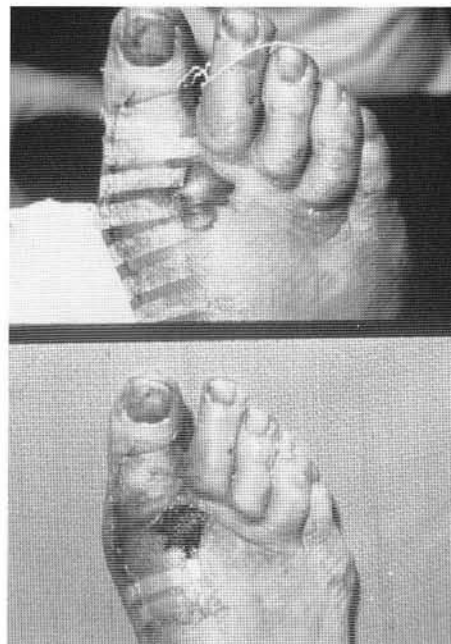


Figure 4. Wound complications: deep hematoma.

often inhibits wound healing (Figure 6). Early recognition and appropriate treatment including appropriate cultures and antibiotic treatment are necessary to obtain a desirable result. Patients with diabetes mellitus and vascular insufficiency the foot and ankle are susceptible to poor wound healing. Diabetic neuropathy can lead to ulceration or lack of healing in chronic ulcers due to the numbness associated with neuropathy making the foot susceptible to repeated trauma and injury.

Hemostasis is essential during surgery to avoid complications of hematoma formation, which may increase the risk of wound dehiscence and secondary infection. Blood vessels should be cauterized or ligated; however, efforts should be made to limit the amount of absorbable suture utilized in the wound. Frequent lavage

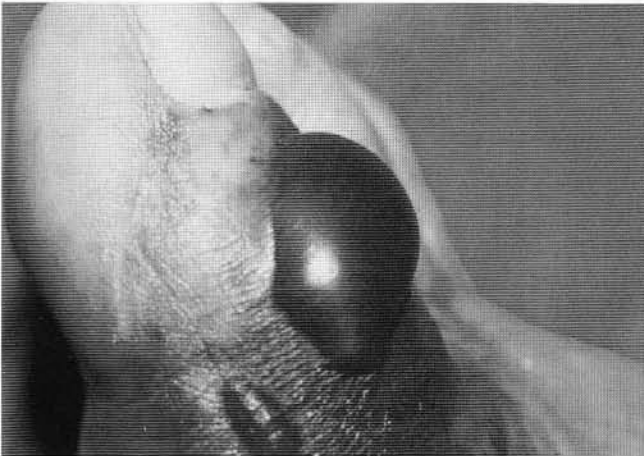


Figure 5. Wound complications: superficial hematoma.

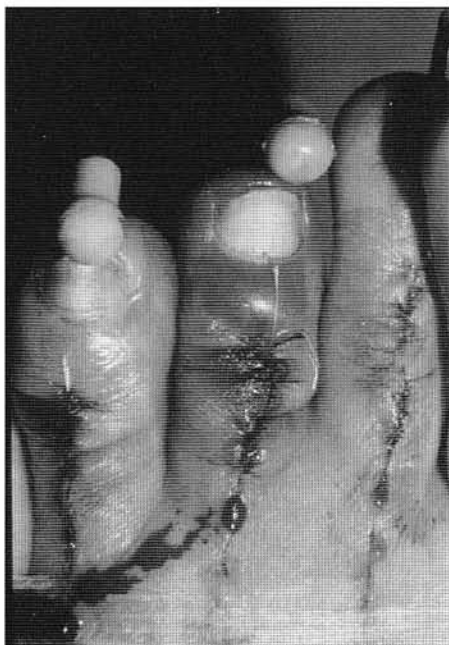

Figure 6. Wound complications: infection.

with cool sterile water during the operation and the placement of the extremity in slight Trendelenburg assists in hemostasis. A tourniquet is rarely used. However, if it is used, it is deflated before final wound closure or packing the wound open to assure adequate hemostasis. The use of a close suction drain is essential to reduce postoperative hematoma formation (Figure 7).

It is essential that all necrotic or diseased tissue be removed when treating wound dehiscence to prevent further complications from infection, or in more severe cases necrotizing fasciitis.

Appropriate intraoperative cultures including gram stain, culture and sensitivity for aerobes and anaerobes, acid fast, and fungal cultures are imperative. In the presence of osteomyelitis, appropriate bone specimens should be sent for definitive diagnosis by pathology as well as bone cultures to isolate the infective organism. It should be noted that when the patients are on preoperative antibiotics, the cultures might show no growth even in the presence of chronic disease. When removing diseased bone, adequate margins must be obtained proximal to the diseased area to assure adequate resection. In the presence of exposed internal fixation devices, the surgeon must make a decision on the benefits versus the consequences of removing the fixation devices (Figure 8).

The importance of appropriate bone biopsy and bone culture cannot be over-emphasized. Final skin closure utilizing interrupted non-absorbable sutures without skin tension followed by compressive dressings, bed rest, elevation, and non-weight bearing ambulation help

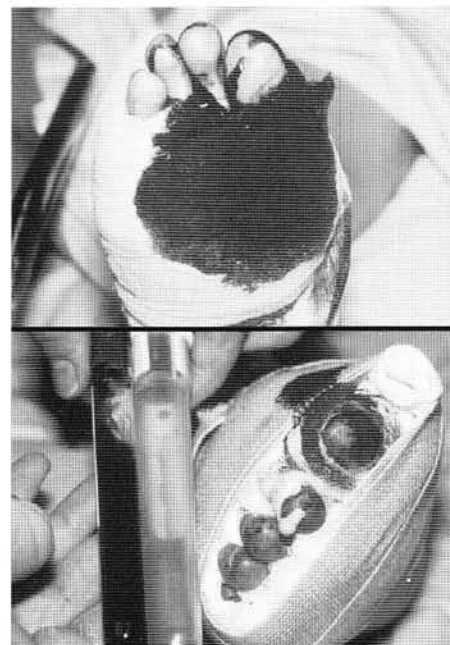


Figure 7. Wound complications: bleeding.

to prevent wound complications including dehiscence and secondary infection.

Dissecting hematoma may be caused by excessive tissue handling during surgery and inappropriate bandaging. Excessive compression proximally and loose compression distally may cause venous congestion particularly in digits which may cause bleeding directly under the skin known as dissecting hematoma (Figure 9).

Open wounds (Figure 10) and a wounds with complex skin loss (Figure 11) require special attention in order to prevent osteomyelitis and possible loss of limb or life due to sepsis. Large tissue loss will not heal by contraction or epithelialization and require skin replacement with a split-thickness skin graft. In the presence of large tissue loss a free muscle graft followed by

a split-thickness graft is indicated as demonstrated in figure 11 involving a patient requiring a free latissimus dorsi muscle transfer to the anterior ankle.

Proper bandaging following injury or surgery is essential in promoting normal wound healing and preventing edema, hematoma, and infection and wound dehiscence. The moistened saline soaked sponge bandage assists in removing blood and fluid away from the wound creating an environment for normal wound healing (Figure 12). Bandaging applied to the foot or ankle in an inappropriate manner without regard to potential bony prominences can cause pressure necrosis and ulceration (Figure 13). Kling directly on skin without proper padding can lacerate or damage the underlining skin causing injury or infection (Figure 13). Maintaining

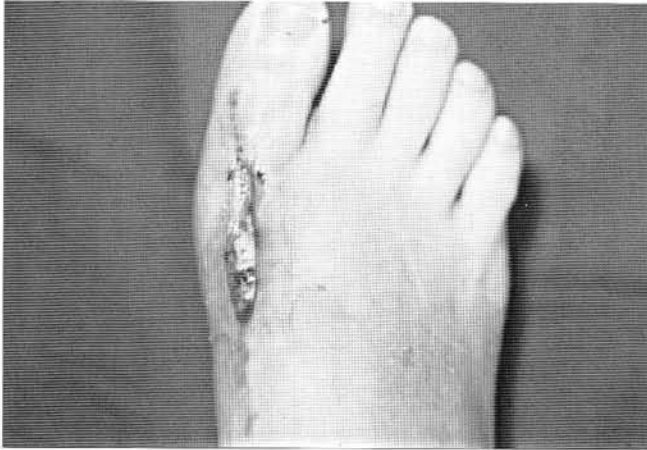

Figure 8. Wound complications: dehiscence.

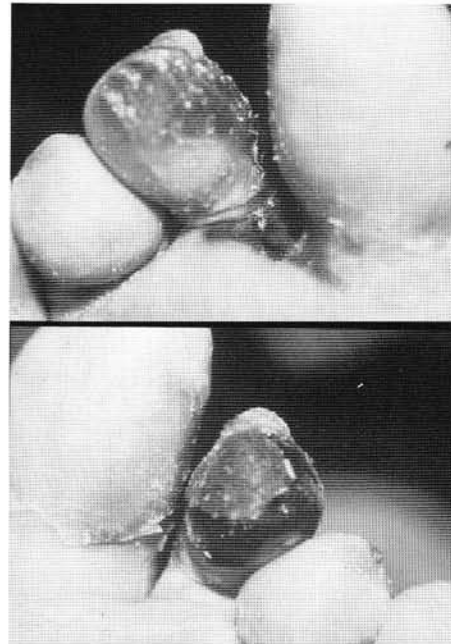


Figure 9. Wound complications: dissecting hematoma.

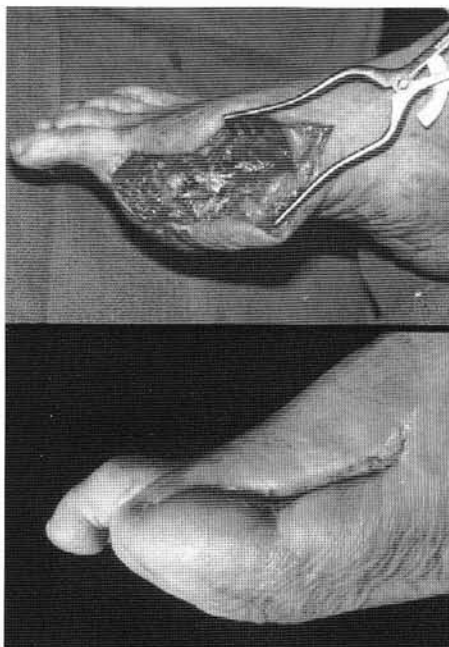


Figure 10. Wound complications: open wound.

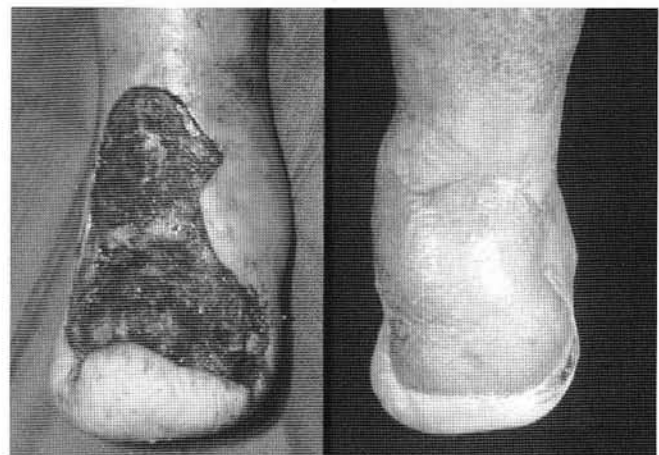

Figure 11. Wound complications: complex skin loss with osteomyelitis.

the foot at 90 degrees to the leg when applying a bandage above the ankle assures proper compression of the foot distally without irritating the skin of the anterior ankle, which may lead to infection or dehiscence (Figure 14). Concentric bandaging using more compression distally and less compression proximally assures adequate compression to promote normal wound healing by controlling swelling and edema (Figure 15, 16). The Jones compression bandage is an excellent bandage for controlling swelling and edema following injury or surgery (Figure 17).

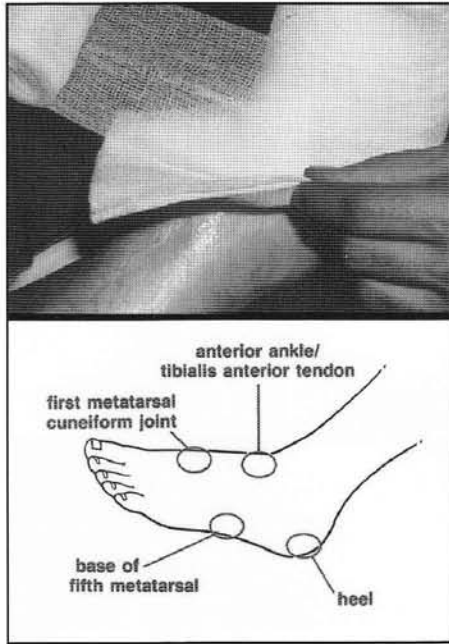


Figure 13. KNOS (no kling on skin).

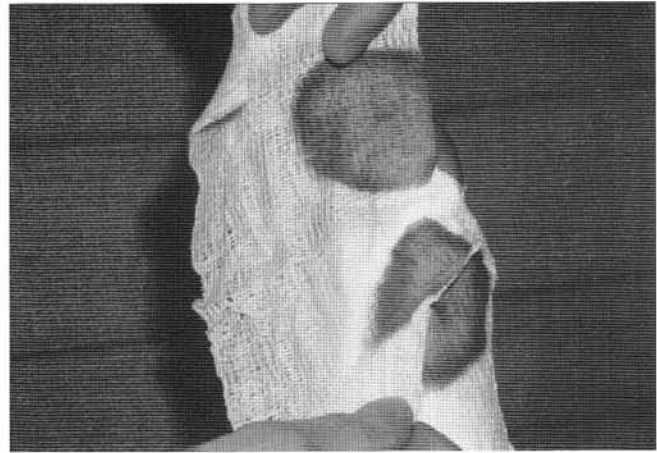


Figure 12. Moistened saline soaked bandage.

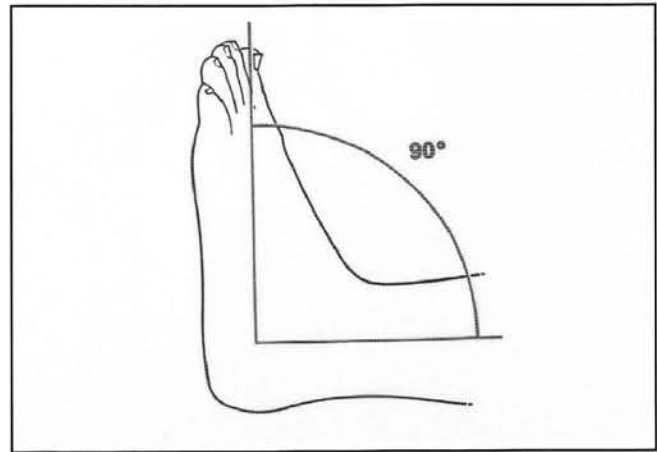


Figure 14. Ankle 90 degrees to leg.

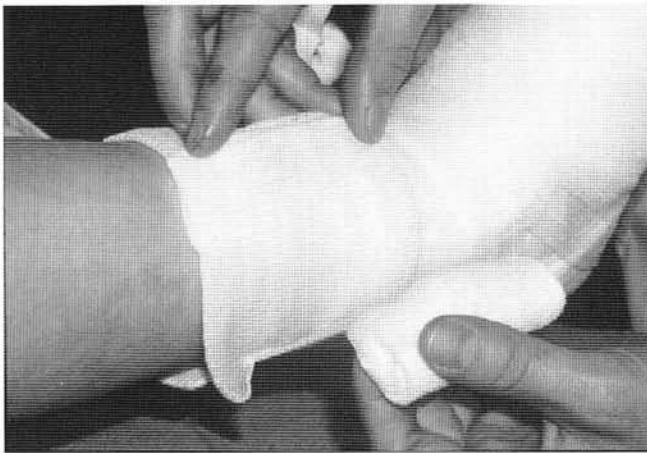

Figure 15. Concentric bandaging.

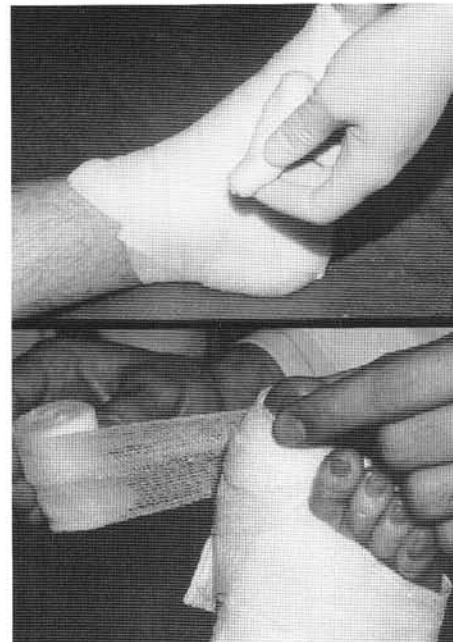


Figure 16. More bandage pressure distally.

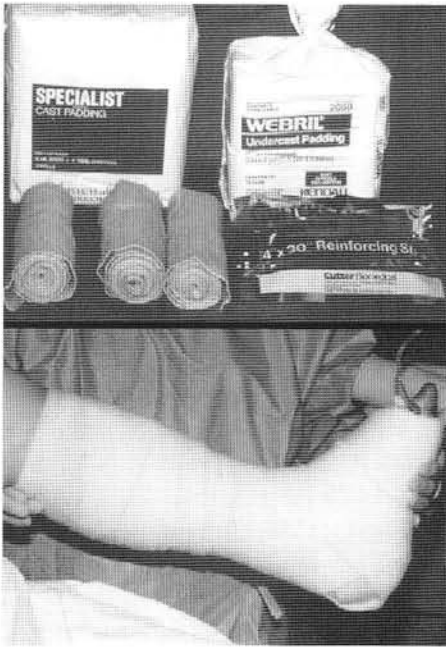

Figure 17. Jones compression bandage.

BIBLIOGRAPHY

- Abramson C, McCarthy DJ, Rupp MJ, eds. Infectious diseases of the lower extremities. Baltimore: Williams & Wilkins, 1991:394.
- Alexander JW: Infection, host resistance, and antimicrobial agents. In American College of Surgeons: *Manual of Preoperative and Postoperative Care*, ed 3, Philadelphia, WB Saunders, 1983, pp 106-136.
- Artz C: Infections in surgery. In Artz CP, Hardy JD: *Management of Surgical Complications*, ed 3, Philadelphia, WB Saunders Co, 1975.
- Bryant WM: Wound healing. *Clinical Symposia*, CIBA Pharmaceutical Co 29:1-36, 1977.
- Burke JF. Infection. In: Burke JF, Dunphy JE, Hunt TK, eds. *Fundamentals of wound management in surgery*. South Plainfield, NJ: Chirurgecom, 1977.
- Cruse PJE: Incidence of wound infection on the surgical services. *Surg Clin North Am* 55:1269-1275, 1975.
- Cruse PJE, Foord R: A five-year prospective study of 23,649 wounds. *Arch Surg* 1907:206-210, 1973.
- Cruse PJE, Foord R. The epidemiology of wound infection: a 10-year prospective study of 62,939 wounds. *Surg Clin North Am* 1980;60:27-40.
- Dineen P (ed): *The Surgical Wound*. Philadelphia, Lea & Febiger, 1981.
- Green R: Pharmacology. In Marcus SA, Block BH (eds): American College of Foot Surgeons - *Complications in Foot Surgery: Prevention and Management*, ed 2. Baltimore, Williams & Wilkins, 1984, pp 78-87.
- Hunt TK, Dunphy JE, eds. *Fundamentals of wound management*. New York: Appelton-Century-Crofts, 1979.
- Joseph WS: *Handbook of Lower Extremity Infections*. New York, Churchill Livingstone, 1990.
- Kalter ES. Inflammatory mediators and acute infection. *Resuscitation* 1984;11:133-140.
- Krizek TJ, Robson MC: Biology of surgical infection. *Surg Clin North Am* 55:1261-1267, 1975.
- Maki DG: The epidemiology of surgical wound infection - guidelines for prevention. *J Surg Pract* 6:10-23, 1977.
- Mathieu A, Burke JF (eds): *Infection and the Perioperative Period*. New York, Gun & Stratton, 1982.
- Migliori V, Kanat IO: Surgical considerations in wound healing. *J Foot Surg* 23:377-381, 1984.
- Miles AA: The inflammatory response in relation to local infections. *Surg Clin North Am* 60:93-105, 1980.
- Miller WA: Postoperative wound infection in foot and ankle surgery. *Foot Ankle* 4:102-104, 1983.
- Mullens, D: Bacterial infections in podiatry. I. *Arch Podiatr Med Foot Surg* 2:255-266, 1975.
- Nelson JP: Musculoskeletal infection. *Surg Clin North Am* 60:213-222, 1980.
- Nichols RL, Smith JQ: Gas in the wound: what does it mean? *Surg Clin North Am* 55: 1289-1296, 1975.
- Peacock EE: *Wound Repair*, ed 3. Philadelphia, WB Saunders, 1984, pp 1-7.
- Polk HC Jr, Miles AA. Enhancement of bacterial infection by ferric iron: kinetics, mechanisms and surgical significance. *Surgery* 1971;70:71.
- Polk HC Jr, Lopez-Mayor JF: postoperative wound infection: a prospective study of determinant factors and prevention. *Surgery* 66:97, 1969.
- Ryan GB: Inflammation and the localization of infection. *Surg Clin North Am* 56:831-846, 1976.
- Spector WG, Willoughby DA: *The Pharmacology of Inflammation*. New York, Grune & Stratton, 1968.
- Stapp Mickey D, Taylor Robert P. Edema, Hematoma and Infection, McGlamrys *Comprehensive Textbook of Foot and Ankle Surgery*, Third Edition, Vol 2, pp 1997-2015.
- Venge P, Lindbom A (eds): *The Inflammatory Process*. An Introduction to the Study of Cellular and Humoral Mechanisms. Stockholm, Almqvist and Wiksell International, 1981.
- Zweifach BW, Grant L, McCluskey RT: *The Inflammatory Process*, ed 2, vols I-III. New York, Academic Press, 1974.