

TECHNIQUES OF GASTROCNEMIUS RECESSION

Gerard V. Yu, DPM, FACFAS

Theresa L. Schinke, DPM

Wissam E. Khoury, DPM

Shane N. Manning, DPM

Recession of the gastrocnemius muscle is one of the oldest orthopaedic procedures described in the literature. It is an effective and predictable method for the treatment of spastic and non-spastic gastrocnemius equinus deformities. Equinus is thought to be a major contributing factor for the development of a number of pathologic conditions including pediatric pes valgus, adult acquired flatfoot and charcot arthropathy.¹⁻³ The focus of this paper is to describe the distal gastrocnemius recession, with emphasis on pearls of the surgical technique to diminish complications, enhance outcomes, and facilitate execution of the procedure.

Equinus is defined as less than 10 degrees of dorsiflexion of the foot to the leg and can be classified as osseous, or muscular.^{1-3,5,6} (see Table) It should be noted that surgical procedures to correct the different types of equinus are distinctly different, therefore it is imperative to identify the specific type of equinus present.

Muscular equinus involves contracture of the posterior crural muscles which can be the result of spastic or nonspastic etiologies. Spastic equinus is usually found in patients with neuromuscular diseases, such as cerebral palsy; it can be acquired or congenital. In the past, spastic equinus was thought to be the most common type of equinus. These individuals are easy to recognize, as they tend to present with classic 'toe-walker' gait, and are

more difficult to correct. Nonspastic equinus is being recognized with increasing frequency, and is probably more common than spastic equinus. Nonspastic equinus may be due to a congenitally shortened tendoachilles. It may also be an acquired deformity or iatrogenic in nature (ie. poor casting techniques).^{1,2}

Posterior muscular equinus can further be broken down into gastrocnemius-soleus equinus or gastrocnemius equinus and can be differentiated by performing the Silverskiold test. To perform the test, the patient should be lying in the supine position. The examiner first determines that an equinus deformity is present by attempting to dorsiflex the foot beyond ninety degrees while the knee is extended. When evaluating for gastrocnemius equinus, the examiner flexes the patients knee to ninety degrees (to remove the influence of the soleus muscle), and again dorsiflexes the patient's ankle. If an increase in dorsiflexion at the ankle joint is appreciated with the knee flexed, but not with the knee extended, a gastrocnemius equinus is felt to be present. This involves contracture of the gastrocnemius and/or plantaris muscles only.^{1,2,5-7}

Gastrocnemius-soleus equinus (gastrocsoleus equinus) involves limitation of ankle joint dorsiflexion both with the knee flexed, and with the knee extended during the Silverskiold test. It involves contracture of all or some of the structures passing posterior to the ankle joint. It must, however, be differentiated from osseous equinus, which produces similar findings with the Silverskiold test.^{1,2}

Osseous equinus involves limited ankle joint dorsiflexion due to pathologic changes about the ankle joint. Talotibial exostosis or other osseous bridging between the tibia and fibula is most commonly the cause of osseous equinus. The clinical examination of ankle equinus gives a significantly different feel at end range of dorsiflexory motion. In osseous equinus, the end range of motion in dorsiflexion is notably a hard or abrupt feel, whereas in gastrocsoleus or gastrocnemius equinus, the end feel is soft or smooth. Conventional radiographs may be taken and examined for possible osseous projections

Table 1

TYPES OF ANKLE JOINT EQUINUS

<u>Muscular Equinus</u>	<u>Osseous Equinus</u>
Gastroc-soleus Equinus	Ankle Joint exostosis
Spastic	Talotibial exostosis
Non-spastic	Tibio-fibular synostosis
Gastrocnemius Equinus	Pseudoequinus
Spastic	Anterior cavus
Non-spastic	

from the margins of the trochlear surface of the talus and the distal surface of the tibia that could limit the dorsiflexion of the ankle joint. Rarely, synostosis may occur between the tibia and fibula which may also limit ankle joint dorsiflexion. Mortise radiographs of the ankle joint are ideal for identifying any osseous pathologic changes of the distal tibiofibular articulation. A stress dorsiflexion view (charger view) of the ankle may also be helpful in evaluating osseous equinus. If equinus is present clinically, and osseous projections are present on radiographic examination, then a diagnosis of osseous equinus can be made. If radiographs are negative for osseous projections or malformations, then muscular equinus must be assumed.^{1,2}

Pseudoequinus is another type of equinus that is often classified as an osseous equinus. Pseudoequinus is not a true ankle joint limitation however, it is a false ankle equinus that is commonly seen in an anterior cavus foot type. In this condition, the entire foot must be dorsiflexed at the ankle to allow the heel of the foot with anterior equinus to reach the ground. Thus the ankle joint dorsiflexion is overtaxed to compensate for the anterior cavus deformity. The inexperienced clinician often falsely identifies an ankle equinus in the anterior cavus foot if he or she measures the sagittal plane bisection of the leg to the forefoot. This allows any plantarflexion of the forefoot on the rearfoot to be included in the measurement. Surgical procedures to correct pseudoequinus are primarily by osseous correction to decrease the anterior cavus deformity.^{1,2}

A full and detailed description of the various types of equinus deformity and their clinical and radiographic differentiation has been published by Downey.^{1,2} The reader is encouraged to read this publication in its entirety for a more comprehensive understanding of equinus deformity, its evaluation, as well as surgical management.

Once it has been determined that gastrocnemius equinus is present, surgical techniques that selectively lengthen the gastrocnemius may be performed. These techniques may include neurectomy of the gastrocnemius muscle, as well as proximal or distal gastrocnemius recessions.

Neurectomy, or selective excision of the tibial nerve branches supplying the gastrocnemius muscle, was first described by Stoffel in 1913 for treatment of spastic gastrocnemius equinus.⁸ It was thought that selective denervation would weaken the gastrocnemius muscle and reduce the equinus deformity. However, neurectomies have fallen out of favor as isolated procedures due to the reported high recurrence rates, consistent loss of function, and atrophy of the gastrocnemius muscle.⁹ Occasionally, they are performed in conjunction with other surgical

procedures for the correction of spastic equinus associated with clonus.^{1,2}

In 1924, Silverskiold first described a proximal recession of the gastrocnemius muscle, which consisted of detaching the medial and lateral heads from the femoral condyles, and transferring them to the proximal tibia.⁷ In 1959, Silver and Simon modified the Silverskiold procedure to include a release of the gastrocnemius muscle heads, without reattachment, and an associated neurectomy. Their study included a total of 110 cases, with 5 recurrences.¹⁰

There is increased risk of surgical complications with proximal recessions including knee effusion and genu recurvatum. There is a moderate recurrence rate with this procedure however, it is still effective and actively utilized for the treatment of muscular equinus due to spasticity of the gastrocnemius muscle.

Distal gastrocnemius aponeurosis recessions may be utilized for correction of either spastic or non-spastic gastrocnemius equinus deformities.^{1,2} The first distal gastrocnemius recession was described in 1913 by Vulpius and Stoffel for the correction of spastic contractures.¹¹ Initially a transverse recession was described, which was quickly modified to take on the shape of an inverted V.^{1,2,6} In 1950, Strayer advocated a transverse recession of the gastrocnemius aponeurosis, with more extensive dissection to free up the proximal flap in order to obtain greater correction. The correction was maintained by securing the aponeurosis to the soleus muscle with suture.¹² In 1958, Strayer published a follow up of his results, reporting a total of 23 cases with 16 excellent results, 2 fair results, and 5 poor results.^{13,12} One poor result was caused by failure to extend the knees at the time of the gastrocnemius recession. The other 4 poor results were attributed to non-compliance with post-operative instructions and inadequate follow-up.¹³ In 2002, Pinney et al. reported an average increase in ankle dorsiflexion of 18.1° after performing the Strayer procedure in 26 limbs.^{14,15}

In 1956, Baker introduced his modification of the distal recession by performing a tongue-in-groove incision in the gastrocnemius aponeurosis, with the tongue portion oriented proximally.¹⁶ Further dissection of the central aponeurosis of the soleus muscle was also performed. This was done to prevent the stretch reflex of the soleus muscle from causing clonus or recurrence. The gastrocnemius ends were then sutured back together in their retracted state.^{16,12}

In 1974, Fulp and McGlamry were the first to perform the distal gastrocnemius aponeurosis recession on non-spastic patients. They proposed that in a non-spastic patient, the deformity was not nearly as severe as in the spastic patient, and felt the deformity was mainly

due to the gastrocnemius muscle without concomitant spasticity or clonus from the soleus muscle. Their modification to the Baker procedure involved inverting the incisions to orient the tongue distally and the groove proximally, while eliminating dissection of the soleus aponeurosis altogether.^{5,1,2}

In a retrospective study, Downey and Banks evaluated 20 patients with non-spastic equinus, who underwent 36 gastrocnemius recessions, utilizing either the traditional Baker or the inverted Baker procedure with an average postoperative period of 5.29 years. There was an average increase of 9 degrees in ankle joint dorsiflexion with both procedures. Mild atrophy of the medial head of the gastrocnemius muscle was noted in those patients that underwent the inverted Baker procedure. They concluded that the gastrocnemius recession procedure does not result in any residual muscle weakness provided the aponeurosis is not over lengthened and the traditional Baker technique is used.^{6,1,2}

Saxena introduced a new technique consisting of an endoscopic release of the gastrocnemius aponeurosis in 2002. He reported performing the procedure on 5 patients, all of which experienced uneventful postoperative recovery, with an average increase in ankle joint dorsiflexion of 10°. Saxena believed the endoscopic technique had considerable advantages over the traditional open procedures including the ability to perform the procedure either supine or prone, shortened anesthesia time, diminished wound healing complications, and improved cosmesis.¹⁷ Tashjian and DiGiovanni et al, subsequently reported their performance of the endoscopic procedure on 15 fresh frozen cadaver limbs. They found that with a modified version of the endoscopic method, complete transection of the gastrocnemius aponeurosis in 15 of 15 (100%) of the specimens and a mean improvement in ankle dorsiflexion of 20 degrees with the knee extended. The sural nerve was injured in one specimen with easy visualization in 5 of 15 specimens.¹⁸

SURGICAL TECHNIQUE

Careful placement and positioning of the patient in a prone position is important before execution of the procedure. The extremity is bolstered so that neither external nor internal rotation of the limb is present. A malpositioned limb can result in placement of the incision in an improper location making the procedure more difficult to perform and increasing the likelihood of a complication, especially entrapment of the sural nerve. The contralateral limb can be supported with a sandbag beneath the patient's hip, underneath the mattress, to

minimize external limb rotation of the opposite side; this is the most frequent problem (external rotated limb while prone) and probably represents, in part, compensation for the equinus deformity itself. Once the incision has been marked, it is usually infiltrated with bupivacaine with epinephrine for local hemostasis; a thigh tourniquet can be employed but is rarely utilized. Anatomic dissection with local anesthetic infiltration provides excellent hemostasis for this procedure.

The skin incision is 1.0 – 2.0 centimeters medial to midline and well below the heads of the gastrocnemius muscle. The gastrocnemius aponeurosis can be palpated and appreciated when the foot is dorsiflexed at the ankle with the knee extended while in the prone position. The incision should not be placed midline or lateral to midline as this will increase the likelihood of encountering the sural nerve and its branches and making execution of the remainder of the procedure more difficult. In addition, entrapment neuropathy of the sural nerve becomes a more likely complication.

Dissection through the subcutaneous layer is facilitated by elevation of the skin with skin hooks with apposing tension on the wound edges, suspending the tissues. While sharp dissection through the subcutaneous tissue can be employed, blunt dissection with metzenbaum scissors is usually preferred as this layer is composed of adipose tissue. One should maintain a watchful eye for the lesser saphenous vein and nerve. If encountered they should be retracted, preferably laterally and carefully protected through the balance of the procedure. Additional hemostasis is achieved with electrocautery and rarely ligation if larger lumen vessels are encountered. Dissection is carried directly down through the subcutaneous tissues (adipose tissue) to the level of the deep fascia. (Figure 1)

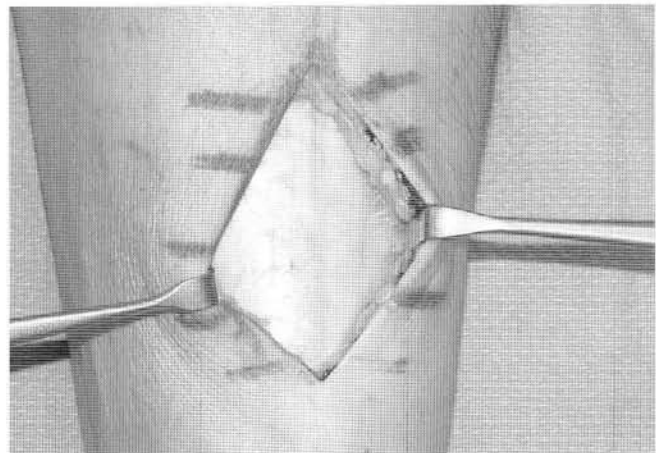


Figure 1. Intraoperative appearance of the deep fascia and paratenon before they are incised and reflected. Notice the skin and subcutaneous tissue has been reflected and retracted as a single layer from the underlying deep fascia layer. (left leg)

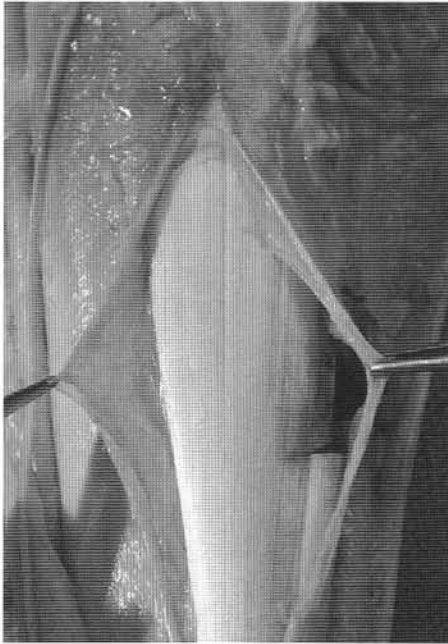


Figure 2. Cadaveric dissection specimen depicting incision of the deep fascia and paratenon which have been reflected back from the underlying gastro-soleus aponeurosis. A portion of the fibers has been transected.

In some patients a pseudo-fascial layer will be encountered making the dissection somewhat confusing. If one encounters additional adipose tissue beneath what is thought to be the deep fascia, then the deep fascial layer has probably not yet been correctly identified. In addition, if one identifies the lesser saphenous vein and nerve beneath this pseudo-fascial layer, it again confirms that the deep fascia has not yet been reached. There is no adipose tissue beneath the deep fascia; only the aponeurosis tissue (which is very well defined as a white dense tendinous layer) should be seen directly beneath the deep fascia.

Once the deep fascia is identified the subcutaneous layer is separated both medially and laterally along this tissue plane. This can be accomplished with blunt dissection techniques. A very effective technique is to “peel” this layer back using a moistened saline sponge. This allows increased retraction of the skin and subcutaneous tissues as a single layer with longer retractors, such as Army Navy retractors, facilitating visualization of the aponeurosis; this distinct separation of the skin and subcutaneous layer from the deep fascia also facilitates closure of the deeper tissues following tendon lengthening.

Next, the deep fascia and paratenon tissues are incised as a single layer. These two layers are intimately arranged. The deep fascial layer is thicker and denser, consistent with most deep fascial tissues within the body, while the paratenon layer is a loosely organize

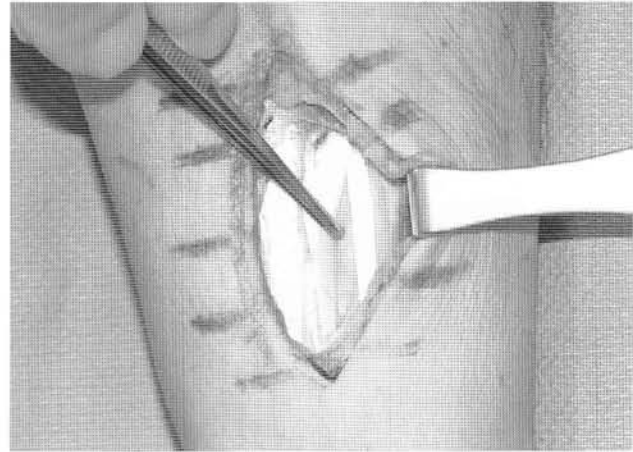


Figure 3. Intraoperative appearance following incision of the deep fascia and paratenon which have been reflected. The medial border of the tendon is seen. The plantaris tendon is readily appreciated as a distinct entity. One can readily appreciate the natural separation of the gastrocnemius aponeurosis fibers from the underlying soleal fibers. The plantaris tendon is transected as part of the surgical lengthening

gossamer-like tissue with little structural strength or organization. It is the interface between the deep fascia itself and the actual aponeurosis layer of the muscle. The tendon itself should not be incised. Once the fascia and paratenon have been incised, they are separated from the underlying aponeurosis by taking the blunt back end of the scalpel handle and “sweeping” superiorly and then inferiorly both medially and laterally between the paratenon and the aponeurosis fibers. The technique is analogous to sweeping your hands beneath the bed sheets or blankets in search of a small lost object without significantly disturbing the arrangement of the sheets or blankets themselves. (Figure 2) The skin, subcutaneous tissues, deep fascia and paratenon are now retracted medially and laterally with the deep end of the Army Navy retractors. (Figure 3) Next is the actual technique of tendon transection; we will describe the most common techniques employed by the senior author for over 20 years.

Modified Vulpius/Strayer Technique

Before performing tendon transection, the surgeon should carefully observe the specific anatomy of the gastrocnemius aponeurosis in each patient. The plantaris tendon is usually identified at the medial border of the aponeurosis and should be sharply transected. A careful, detailed, focused examination of the edges of the aponeurosis will reveal whether the gastrocnemius and soleal fibers can be visualized as separate, distinct layers merging together or whether they are already merged together as one single layer with no visual distinction.

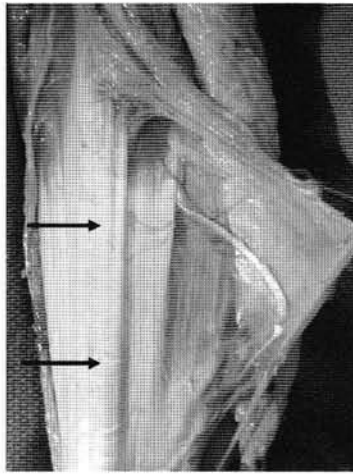


Figure 4. Cadaveric specimen showing reflection of the deep fascia and paratenon tissues medially. The plantaris tendon has been cut and reflected. Transection of the superficial fibers at the level of the proximal arrow would allow selective lengthening of the gastrocnemius fibers alone. The distal aspect of the gastrocnemius muscle itself can be seen as the tendinous fibers originate. The distal arrow indicates the level at which the gastrocnemius and soleal fibers merge together as one to form the tendoachilles.

In many cases, one can actually appreciate two separate distinct layers comprising the aponeurosis. As one progresses more distally, the two layers of the aponeurosis merge together as one and eventually form the tendoachilles. (Figure 4)

Whenever two separate distinct layers are seen, we will attempt surgical lengthening of the gastrocnemius portion (the more superficial layer of the two) only, beginning at the edge where the distinction is best appreciated; it is most commonly the medial aspect. The knee is maintained in an extended position and the foot dorsiflexed at the ankle to create maximum tension on the tendon complex. The superficial fibers are then cut from medial to lateral (or lateral to medial) leaving the deeper layer (soleal fibers) intact. (Figure 5) If immediate separation (lengthening) of the fibers is visualized as the fibers are transected, the process is continued to the opposite side of the tendon. The gastrocnemius fibers are now appreciated in their lengthened position, usually about one-inch while the deeper fibers of the soleus are still observed intact. (Figure 6a, 6b)

In some cases, as the transection is being performed from one side to the other, the distinct separation is lost and the full thickness of the aponeurosis is transected exposing the underlying muscle tissue itself. The key to success of this technique is direct observation and appreciation of the aponeurosis as a single layer or two distinct layers which are merging together. Another important aspect of the procedure is a controlled depth transection of the more superficial fibers. A hemostat or

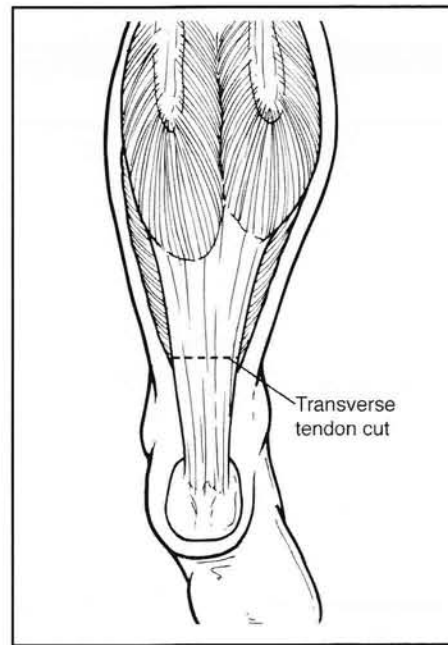


Figure 5. Diagram showing the level of the transection for the strayer procedure.

similar instrument can be used to enhance the separation before transection, but is not generally done in our cases. We believe this increased dissection, although facilitating an appreciation of the two distinct layers, increases post-operative fibrosis and adhesions.

Fulp and McGlamry Modified Tongue-in-Groove Technique

Our alternative technique is a modification of the more traditional tongue-in-groove approach initially described by Baker, with the tongue being oriented distally rather than proximally. (Figure 7) knee is maintained in an extended position with the foot and ankle maximally dorsiflexed. The proximal medial and proximal lateral one-third of the aponeurosis are identified and the fibers sharply transected beginning at the junction of the medial or lateral one-third and progressing to the outer edge of the tendon. Cutting of these fibers is done with a standard Bard Parker #15 surgical blade or if preferred a #64 Beaver blade. The blade enters the tendon oriented parallel to the longitudinal direction of the fibers; immediately after penetration through the tendon, the blade is rotated 90 degrees and the fibers cut using an up and down controlled cutting maneuver. Immediate lengthening is usually appreciated as soon as the tendon fibers are transected. After lengthening one portion (either the medial or lateral aspect), the opposite side is lengthened. The central one-third of the aponeurosis has not yet been cut and its continuity unaltered; palpation of

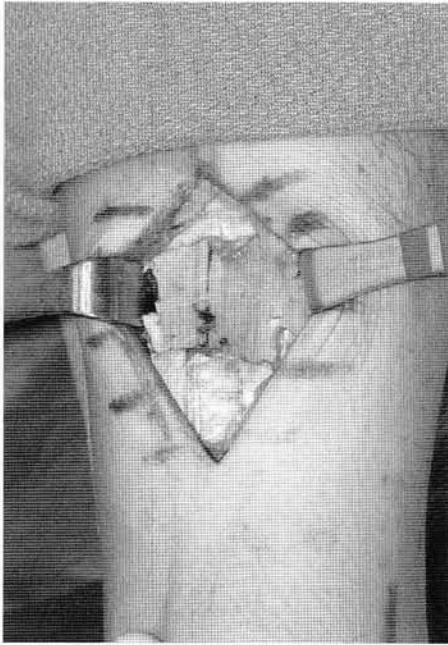


Figure 6a. This is the intraoperative appearance following transverse transection of the gastrocnemius aponeurosis fibers only. The underlying fibers represent the tendinous portion of the soleus muscle. The lateral fibers of the underlying soleus have also been transected due to the tightness of the fibers following lengthening of the gastrocnemius fibers. The decision to transect these fibers is an intraoperative one.

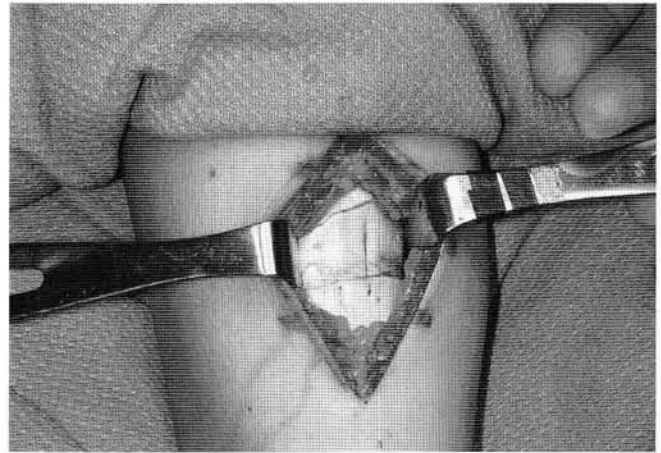


Figure 6b. Appearance of a pediatric patient following a modified strayer procedure in which the gastrocnemius aponeurosis fibers have been transected and lengthened. Note the underlying preservation of the soleal fibers. The distal portion of the transected plantaris tendon can also be seen.

these central fibers will demonstrate their toughness. Care is taken to avoid accidental cutting of muscle tissues as these bleed quite readily when traumatized.

The foot is then plantarflexed and the distal central one-third fibers of the aponeurosis are identified, grasped with forceps and transected using a sharp technique. Slight dorsiflexion of the ankle will cause the central fibers to become taught and facilitate grasping them with forceps. These fibers are not cut from medial to lateral or vice versa, but rather, cut the outside edge to the center of the aponeurosis. The fibers should be maintained or bunched as a group until they have been completely transected. Now, the distal central one-third fibers of the aponeurosis have been transected in effect creating the tongue portion of the lengthening technique. At this point the surgeon should confirm that the proximal medial and proximal lateral fibers of the aponeurosis and the distal central fibers of the aponeurosis have all been cut. Several inches of distance should be present between the proximal tendon cuts and the distal tendon cut.

Once confirmation of the segments lengthened is confirmed, the foot is held in neutral position and the knee maintained in an extended position; the ankle is dorsiflexed under a controlled gradually increasing load until sufficient tendon lengthening is observed. The actual lengthening is

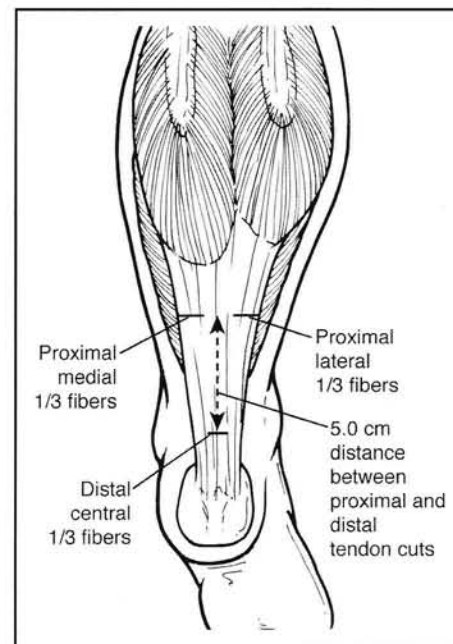


Figure 7. Diagram showing the location of the 3 separate cuts for the Fulp & McGlamry Modified Tongue-in-Groove procedure

quite impressive and is typically 1 – 1-1/2 inches. If lengthening is not observed, the site is inspected to ensure that the medial one-third, lateral one-third and central one-third fibers have indeed been cut.

While most surgeons reinforce the lengthened tendon at various points where the slide lengthening overlaps, the senior author does not perform any suturing of the newly lengthened tendon and has not done so for the last 13 years. No complications attributed to not suturing the lengthened tendon have been encountered. Further lengthening does not seem to occur as the limb is protected in a short leg cast

with the foot at 90 degrees. Some surgeons do prefer to close the defect distal to the end of the tongue portion by suturing the medial and lateral edges together. The senior author does not perform this maneuver and has not encountered any complications as a result of not doing so.

The wound is then irrigated with copious amounts of normal sterile saline. With the knee extended and the foot dorsiflexed, the areas of lengthening are palpated to check for individual deeper strands of tendon which are still intact and require transection. They are like individual spaghetti strands of taut tendon which can cause significant postoperative discomfort if not released. Release of these individual strands is analogous to performing a percutaneous tenotomy.

Once adequate lengthening of the tendon is confirmed, the wound is irrigated and prepared for closure. The deep fascia and paratenon layer are closed as a single layer or unit with synthetic absorbable multifilament 3-0 or 4-0 suture in a continuous running manner. (Figure 8) The foot is periodically dorsiflexed and plantarflexed to ensure that this layer is not accidentally sutured to the underlying tendon itself. The underlying tendon should be observed moving freely without attachment at any point to the overlying paratenon or deep fascia. Next, the subcutaneous tissue layer is closed with a running stitch of synthetic absorbable, multifilament 4-0 suture. The skin is repaired with an intradermal or subcuticular stitch of 5-0 absorbable or nonabsorbable suture of choice. Full length wound closure strips are applied to minimize tension on the skin edges and help attain a fine line scar; they are left intact and undisturbed for 4-6 weeks.

No additional local anesthetic is usually required since long acting solutions were employed from the start of the procedure. If the nerve is encountered it can be bathed with short acting steroid to decrease inflammation and postoperative scar tissue formation around the nerve. If a tourniquet was employed, which we find unnecessary, it is released and additional hemostasis achieved with ligatures or electrocautery. A dry sterile dressing is applied.

POSTOPERATIVE MANAGEMENT

Postoperative management consists of cast immobilization for a minimum of four weeks and more commonly 5-6 weeks. Other procedures will dictate longer periods of immobilization in most patients. At the very minimum, the senior author recommends a non-weightbearing status for the first 4 weeks, followed by progressing increase in weight bearing to full weightbearing and ambulation by the sixth week.

The cast is usually removed six weeks postoperatively.

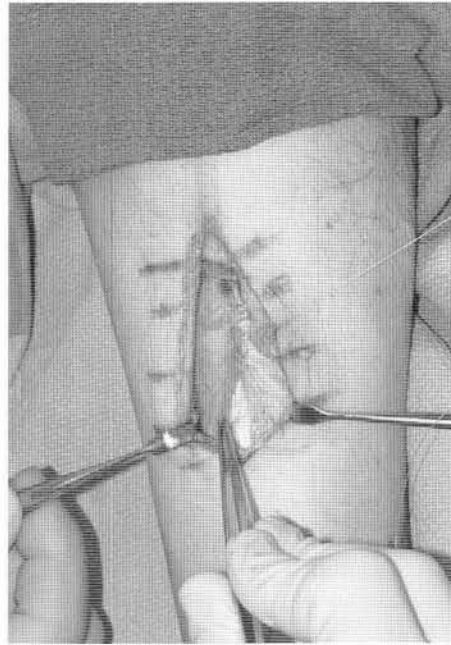


Figure 8. Intraoperative photo showing partial closure of the deep fascia and underlying paratenon as a single layer. The deep fascia layer, which is more superficial, has a whiter slightly denser appearance although it is a very thin layer. The underlying paratenon fibers are a gossamer-like tissue layer, which preserve the gliding function of the underlying tendon.

The wound closure strips are also removed. Physical therapy can be instituted to help restore full strength while maintaining good ankle dorsiflexion to at least 10 degrees. Edema, which is rarely a significant issue with this procedure, is easily controlled with compression stockings, low dose diuretic therapy and physical therapy. By 3-4 months, most patients will make a full functional recovery.

COMPLICATIONS

With meticulous surgical technique and proper postoperative management, complications following this type of surgery are rare. Like most surgical procedures, wound infection and complication remain dreaded but rare occurrences.

Complications specific to tendon procedures include over lengthening or under lengthening and again are rare problems. Over lengthening could result in a calcaneus deformity but is more common following tendoachilles lengthening. Recurrence of the equinus could also occur but is rarely reported. Its occurrence is more likely when these procedures are performed in patients with underlying neuromuscular disease, especially those associated with spasticity.

A complication of particular concern is entrapment neuropathy of the sural nerve within the incision site. This complication can result in minimal symptomatology and in other cases, severe neuritic symptoms which mimic complex regional pain syndrome. A specific trigger point can usually be identified. A selective diagnostic nerve block can be administered and will usually resolve all symptoms for a short period of time confirming the clinical suspicion of a post surgical entrapment neuropathy. If patients fail to respond to pharmacologic agents, physical therapy and tincture of time, surgical exploration with release of the nerve is likely to be required. In some patients resection of the sural nerve may be necessary.

REFERENCES

1. Downey MS. Ankle equinus. In: Banks AS, Downey MS, Martin DE, Miller SJ, editors. Comprehensive textbook of foot surgery. Baltimore: Lippincott Williams & Wilkins; 2001. p. 715-760.
2. Downey MS. Ankle equinus. In: McGlamry ED, Banks AS, Downey MS, editors. Comprehensive textbook of foot surgery. Baltimore: Williams & Wilkins; 1992. p. 687-730.
3. Schoenhaus HD, Jay RM. A modified gastrocnemius lengthening. *J Am Podiatry Assoc* 1978;68:31-7.
4. DiGiovanni CW, Kuo R, Tejwani N, Price R et al. Isolated gastrocnemius tightness. *J Bone Joint Surg Am* 2002;84:962-9.
5. Fulp MJ, McGlamry ED. Gastrocnemius tendon recession: tongue in groove procedure to lengthen gastrocnemius tendon. *J Am Podiatry Assoc* 1974;64:163-71.
6. Downey MS, Banks AS. Gastrocnemius recession in the treatment of nonspastic ankle equinus: a retrospective study. *J Am Podiatry Med Assoc* 1989;19:159-74.
7. Silverskiold N. Reduction of the uncrossed two-joints muscles of the leg to one-joint muscles in spastic conditions. *Acta Chir Scand* 1924;56:315-30.
8. Stoffel A. The treatment of spastic contractures. *Am J Orthop Surg* 1913; 10:611-44.
9. Martz CD. Talipes equinus Correction in cerebral palsy. *J Bone Jt Surg* 1950;42:769-76.
10. Silver CM, Simon SD. Gastrocnemius-muscle recession (Silverskiold operation) for spastic equinus deformity in cerebral palsy. *J Bone Jt Surg Am* 1959; 41:1021-8.
11. Vulpius O, Stoffel A. Orthopadische Operationslehre. Ferdinand Enke, Stuttgart, 1913. Tenotomie der end schnen der mm. gastrocnemius el soleus mittels rutschenlassens nach vulpius; p 29-31.
12. Strayer LM. Recession of the gastrocnemius: an operation to relieve spastic contracture of the calf muscles. *J Bone Jt Surg Am* 1950; 32:671-6.
13. Strayer LM. Gastrocnemius recession: five-year report of cases. *J Bone Jt Surg Am* 1958;40:1019-30.
14. Pinney SJ, Hansen ST, Sangeorzan BJ. The effect on ankle dorsiflexion of gastrocnemius recession. *Foot Ankle Int* 2002;23:26-9.
15. Donley BG, Pinney SJ, Holmes A. Gastrocnemius recession. *Tech Foot Ankle Surg* 2003;2:35-9.
16. Baker LD. A Rational approach to the surgical needs of the cerebral palsy patient. *J Bone Jt Surg Am* 1956;38:313-23.
17. Saxena A. Endoscopic gastrocnemius tenotomy. *J Foot Ankle Surg* 2002; 41:57-8.
18. Tashjian RZ, Appel JA, Banerjee, DiGiovanni CW. Endoscopic gastrocnemius recession: evaluation in a cadaver model. *Foot Ankle Int* 2003;24:607-12.

ADDITIONAL REFERENCES

- Banks HH, Green WT. The correction of equinus deformity in cerebral palsy. *J Bone Joint Surg Am* 1958; 40:1359-79.
- Borton DC, Walker K, Pirpiris M, Nattrass GR, Graham HK. Isolated calf lengthening in cerebral palsy. *J Bone Jt Surg Br* 2001;83:364-70.
- Craig JJ, Van Vuren J. The importance of gastrocnemius recession in the correction of equinus deformity in cerebral palsy. *J Bone Jt Surg Br* 1976;58:84-7.
- Grady JF, Saxena A. Effects of Stretching the gastrocnemius muscle. *J Foot Surg* 1991; 30:465-69.
- Green WT, Calandriello B. The detachment of gastrocnemius muscles in the treatment of spastic equinus foot. *Bull Hosp Jt Dis* 1959;20:48-52.
- Green WT, McDermott LJ. Operative treatment of cerebral palsy of the spastic type. *JAMA* 1942;118:434-40.
- Javors JR, Klarren HE. The vulpius procedure for correction of equinus deformity in cerebral palsy. *J Pediatric Orthop* 1987;7:191-3.
- McGlamry ED, Kitting RW. Equinus foot: An analysis of the etiology, pathology and treatment techniques. *J Am Podiatry Assoc* 1973;63:165-84.
- Pollack GA. Lengthening of the gastrocnemius tendon in cases of spastic equinus deformity. *J Bone Jt Surg Br* 1953;35:148.
- Sharrard WJW, Bernstein S. Equinus deformity in cerebral palsy: a comparison between elongation of the tendo calcaneus and gastrocnemius recession. *J Bone Jt Surg Br* 1972; 54:272-6.
- Thomas F, Sands AK. Treatment of equinus contracture. *Tech Foot Ankle Surg* 2003; 2:180-5.
- Takahashi S, Shrestha A. The Vulpius procedure for correction of equinus deformity in patients with hemiplegia. *J Bone Jt Surg Br* 2002;84:979-80.
- Yngve DA, Chambers C. Vulpius and Z-lengthening. *J Pediatr Orthop* 1996;16:759-64.