

SURGICAL TECHNIQUES OF DIGITAL AMPUTATION AND MANAGEMENT OF COMMON COMPLICATIONS

James L. Bouchard, DPM

Locomotion is the primary function of the lower extremity, and foot preservation is a major goal of the podiatric surgeon. According to published statistics, over 40,000 amputations are performed annually on diabetic patients. Of these, 65% are leg amputations, 31% toe amputations, and 4% foot amputations. Of these amputations, there is a 30% mortality rate during the first three years and a 60% mortality rate after five years. Furthermore it is estimated that 85% of these amputations could be prevented through proper patient education and proper early treatment in preventing foot ulcerations. When a neurotrophic diabetic patient presents with chronic foot ulceration, a more proximal amputation is not always necessary. Digital or partial forefoot amputations may allow for preservation of a functional foot with the major advantage being the ability to bear weight.

Since the amount of energy expended during gait increases as the level of amputation progresses proximally, foot preservation becomes one of the major goals of the podiatric surgeon. As podiatrists we are all aware of the excessive load placed on the remaining contra lateral limb following leg amputation. Digital amputations unlike lesser ray amputations are indicated when the infection or necrotic tissue does not extend to the web space of the foot or the metatarsophalangeal joint. An understanding of the basic principles and techniques of amputation surgery is essential in obtaining an optimal surgical result.

The purpose of this presentation is to present the principles and techniques of amputation surgery as applied to digital amputations emphasizing the intraoperative procedures and surgical technique. One of the major objectives of digital amputation is to maintain a functional stump, which is capable of adequate wound healing, thus preventing the need for additional amputation at a more proximal level. Generally, most investigators agree that the more distal the site of amputation the less energy that is required in walking and the more functional the postoperative results. The indications for digital amputation include gangrene of one or more toes which has stabilized and does not involve the dorsal or plantar aspect of the foot. Digital amputations are also effective in non-healing open infected lesions of the digits in a neurotrophic foot and when the infectious process has not extended to the web space or plantar aspect of the distal foot.

GENERAL PRINCIPLES AND TECHNIQUE OF DIGITAL AMPUTATIONS

Most surgeons agree on certain basic techniques in amputation surgery in order to obtain a successful result. These may be categorized in the following anatomical groups: skin, muscle function, nerve endings, blood vessels, the bony prominences, and infected tissues.

Skin

Great care must be taken by the surgeon to minimize trauma to the skin by avoiding unnecessary instrumentation or excessive handling of the tissues. In digital amputation surgery anatomical dissection with separation of tissue layers is avoided in order to preserve the deep circulation and viability of the tissues. During surgery, consideration must be given to each tissue encountered and the role that it will play in providing function following amputation. It is imperative that all diseased tissue is excised and that no dead space remains prior to final closure. It is important to determine whether the wound should be packed open or closed by secondary healing, delayed primary closure at a later date or closed primarily at the time of surgery.

The surgeon must avoid overlapping or inverting the skin margins during skin closure, which lead to an increased incidence of wound dehiscence, secondary infection, and possible progression to a more proximal amputation. The optimal skin closure involves skin margins end to end or slightly everted utilizing a non-reactive material, usually a monofilament suture, with no tension on the wound edges (Figure 1).

Too few or too many sutures also lead to complications of improper skin closure causing wound dehiscence in many cases. In the presence of peripheral vascular disease the surgery must be meticulous with delicate handling of all tissue. Strict aseptic technique should be utilized to avoid wound infection, which may lead to a disastrous result. In the presence of serious infection and ischemia, packing the wound open usually provides a lower rate of wound complications or sepsis. Staging the time and level of the digital amputation is imperative. In the presence of infection, appropriate

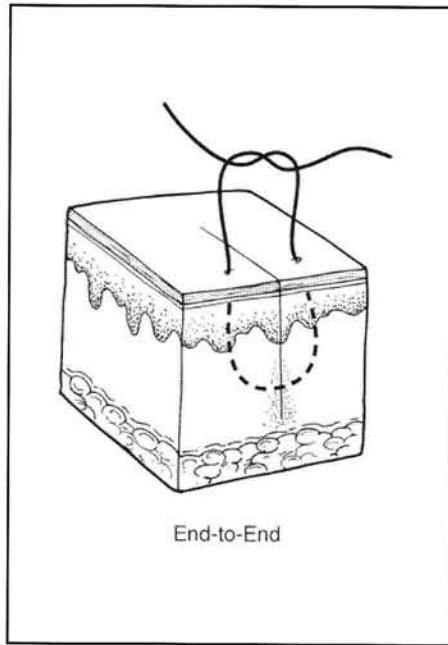


Figure 1. Skin margins end-to-end or slightly everted.

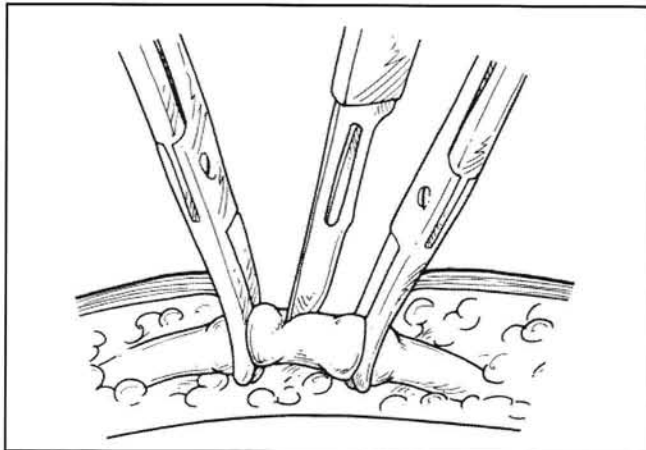


Figure 2. Ligation of blood vessels to prevent hematoma.

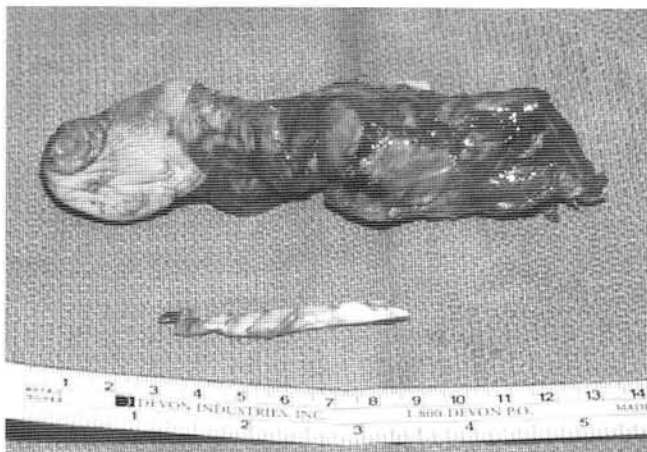

Figure 3. Bone biopsy and cultures.

antibiotics given preoperatively and postoperatively help assure appropriate healing of the wound edges. Strict non-weight bearing is not mandatory and the patient may usually ambulate in a surgical shoe.

Preservation of Muscle Function

Preservation of muscle function is extremely important when a digital amputation is performed. As the insertion of the flexor digitorum longus and extensor digitorum longus tendons are violated during digital amputation, there is a higher incidence of muscle imbalance, which commonly presents as an associated deformity of the adjacent digits. Amputations involving the entire second digit commonly are associated with subsequent hallux valgus deformity in which the hallux deviates laterally filling the void created by the amputation of the second digit. In severe foot infections, there may be extensive necrosis of major muscle function necessitating a more proximal amputation such as a below-the-knee or above-the-knee amputation. Two major factors usually accounting for failure of digital amputations are abnormal pressure at the stump site and the development of adjacent deformity.

Nerve Endings

Painful and disabling stump neuromas are common following digital amputation.

All sensory nerves encountered dorsally and plantarly should be sharply incised at a proximal level protecting them from any potential external force such as the patient's prosthesis or shoe. The incised nerve endings should be allowed to retract proximally to avoid reinnervation of the skin or distal anatomical structures. In addition to nerve endings being sharply incised, all flexor and extensor tendons are identified and incised at a proximal level allowing the tendon to retract proximally.

Blood Vessels

Hemostasis is essential during amputation surgery to avoid complications of hematoma formation, which may increase the risk of wound dehiscence and secondary infection. Blood vessels should be cauterized or ligated (Figure 2); however, efforts should be made to limit the amount of absorbable suture utilized in the wound. Frequent lavage with cool sterile water during the operation and the placement of the extremity in slight Trendelenburg assists in hemostasis. A tourniquet is rarely used. However, if it is used, it is deflated before final wound closure or packing the wound open to assure adequate hemostasis. The use of a close suction drain is essential to reduce postoperative hematoma formation.

Bony Prominences

Adequate surgical planning is necessary to assure that no remaining bony prominences are evident in potential weight bearing areas. Appropriate power instrumentation and remodeling of any irregular surfaces prior to closure are essential. This is imperative when an osteotomy amputation technique (Figures 4, 5) is utilized rather than a disarticulation amputation (Figures 6, 7).

Removal of Diseased Tissue

It is essential that all necrotic or diseased tissue be removed at the time of amputation to prevent further complications from infection, or in more severe cases necrotizing fasciitis.

Appropriate intraoperative cultures including gram stain, culture and sensitivity for aerobes and anaerobes, acid fast, and fungal cultures are imperative. In the presence of osteomyelitis, appropriate bone specimens should be sent for definitive diagnosis by pathology as well as bone cultures to isolate the infective organism. It should be noted that when the patients are on preoperative antibiotics, the cultures might show no growth even in the presence of chronic disease. When removing diseased bone, adequate margins must be obtained proximal to the diseased area to assure adequate resection (Figure 7).

The importance of appropriate bone biopsy and bone culture cannot be over-emphasized. Final skin closure utilizing interrupted non-absorbable sutures without skin tension followed by compressive dressings, bed rest, elevation, and non-weight bearing ambulation help to prevent wound complications including dehiscence and secondary infection which may lead to more proximal amputation at a later date.

Postoperative Management

Most postoperative regimens do not require non-weight bearing. It is important for the podiatric surgeon not to neglect the contralateral limb, which is at increased risk, which requires frequent monitoring, and protective measures. The use of surgical shoes is an excellent regimen to progress to normal footwear. Dry sterile bandaging is applied using concentric bandaging using more compression distally than proximally. It is imperative to avoid using excessive pressure during bandaging the toe, foot and ankle. No Kling on skin without proper padding of the potential pressure sites and bony prominences. (Figure 8).

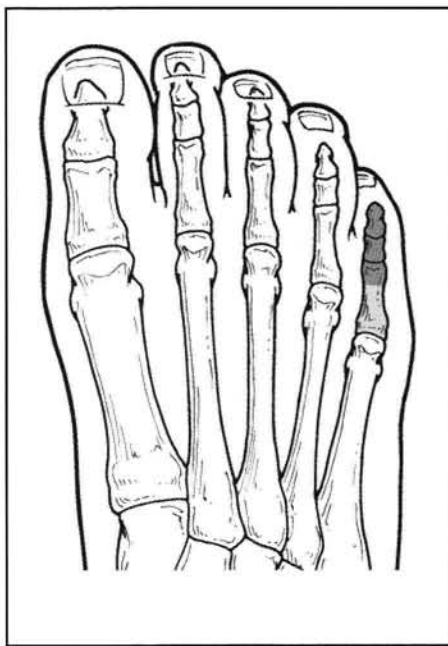


Figure 4. Partial digital osteotomy amputation

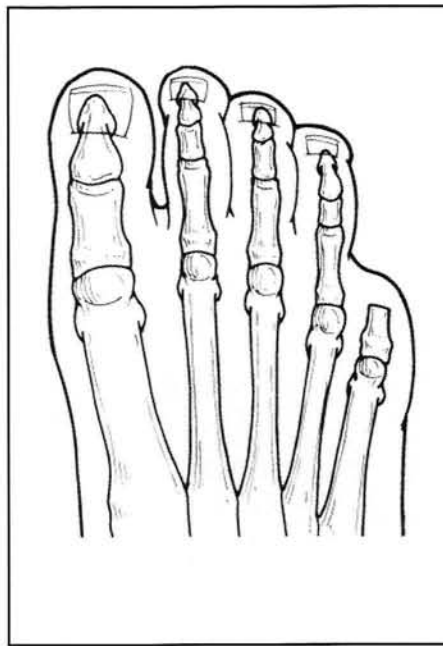


Figure 5. Partial digital osteotomy amputations

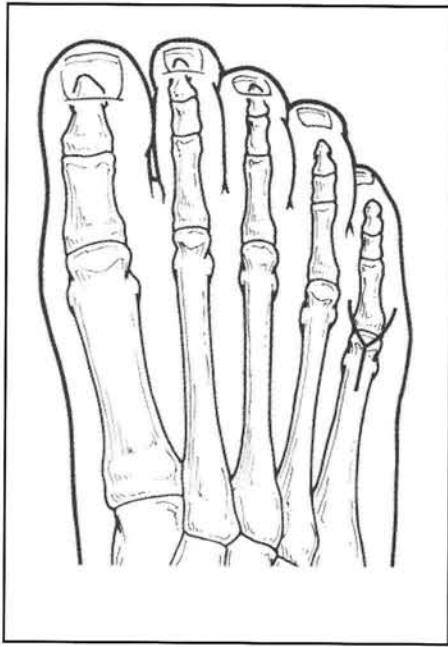


Figure 6. Complete digital dislocation amputation.

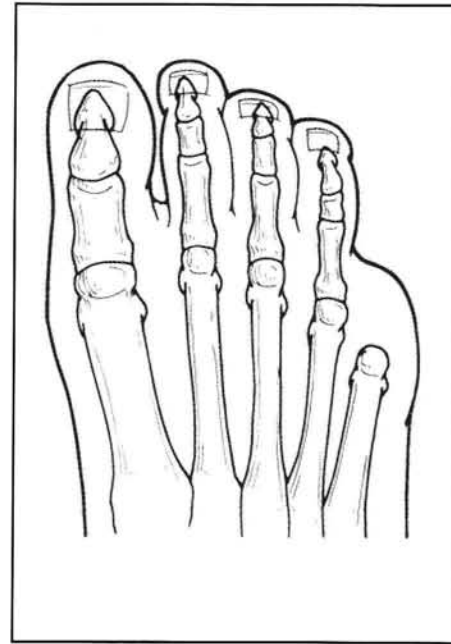


Figure 7. Complete digital dislocation amputation.

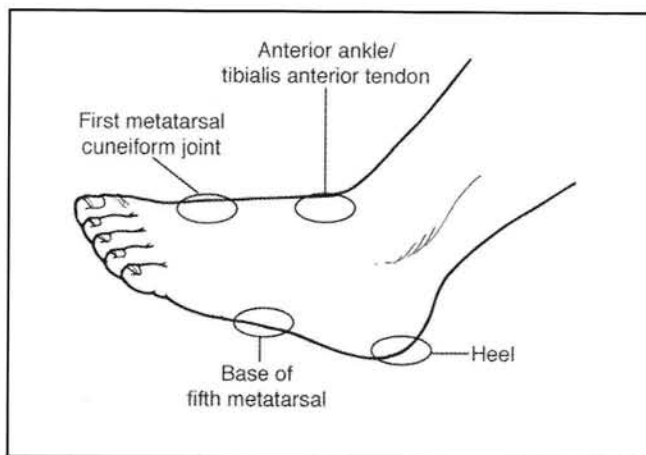


Figure 8. Avoid bony prominences during bandaging.

BIBLIOGRAPHY

- Bilk D, Selby JV, et al. Lower extremity amputations in people with diabetes; epidemiology and prevention. *Diabetes Care* 1990;13:513.
- Duggar, GE, et al. Time-Line for the diabetic foot. In: McGlamry ED, editor. Update 1987. Tucker (GA): Podiatry Institute Publishing; 1987.
- Fronek A, Coel M, Bernstein EF. The importance of combined multisegmental pressure and Doppler flow velocity studies in the diagnosis of peripheral arterial occlusive disease. *Surgery* 1978;84:840-7.
- Gavin LA. Perioperative management of the diabetic patient: endocrinology and metabolism *Clin North Am* 1992;21:457-75.
- Goldstein B, Citron D, Neshit C. Diabetic foot infections. *Diabetes Care* 1996;19:638-41.
- Griffiths D, Wieman, TJ. Meticulous attention to foot care improves the prognosis in diabetic ulceration of the foot. *Surgery Gyn Obst* 1992;174:49-51.
- Lance, B, Kirschenbaum S. Distal ischemia with digital gangrene secondary to Buerger's disease. *J Foot Surg* 1991;30:534-41.
- Lavery LA, Armstrong DO, Harkless LB: Classification of diabetic foot wounds. *J Foot Ankle Surg* 1996;35:528-31.
- Levin M. Foot lesions in patients with diabetes mellitus. *Chron Comp Diab* 1996;25:447-55.
- Levin ME, O'Neil LW: The diabetic foot: pathophysiology, evaluation, and treatment. In: Levin ME, editor. *The Diabetic Foot*. 4th edition. St. Louis (MO):CV Mosby; 1988. p 17.
- Pinzur MS, Gold J, Schwartz D, et al. Energy demands for walking in dysvascular amputees as related to the level of amputation. *Orthop* 1992;15:1033-7.
- Pinzur MS, Sage R, Abraham M, et al. Limb salvage in infected lower extremity gangrene. *Foot Ankle* 1988;8:212-5
- Rith-Najarian SJ, Stolusky T, Gohdes DM. Identifying diabetic patients at high risk for lower extremity amputation in a primary health care setting. *Diabetes Care* 1992; 15:1386-9.
- Schina MJ, Atnip RG, Healy D, Thiele B. Relative risks of limb revascularization and amputation in the modern era *Cardiovas Surg* 1994;2:754-9.
- Sizer JS, Wheelock FC. Digital amputations in diabetic patients. *Surgery* 1972;72:980-9.
- Uccioli L, Faglia E, Monticone G. Manufactured shoes in the prevention of diabetic foot ulcers *Diabetes Care* 1995;8:1376-8.
- Newman LG, Waller J, Palestro CJ, et al. Unsuspected osteomyelitis in diabetic foot ulcers. *JAMA* 1991;266:1246-51.
- Gibbons GW. the diabetic foot: amputations and drainage of infection. *J Vasc Surg* 1987;5:791-3.
- Wagner FW. Amputations of the foot and ankle. *Clin Orthop* 1977; 122:62-9.