

# THE PLANTAR SKIN AND SOFT TISSUES: Private Surgical Anatomy Review

*Thomas F. Smith, DPM*

Plantar surgical approaches are feared due to a concern for symptomatic scarring. There should be a respect for the plantar skin and associated subcutaneous tissues, but not fear. To avoid the possibility of a painful scar, it has been recommended that plantar incisions be placed on the non-weightbearing areas of the plantar skin. Incisions can likewise be placed plantarly in areas of potential non-weightbearing where a sesamoid or metatarsal is to be resected. A non-weightbearing area plantarly is in essence created from a weightbearing area. A more complete approach to the plantar scar is to orient the scar to not only consider the weightbearing status of the skin but neurovascular concerns, relaxed skin tension lines, and adequacy of exposure.<sup>1-3</sup>

The plantar skin and soft tissues are very specialized to provide the suppleness and padding needed for absorbing the forces of weightbearing. The plantar soft tissues possess the strength to resist ground reactive forces whether walking shod or unshod. Special techniques of surgical approach, repair, and postoperative management are warranted. Plantar approaches are very reasonable to consider, and do not necessarily result in pain or problems of scar hypertrophy. Callous formation or loss of padding and protective function are not common place following plantar incisions.<sup>4,7</sup>

Many surgical procedures require a plantar approach. Advances in nerve and other soft tissue and osseous techniques related to the foot open new vistas for reconstruction, if plantar approaches can be utilized with confidence. Plantar incisions should not be feared, but respected and judiciously utilized. A full understanding of topographical and local plantar anatomy is required. Special understanding of the neurovascular supply and associated subcutaneous tissues of the plantar foot are important. The plantar foot anatomy will be reviewed as an introduction to plantar foot surgery in general. Emphasis will be placed on the skin and dermal neurovascular supply as it impacts plantar incision placement considerations. The

specialized aspects of the subcutaneous tissues or fat pads will be reviewed with emphasis on exposure and visualization.

### THE SKIN

The histology of skin is important to review. Skin is composed of two basic layers, the epidermis on the surface and the deeper dermis. The epidermis is composed of the stratified squamous epithelium. The major cell of the epidermis is the keratinocyte. Other cells of the epidermis include melanocytes. Melanocytes are not numerous in plantar skin and little melanin pigment is formed. Plantar skin gets its characteristic yellow-golden color from the pigment carotene that exists in the subcutaneous fat, not the more translucent skin. The pink coloration of the plantar foot comes from the oxyhemoglobin in the highly vascular plantar dermis. Langerhans's cells in the epidermis play a role in immunologic function. Merkel's cells present in the plantar epidermis are thought to serve as mechanoreceptors.<sup>8</sup>

The dermis is primarily made up of collagen fibers and a protein matrix network that strengthens and binds the epidermis to the subcutaneous tissue. Cells in this layer are primarily fibroblasts. The outer papillary layer of the dermis is loosely arranged. The inner reticular layer is composed of denser connective tissue. There is a rich network of neurovascular and lymph structures within the dermis, feeding and nourishing the epidermis.

The dermis has two viscoelastic properties that can be utilized surgically to expand coverage of defects.<sup>9</sup> The first is termed creep. Creep represents the ability of skin stretched at a constant tension to expand in surface area. Creep can occur by two mechanisms. Biological creep is not the stretching of skin, but the expansion or growth of additional skin over slow insidious expanding forces. Biological creep occurs in pregnancy and subcutaneous tumor growth. Mechanical creep of the dermis is the actual stretching of skin over a much shorter time beyond the limits of its ability to

return to the original surface area, not the additional growth of skin.

The second viscoelastic property of the dermis is stress relaxation. Stress relaxation represents the property that as skin is stretched, the amount of tension required to maintain the stretch is decreased over a factor of time.

The skin of the sole of the foot is thickened for a protective function. It is thickest at the heel and lateral plantar margin of the foot. The plantar pedal skin is tighter and more fixed than the dorsal pedal skin that is more mobile. Surgical exposure plantarly may require longer or more varied shapes of incisions to provide a similar degree of exposure as shorter linear dorsal foot incisions. Accuracy of placement for specific areas of visualization on the plantar aspect of the foot is more critical and leaves less room for error. The plantar skin is much more resistant to abrasion. Plantar skin has a higher pain threshold to abrasion when compared with thigh skin. These two characteristics of elevated pain threshold and abrasion resistance attest to the ability of the plantar skin to avoid pain and injury in barefoot walking.<sup>10</sup>

The dermis contains numerous appendages that may have their origin in the subcutaneous tissue just beneath the dermis. The plantar skin does not contain hair follicles. Sebaceous gland function and excretions do not exist without hair follicles. Sweat function does exist on the plantar skin as eccrine

glands, but not apocrine glands.<sup>11</sup> The excretions to the sole are more watery than oily in character. The sweat function is controlled by the sympathetic nervous system as is plantar skin wrinkling in response to water exposure.

Numerous creases and line systems have been described within the skin. Dermographic patterns are finger and foot prints unique to each individual. Foot or finger prints have no surgical significance. Flexion skin creases or folds in plantar skin are numerous (Figure 1). Flexion creases plantarly represent the fixed and resilient nature of this skin, as well as the adaptable and mobile qualities of the plantar foot needed to permit joint motion. Flexion creases can hide scars when placed within their depths. This technique is most commonly exploited on the face not the plantar foot.

Cleavage lines, as described by Cox, run longitudinally in a proximal and distal orientation on the plantar foot.<sup>12</sup> There is a slight convex curvature on the fibular side and a circumferential orientation about the posterior plantar heel area (Figure 2). Cleavage lines were based on studies originally done by Langer. Cleavage lines were determined by skin hole orientation following awl punctures in fresh cadaver skin. Langer's lines generally tend to follow in the direction of muscle pull throughout the body, cleavage lines do not.<sup>13</sup> Cox's and Langer's lines vary in orientation on the foot dorsally, but not plantarly.

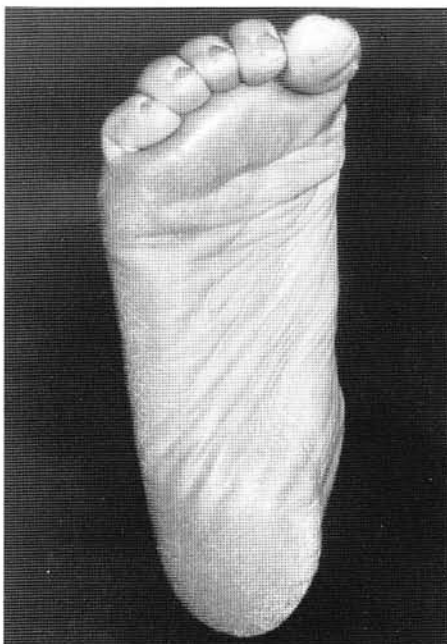

Figure 1. Flexion creases on the plantar aspect of the foot.

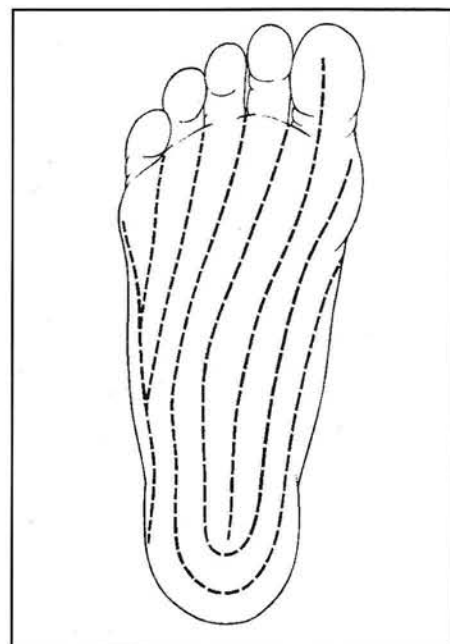


Figure 2. Cleavage lines on the plantar aspect of the foot.

Relaxed skin tension lines (RSTL) were described by Borges and Alexander.<sup>14</sup> They determined the tension on the skin with respect to elasticity of the skin, stretch of the skin as related to muscle pull, and local anatomy considerations. These lines have proven to be more effective in determining orientation of scars to prevent hypertrophy. Incisions parallel to RSTL do not gap as much as those perpendicular to RSTL. Incisions parallel to RSTL have much less tension on them after closure. The tension demonstrated by RSTL is constant, whether the wound is dressed, placed in a cast, or supported by suture. Scars are much less likely to hypertrophy when parallel to RSTL due to the lessened degree of tension on the wound. RSTL run transversely across the plantar aspect of the foot (Figure 3).

RSTL vary from cleavage lines plantarly by 90 degrees. RSTL run transversely whereas cleavage lines run longitudinally on the plantar aspect of the foot. Incisions, however, in either line system of the plantar foot are said to show little tendency to hypertrophy.

The incidence of hypertrophic scars or keloids on the plantar skin is minimal, whether RSTL or cleavage lines are followed. Scars in either direction on the plantar skin whether transverse or longitudinal in orientation show little signs of hypertrophy.<sup>4</sup> Plantar scars can still be sensitive, have keratotic thickening, or have atrophy of the

subcutaneous padding and be problematic, yet not be considered hypertrophic. Perhaps this tendency of plantar scars not to hypertrophy is a function of the rigid nature of the plantar skin that splints and protects the scar, as well as the pressure of weight bearing that is therapeutic in adding compression forces to the plantar scar.

### BLOOD SUPPLY

As a general rule, one thinks of arterial outflow and venous return in a proximal and distal orientation (Figure 4). This is accurate in most areas of the body. The deep arterial flow to the plantar aspect of the foot follows this orientation from the posterior tibial artery to the medial and lateral plantar arteries distally. The medial and lateral plantar arteries continue distally within the central compartment of the sole of the foot deep to the plantar fascia to the digits.

The blood flow through the plantar skin within the subdermal plexus follows a different orientation. The arterial flow to the skin and related soft tissues of the sole of the foot is rich and plentiful. The vessels reach the skin through a perforating system from principally the larger lateral plantar artery and the smaller medial plantar artery deep in the central compartment of the foot. The vessels must perforate the deep fascia towards the plantar skin (Figure 5). This perforating system occurs along either side of

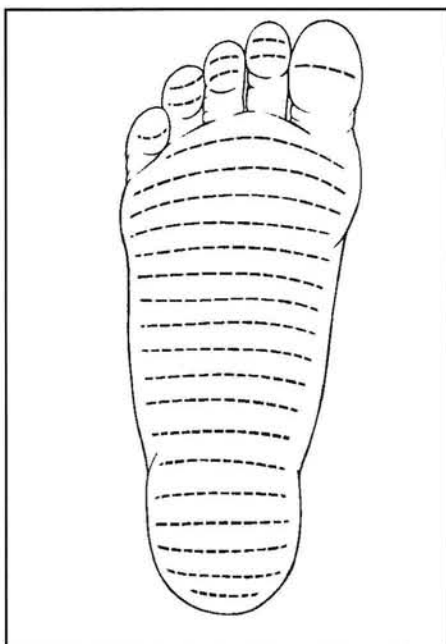


Figure 3. RSTL on the plantar aspect of the foot.

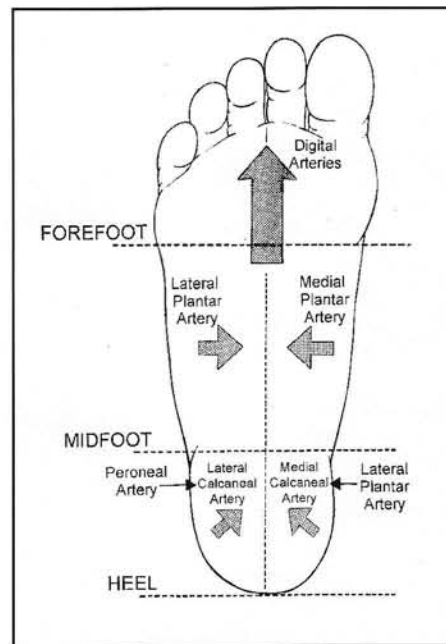


Figure 4. Arterial blood flow to the plantar aspect of the foot.

the strong central portion of the plantar fascia through the medial and lateral plantar sulci.<sup>15</sup>

Curtin has shown through infrared photography that the distribution of vessels in the plantar skin follows a more transverse orientation, not longitudinal.<sup>16</sup> The flow originates laterally and medially and proceeds toward the plantar central aspect of the sole of the foot. This is a critical concern when designing plantar surgical approaches or assessing the viability of plantar skin after lacerations. Parallel plantar incisions or longitudinally-oriented lacerations could result in a compromise to the tissue between them (Figure 6). Parallel incisions transversely oriented would not be as prone to avascularity. Large medially or laterally based skin flaps that cross into and transect the blood flow from the opposite direction can result in significant tip necrosis (Figure 7). Skin flap and plastic surgical techniques on the plantar skin must respect the deep and superficial variations in arterial blood flow. Viability of the skin would outweigh concerns of scarring, given the choice of surgical wound orientation options.

The deep venous flow runs from distal to proximal through the posterior tibial veins (Figure 8). The subdermal network of veins from the skin and related soft tissues flows outward from the central plantar foot in a medial and lateral direction. The multitude of superficial veins about the periphery of the foot where the plantar skin joins the

dorsal skin attests to the abundance of the plantar skin blood supply. Lacerations or incisions in this marginal skin may require substantial hemostasis. These superficial veins then drain dorsally into the large saphenous system medially, and the small saphenous system laterally.

## NERVES

The nerves to the plantar skin and related soft tissues reach the sole of the foot in the midfoot region much in the same manner as the arterial system. The major plantar nerves of the midfoot and forefoot are the large medial plantar nerve and smaller lateral plantar nerve. These nerves course deep to the plantar fascia within the central compartment of the foot. The cutaneous nerve extensions pierce the deep fascia along the medial and lateral margins of the plantar fascia within the medial and lateral sulci in the midfoot region.<sup>16</sup> The cutaneous nerves branch transversely within the neurovascular arcade to innervate the skin.

The plantar heel skin nerve supply originates from two sources. The sural nerve innervates the lateral heel area plantarly. The medial heel is innervated by the medial calcaneal nerve as a branch of the tibial nerve. The cutaneous perforating branches to the plantar heel are variable in presentation, and difficult to visualize and identify.

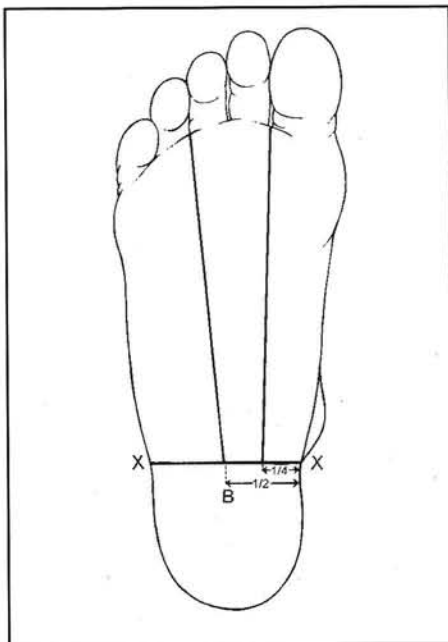


Figure 5. Topographical identification of the medial and lateral sulci on the plantar aspect of the foot.

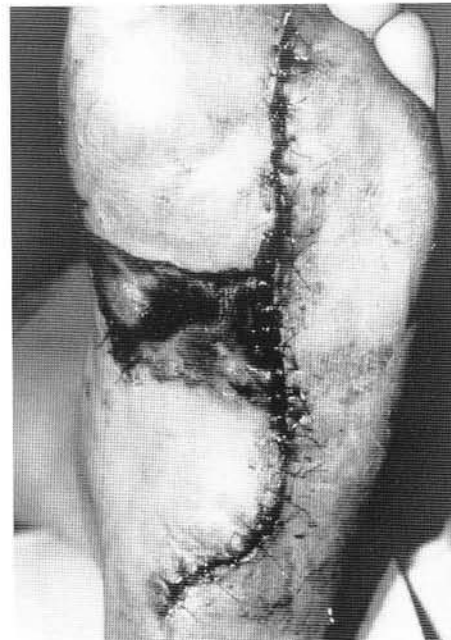


Figure 6. Skin necrosis between two parallel plantar incisions.

The ball of the foot and digits are supplied primarily by the medial, and to a lesser degree, the lateral plantar nerve. These two nerves overlap at the third intermetatarsal space where both send a branch that supplies the lateral aspect of the third toe and medial aspect of the fourth toe, and is involved in the classic Morton's neuroma. These major plantar nerves are axon extensions of cells whose cell body and nucleus lie in the sensory dorsal root ganglion of the spine. The nerve root levels of L5 and S1 are the spinal origin of the nerves to the plantar aspect of the foot.

The plantar digital nerves are protected from the effects of movement and weight bearing by the fat bodies plantarly. The fat bodies are accumulations of adipose tissue enclosed by fibrous fascial septa between the metatarsal heads. As the digital nerves progress beyond the metatarsal heads, they become rather superficial in the digital sulcus area plantarly. Surgical approaches to the digital nerves at the non-weight bearing sulcus area require less exposure than more proximally at the metatarsal head level through the fat bodies. The cutaneous nerves to the ball area of the foot exit and perforate towards the skin at various levels along the course of the digital nerves. The digital nerves end in the cutaneous fat of the tufts of the toes.

The dermatomal distribution of innervation to the sole of the foot can be viewed as spinal or

peripheral nerves. Careful study and memorization of these dermatomal maps is required. Some variability exists and the distribution patterns are not absolute. Complicating the situation is the finding that texts and articles represent these dermatomal distribution maps differently. Representative dermatomal maps are provided here for review, study, and comparison (Figures 9-11).

## SUBCUTANEOUS TISSUES

The plantar subcutaneous tissues are specifically adapted, both structurally and biochemically, to act as a cushion for weight bearing. The subcutaneous tissues can be divided into three distinct and unique areas. These areas include the heel, arch and forefoot subcutaneous tissues. A closed-cell structure of the adipose tissue in the heel and forefoot provides for weight-bearing force transmission and absorption. As an example, normal heel fat pads tend to broadly disperse weight-bearing forces. Atrophic heel fat pads tend to have more concentrated peak pressure distribution.<sup>17</sup> The septal walls of atrophic heels tend to be fragmented and wider than normal with fibrosis. The structure of fat cells is similar in normal and atrophic heels, but a smaller mean cell area has been noted.<sup>18</sup> Higher percentages of unsaturated fatty acids and lower percentages of saturated fatty acids are found in normal heel fat than

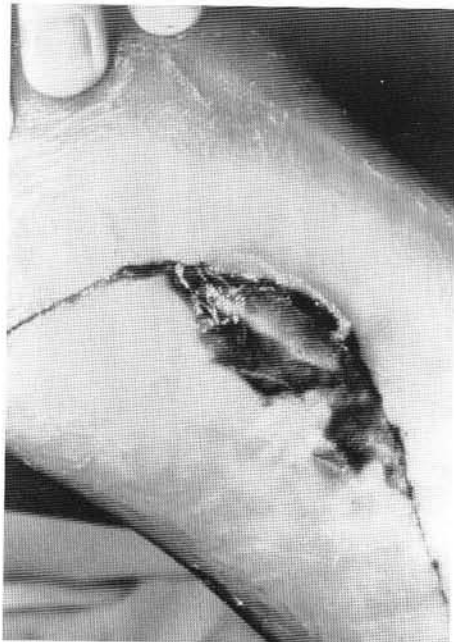


Figure 7. Skin necrosis at the distal tip of the skin flap that extended into and transected blood flow from the opposite side of the foot.

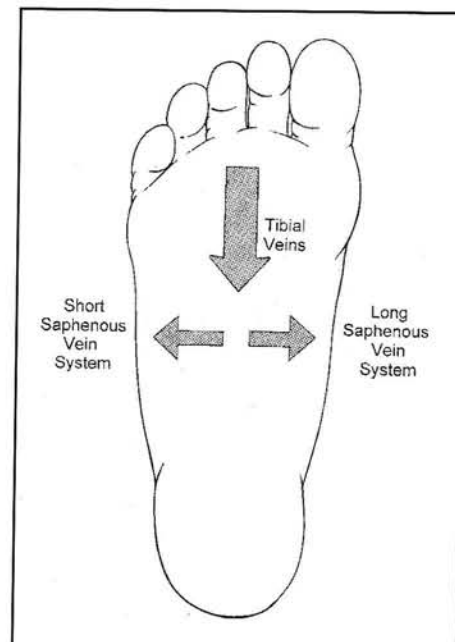


Figure 8. Venous blood flow from the plantar aspect of the foot.

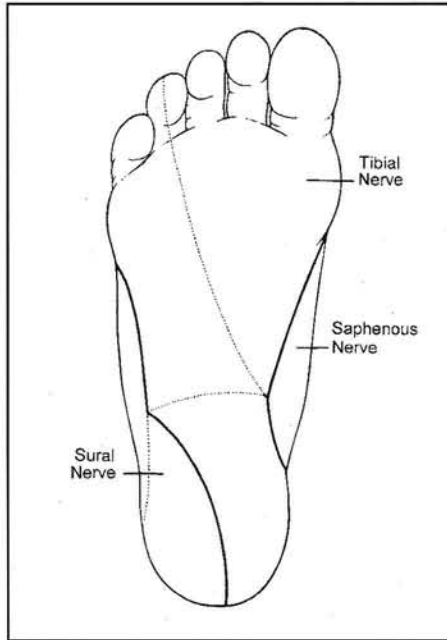


Figure 9. Large peripheral nerve innervation to the plantar foot.

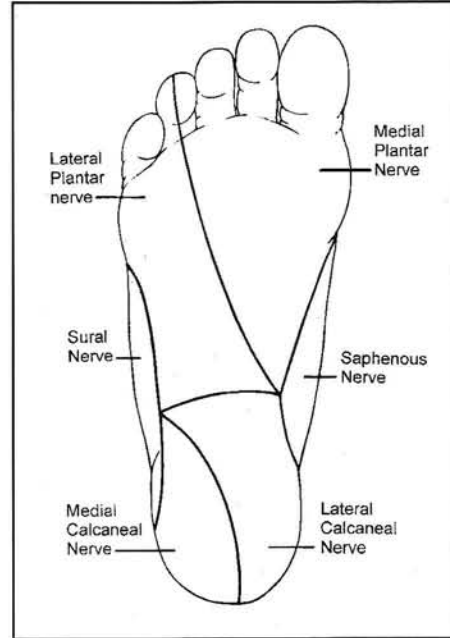


Figure 10. Small peripheral nerve innervation to the plantar foot.

other bodily fatty tissues. The increased unsaturated fatty acid ratio may decrease triglyceride viscosity and enhance biomechanical efficiency. No difference in this fatty acid ratio is found when comparing normal or atrophic heel fat pads.<sup>19</sup>

The thickness of the subcutaneous tissue of the heel can be 2 cm. Fibrous septa are oriented in a spiral fashion through the subcutaneous tissue to hold the heel fat about the calcaneus in chambers plantarily.<sup>20</sup> The septa form a precise system of chambers that retains the adipose tissue (Figure 12). The hydrodynamics of these chambers provide for the effective absorption and distribution of body weight through the weight-bearing process. The most plantar and superficial spiral septal system originates medially on the calcaneus. The septa spiral posterior and lateral. A second more proximal spiraling system of septa, originates on the lateral calcaneus. These septa spiral posteriorly, but end more medial-ward in the subcutaneous tissues. A third converging septal system runs from the anterior calcaneus and curves lateral and forward. The more anterior septa on the heel run anterior towards the plantar skin. The more posterior septa run relatively posterior as they course towards the plantar skin. A complex of multiple smaller chambers is created, which gives the strength to the overall system to

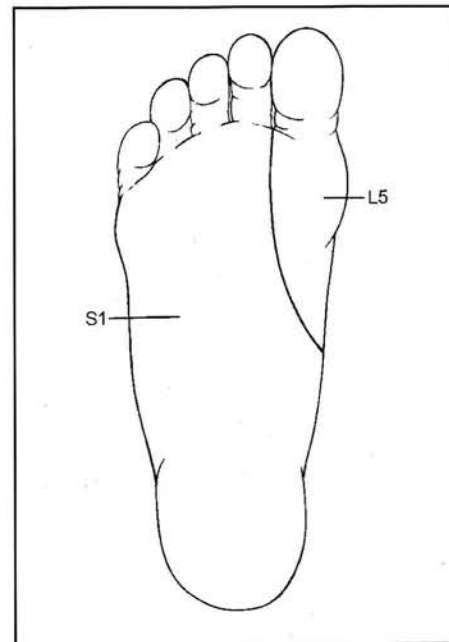


Figure 11. Spinal nerve root innervation to the plantar foot.

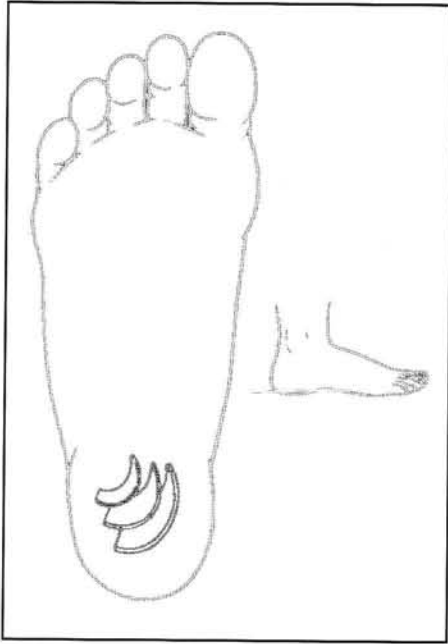


Figure 12A. Diagrammatic representation of the primary fibrous septal system of the heel subcutaneous tissue layer that originates medially on the calcaneus and spirals posterior and lateral.

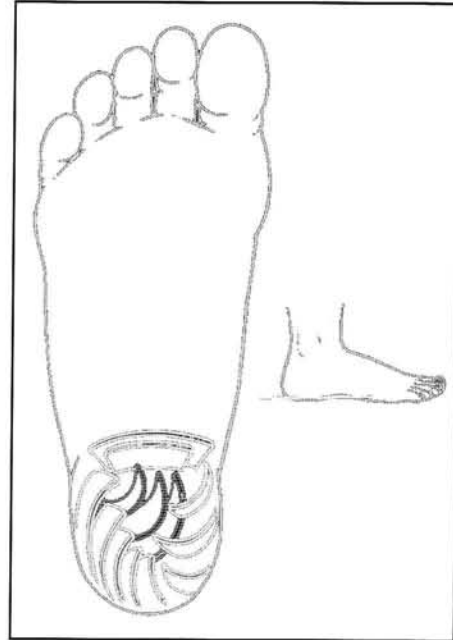


Figure 12B. The secondary spiral septal system originates more lateral and spirals posterior and ends more medial.

provide resiliency and shock absorption. It is difficult whether the plantar heel incision is transverse or longitudinal, not to violate this septal system. A rather large subcalcaneal bursa is present just beneath the weight-bearing calcaneus to provide additional padding.

The non-weight-bearing arch subcutaneous tissue varies little from other areas of the body. Linear vertical bands bind the fat loosely. The structure is not nearly as formal as the heel or ball area of the plantar foot (Figure 13). The subcutaneous tissue in the arch area of the plantar foot is very thin. Scarring from the skin can readily form adhesions to the deeper plantar fascia. Plastic surgical techniques that involve full-thickness transfer of skin and subcutaneous tissue from the arch area to the weight-bearing areas may not provide adequate padding against weight bearing.

The plantar subcutaneous tissue of the ball of the foot is retained and maintained by a complex system of intersecting ligaments and fascial bands. The plantar fascia forms bands that are longitudinally oriented. The more transverse bands are called transverse fasciculi proximal to the metatarsal heads, and natatory ligaments more distally. These longitudinal and transverse fibrous structures define adipose deposits termed fat bodies

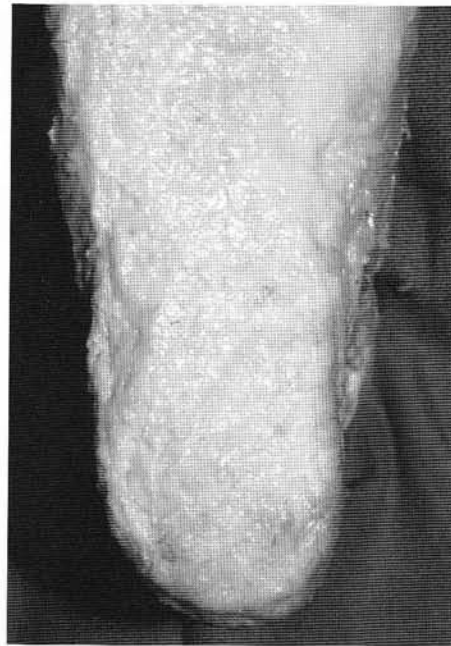

Figure 12C. Cadaveric view of the superficial layer of the heel subcutaneous tissues just below the dermis. The septal system lies deep to this surface.

that protect and cushion the neurovascular structures between the metatarsals. The subcutaneous fat beneath the metatarsal heads is termed the submetatarsal cushion (Figure 14). The submetatarsal cushion is confined medially and laterally between two longitudinal fascial bands called the vertical fibers. The vertical fibers arise from the sides of the plantar plate and flexor sheath. They course plantarly from either side of the metatarsal head. The vertical fibers form an arching pattern beneath the metatarsal head to encase the fatty tissue of the metatarsal cushion. Longitudinal incisions in the plantar forefoot tend not to violate this septal system. Longitudinal incisions help to avoid the weight-bearing areas and are parallel to the cleavage lines, but perpendicular to the RSTL.

### CONCLUSION

Plantar incisions are a safe method of accessing the foot for surgical procedures. The specialized plantar soft tissue and skin anatomy aids in providing strength to resist weight bearing, yet cushioning for weight-bearing loads. The plantar skin and soft tissue readily serves this function. Surgery through this area requires an understanding of anatomy and function to yield the best results with the fewest complications.

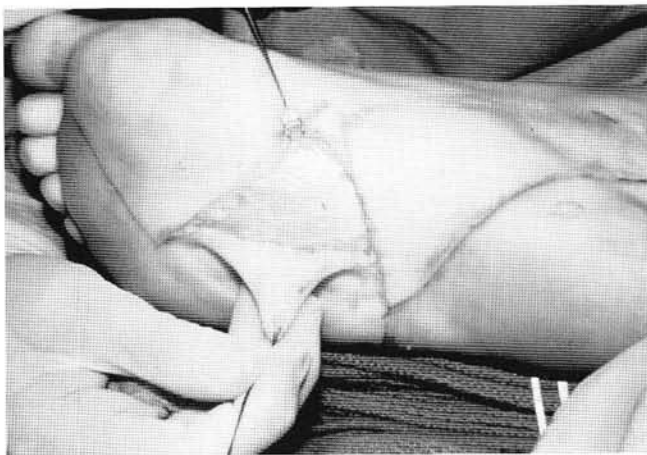

Figure 13. A. Surgical exposure of the plantar fascia in the arch area with the subcutaneous tissue layer retained to the dermis for vascular preservation of the skin flaps.

### REFERENCES

1. Stapp MD. Plantar skin incisions: an overview. In Vickers NS, editor. *Reconstructive Surgery of the Foot and Leg, Update '96* Tucker (GA): Podiatry Institute; 1996. p. 108-12.
2. Mahan KT. Plantar fibromatosis: surgical considerations. In McGlamry ED, editor. *Reconstructive Surgery of the Foot and Leg, 1986*. Tucker (GA): Doctors Hospital Podiatric Education and Research Institute; 1986. p. 161-4.
3. Mahan KT. Plastic surgery and skin grafting. In McGlamry ED, Banks AS, Downey MS, editors. *Comprehensive Textbook of Foot Surgery* 2nd ed. Baltimore (MD): Williams & Wilkins; 1992:1256-96.
4. Richardson EG, Brotzman SB, Graves SC. The plantar incision for procedures involving the forefoot. *J Bone Joint Surg Am* 1993;75:726-31.
5. Lewis G, Gatti A, Barry L, et al. The plantar approach to heel surgery: a retrospective study. *J Foot Surg* 1991;30:542-6.
6. Satterfield VK, Jolly GP. A new method of excision of painful plantar forefoot lesions using a rotation advancement flap. *J Foot Ankle Surg* 1994;33:129-34.
7. Perelman GK, Figura MA, Sandberg NS. The medial instep plantar fasciotomy. *J Foot Ankle Surg* 1995;34:447-57.
8. Loveland LJ, McClure LP, Page JC, et al. Living skin equivalents. *Lower Extremity* 1996;3:231-6.
9. Armstrong DG, Sorenson JC, Bushman TR. Exploiting the viscoelastic properties of pedal skin with the sure closure skin stretching device. *J Foot Ankle Surg* 1995;34:247-53.
10. Robbins S, Gouw GJ, McClaran J, et al. Protective sensation of the plantar aspect of the foot. *Foot Ankle* 1993;14:347-57.
11. Bates B. *A guide to Physical Examination and History Taking* Fifth ed. Philadelphia (PA): JB Lippincott; 1991. p. 140.
12. Cox HT. The cleavage lines of the skin. *British J Surg* 1988;9:34-9.
13. Langer K. Ueber die Spaltbarkeit der Cutis, Sitzunop.d., K Akad.d.Wissensch. Math-naturw CL 43:23, 1861, Cited by Kraissl C: The selection of appropriate lines for elective surgical incisions. *Plast Reconstr Surg* 1951;8:1-28.
14. Borges AF, Alexander JE. Relaxed skin tension lines, z-plasties on scars and fusiform excision of lesions. *Br J Plast Surg* 1962;15:242-54.

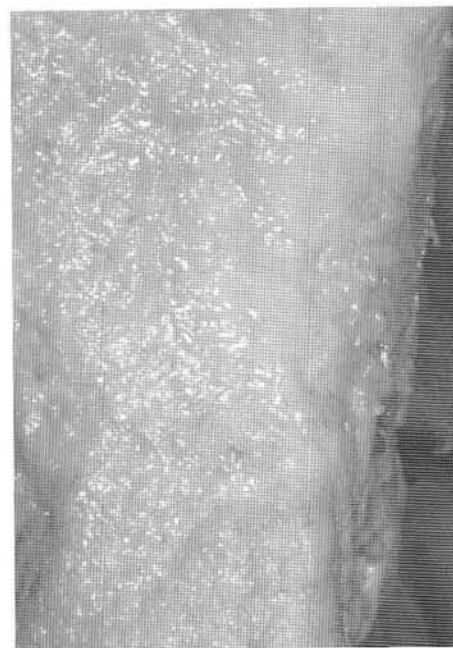

Figure 13B. Cadaveric view of the superficial layer of the arch subcutaneous tissues just below the dermis. The subcutaneous tissues are fairly contiguous throughout in the arch area of the foot.



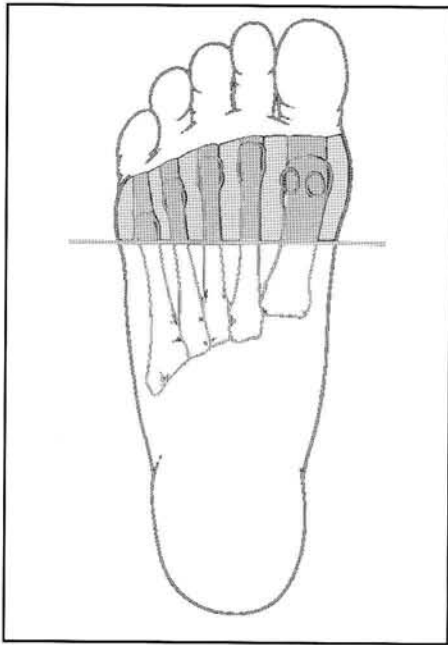


Figure 14A. Diagrammatic representation of the subcutaneous tissues of the plantar forefoot in the transverse plane. Note the segmented variation in tissue character from beneath the metatarsal heads and the fat pad or submetatarsal cushion to between the metatarsal heads and the fat bodies.

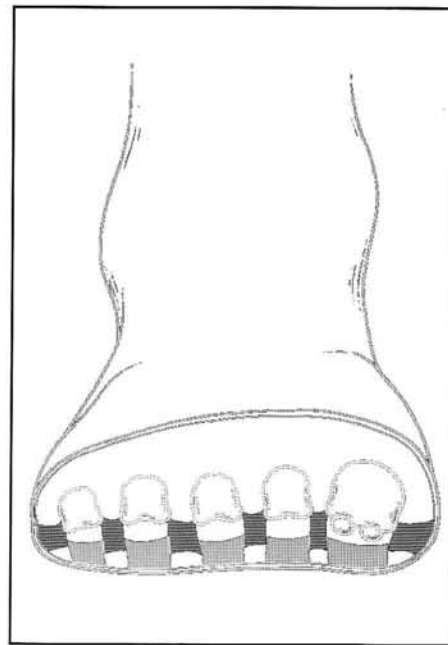


Figure 14B. Segmented look in the frontal plane.

15. Curtin JW. Fibromatosis of the plantar fascia. *J Bone Joint Surg Am* 1965;47:1605-8.
16. Sarrafian SK: *Anatomy of the Foot and Ankle* Philadelphia: JB Lippincott;1983.
17. Jahss MH, Kummer F, Michelson JD. Investigations into the fat pads of the sole of the foot: heel pressure studies. *Foot Ankle* 1992;13:227-32.
18. Buschmann WR, Jahss MH, Kummer F, et al. Histology and histomorphometric analysis of the normal and atrophic heel fat pad. *Foot Ankle* 1995;16:254-8.
19. Buschmann WR, Hudgins LC, Kummer F, et al. Fatty acid composition of normal and atrophied heel fat pad. *Foot Ankle* 1993;14:389-94.
20. Blechschmidt E. Die Architecktur des Fersenpolsters. In Gegenbaurs Morphologisches Jahrbuch, Leipzig, Akad Verlag MBH, 1933. p. 65-6.

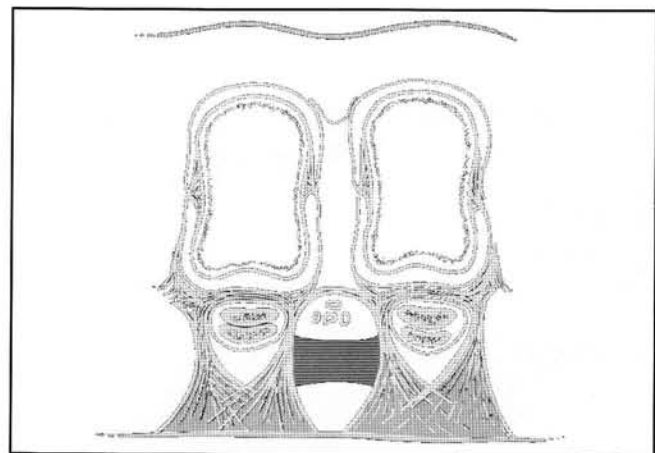


Figure 14C. More anatomic look in the frontal plane with the deeper fat body in the intermetatarsal spaces and the more superficial fat pad beneath the metatarsal heads.