CHAPTER **48**

STRESS FRACTURES OF THE LOWER EXTREMITY

Charles F. Peebles, DPM

Stress fractures are a common part of the lower extremity specialists' practice. Some symptoms are easily identified as consistent with stress fractures and the treatment progresses without much difficulty. Certain patient populations have higher incidences of stress injuries and must be identified to prevent further injury or complete fracture requiring surgery. The earlier diagnosis results in limitation of complications and allows the patient to return to their desired level of function. Stress fractures can occur in any bone but are more common in some, and these will be detailed in terms of diagnosis and treatment considerations.

PATHOMECHANICS OF STRESS FRACTURES

Stress fractures are commonly grouped into two different categories based on their underlying etiologies: insufficiency fractures and fatigue fractures. Both are the result of stress on the bone but can be of varying loads. Insufficiency fractures result when the bone is weakened by a direct or systemic process that leads to bone loss and subsequent fracture with normal weightbearing load. Lack of normal weightbearing after an illness or treatment for an injury can result in disuse atrophy of bone and place the patient at higher risk for fracture during the rehabilitation stage. Systemic processes such as rheumatoid arthritis, prolonged steroid use, osteoporosis, hyperparathyroidism, osteomalacia, and a number of hormonal deficiencies may also result in weakened bone properties.

Fatigue fractures are usually a result of increased stress applied to normal bone. This commonly occurs in athletes and military recruits but can occur in any population with a change in activity. The increased stress is usually applied with increased intensity over a short period of time. The body's reparative process is unable to keep up with the stress being applied and results in a breakdown in the osseous structures.

Bone requires stress for normal function and normal remodeling of the bone to maintain appropriate bone health. Stress on the body requires compensatory changes to occur in bones, muscles and tendinous structures and result in either remodeling or injury if the body does not respond rapidly enough. Bone remodels through a process of osteoclastic breakdown of bone followed by osteoblastic ingrowth to increase stability and strength. Microfractures develop in this process and if not kept in relative balance the sum of the microfractures at the site may result in a stress fracture. The pathologic process described by Johnson is a variation of the normal remodeling process of bone in response to stress, as described by Wolf's law.[1] The dynamic response of bone to stress results in the strengthening of osseous structures, but the stress can occur at too high and too frequent a rate, resulting in failure of the bone. The electropositive potential produced at the tension side of the bone with increased stress activates osteoclasts, resulting in a breakdown of bone. The histiogenic properties of stress fractures consist of an initial osteoclastic period that continues for approximately one week followed by increased osteoblastic activity and the periosteal callus formation. This creates a stress reaction of bone with no cortical fracture present. The continuation of stressful activity creates a defect in the cortex at approximately three weeks, with maximum callus formation present at six weeks corresponding to the approximate delay in radiographic findings (Figure 1).

Histology of Stress Fractures

Event	Time	X-ray	Bone Scan
Stress Initiated / Osteoclastic Activity		(−)	(−/+)
Stress Reaction / Periosteal Callus	1 week	(−)	(+)
Stress Fracture / Cortical Defect	3 weeks	(−)	(+)
Maximum Callus Formation	6 weeks	(+)	(+)

Adapted from Johnson LC, et al. "Histogenesis of Stress Fractures". *J Bone Joint Surg*. 1963.

Figure 1. Histiogenesis of Stress Fractures

The three week period of stress fracture development corresponds with Gilbert's findings that military recruits with stress fractures most commonly develop symptoms in the second and third weeks after commencing recruit activities.[2] The delay in diagnosis occurs due to the delay in the ability to visualize callus on the plain film radiographs. The diagnosis is often made in the later stages of the injury thereby placing the patient at a significantly increased risk of sustaining a complete fracture. This same process has an effect in insufficiency fractures as the osseous remodeling process is unable to maintain pace with the normal stresses applied to bone and microfractures develop and summate into stress fractures.

Muscle function plays an important role in this process. Increased muscle strength results in an increased pull on the bone subsequently developing weakness at the maximum site of stress and subsequent fracture development. Muscle weakness of fatigue requires the osseous structures to maintain more of the load and may also result in abnormal stress on the musculoskeletal system. The use of improper equipment or shoes that no longer provide adequate functional support can lead to fractures through both osseous overload and muscle fatigue.

DIAGNOSIS

The key to diagnosis of stress fractures is to have a high index of suspicion and to rule out the fracture prior to leading toward other more benign diagnosis. Pain is usually the biggest indicator with stress fractures and the patient will usually give you all the information necessary to make the diagnosis prior to any adjunctive radiographic studies. Early identification is essential in preventing stress fractures from going undiagnosed resulting in delay in treatment and worsening of the injury. Pain is likely to increase with increased activity and is likely to linger even after discontinuation of activity. The patient can commonly pinpoint the region of pain and allows the direct clinical evaluation to pinpoint the region of maximum tenderness. Common symptoms include swelling, pain at a specific site, and pain that progressively worsens throughout the day, evening or activity.

Clinical exam typically results in identification of localized edema and pinpoint tenderness. Certain types of muscle testing and joint positioning can assist in better identifying stress fractures and ruling out other pathology. Gait evaluation will usually result in an apropulsive gait guarding against full weightbearing on the effected extremity. Unilateral weightbearing and direct stressing of the bone will likely result in severe pain limiting any weight-bearing strain.

Adjunctive therapy and examination can also clue the physician as to the exact etiology of the injury. Mechanical vibration with a tuning fork over the affected bone or the use of ultrasound modalities will likely increase pain and allow more ready identification of the injury.

IMAGING STUDIES

The clinical exam and history are usually the best tools used in identifying as stress fracture. Imaging studies are used to confirm a diagnosis and help to determine the specifics of treatment. Depending on radiographic studies may lead to a number of false negatives that will result in a delay in treatment. Plain film radiographs will have a delay until a positive result is identified. This delay is dependent on time of injury or pain onset, the bone involved and the speed of the reparative process. Cancellous bone which is found in shorter bones and in metaphyseal and epiphyseal regions is not as clearly identified as is typically seen radiographically as a sclerotic line. Cortical bone that is more prevalent in the diaphyseal regions of long bones is often seen earlier as a periosteal callus which we typically visualize on lesser metatarsal stress fractures. The visualization of the radiographic evidence of a stress fracture may be delayed from 10 days to 10 weeks depending on the interval from diagnosis to treatment and the location of the fracture. Serial radiographs are essential not only for diagnosis but also to monitor for appropriate alignment and healing.

Due to the inconsistent nature of plain film radiographs, other imaging studies may be utilized for a more rapid diagnosis and to expedite therapy. Bone scintigraphy is commonly utilized, as it identifies regions of increased osseous activity in the remodeling process. These examinations become positive within 24 hours and therefore allow for much more rapid diagnosis. These exams also assist in ruling out other malignancies if a full body scan is viewed and any suspicion of malignancy and pathologic fracture is identified. The use of

computed tomography and magnetic resonance imaging is being used much more commonly as a noninvasive examination that allows for direct evaluation of the bone cortex and internal marrow, respectively. These are especially useful in the diagnosis of short bone fractures such as the calcaneus, navicular and other tarsal bones, sesamoids and the tibia.

SITES OF LOWER EXTREMITY STRESS FRACTURES

Sesamoids

Stress fractures of the sesamoids can be a very disabling injury. They are commonly caused by the same forces that cause acute sesamoidal fractures yet with more repetition. Increased weightbearing on the forefoot produces increased forces traumatizing the cancellous nature of these and resulting in potential fracture or collapse. These fractures are common in dancers and those who maintain toe weight bearing such as painters who are on the rungs of ladders or with their feet in a maximally dorsiflexed attitude. Patients typically ignore these injuries in the early stages and therefore early diagnosis is key to preventing a delayed or nonunion in this region (Figures 2, 3).

Edema with pinpoint tenderness with dorsiflexion of the first metatarsophalangel joint is pathomnemonic of this type of fracture. Plain film radiographs will likely not identify a fracture until the bone has collapsed or fragmented. Bone scans will be indeterminate at best due to the decreased vascularity of these bones. MRI is helpful in the early stages and the use of CT scans can identify the cortical breaks that may occur as the stress fracture progresses.

Treatment is determined based on when the stress fracture is identified. It may range from simply decreasing the stressful activity and using a stiff soled shoe, to the use of a walking cast to limit dorsiflexion and immobilize the fracture to allow complete healing. Biomechanical etiologies should be evaluated to allow the patient to progress back to activities after healing of the fracture. In the event that complete collapse occurs or in the development of nonunion the surgical excision of the sesamoid or a portion of it may become necessary with attempts made to preserve the functional structure about the first metatarsophalangeal joint to prevent malalignment of the joint. Aggressive early intervention can successfully treat sesamoid stress fractures conservatively and limit the need for surgical excision and the complications that may arise from this.

Figure 2. Tibial sesamoid stress fracture due to delayed diagnosis.

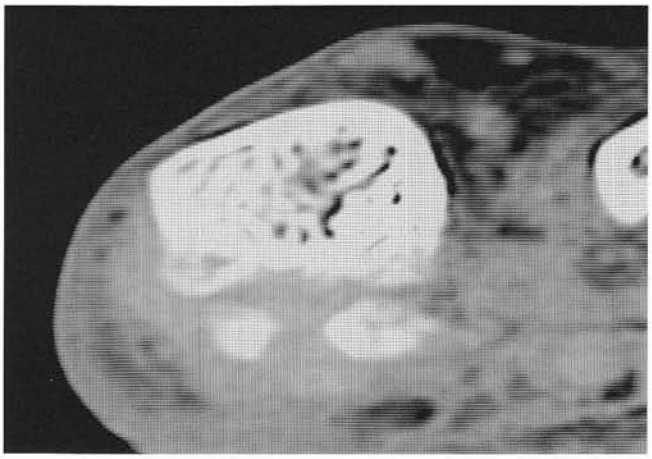

Figure 3. CT of fibular sesamoid stress fracture with initiation of callus formation.

Metatarsals

Stress fractures in the metatarsals are the most common stress fracture treated. The repetitive trauma induced throughout the forefoot with exercise and with improper support leads to strain throughout the longitudinally directed bones creating a stress with tension plantarly and compression dorsally. This is commonly evidenced as patients begin an exercise routine or increase activity and develop pain that progresses relatively rapidly. The pain is typically accompanied by a patient's complaint that shoes no longer fit due to swelling in the forefoot and limitation of normal activity.

Significant edema in the forefoot is usually indicative of a stress fracture of one or more of the metatarsals and palpation will reveal the pinpoint tenderness associated with a stress fracture. The use of a tuning fork placed adjacent to the fracture will usually localize pain to the site of the fracture.

Plain film radiographs will likely show evidence of callous formation and secondary intention bone healing within 10-14 days of the onset of symptoms. If a more definitive diagnosis is necessary more rapidly due to an upcoming event a bone scan will positively reflect a fracture within 1-2 days and will remain positive for approximately one year as the fracture site remodels (Figure 4).

The location of the fracture will determine the specific treatment. Distal stress fractures of the metatarsal neck are commonly treated by limitation of activity and stabilization with either a stiff soled surgical shoe or use of a removable walking cast. Stress fractures in the proximal two-thirds of metatarsal 1,2,3,4 are commonly treated with a weightbearing cast depending on bone health and the integrity of the cortical surfaces. Fractures involving the fifth metatarsal base necessitate non-weightbearing for a period of 4-6 weeks followed by protective weightbearing with a removable cast to allow for mobilization and progressive return to function (Figure 5). Serial radiographs should be monitored to insure adequate healing and more aggressive immobilization or potential surgical intervention may become necessary. The use of external fixation may allow for more aggressive weightbearing should surgical intervention become necessary. If fractures are not identified early, the weightbearing strain may produce displacement or complete fracture. These situations may require surgical intervention. Sagital plane displacement may produce adjacent stress fractures where transverse plane deviations are better tolerated. Metatarsal stress fractures usually present early in the course of the injury and aggressive treatment should allow for uneventful healing and normal return to function.

Navicular and Tarsal Stress Fractures

The most common stress fracture in the midtarsal region occurs in the navicular bone. The cuneiforms and cuboid can also have increased stress with certain types of activities. The navicular has increased stress due to the insertion of posterior

Figure 4. Metatarsal stress fractures in patient on chronic steroids for rheumatoid arthritis. Third metatarsal stress fracture developed due to dorsiflexed position of healed second metatarsal stress fracture.

Figure 5. Fifth metatarsal stress fracture at the proximal diaphyseal/metaphyseal junction.

tibial tendon and the driving force of the talus that increases the force and stress on this bone making it prone to stress fractures. It is often misdiagnosed as plantar fasciitis, posterior tibial tendonitis or partial tear, or anterior tibial tendonitis.

Edema in the medial midfoot and pain that may occur with and without muscle testing of the posterior tibial tendon are likely related to a navicular stress fracture. Compression of the talon-avicular joint will strain the navicular as will single heel rise tests and increase the probability of a stress fracture especially in light of pain with palpation at the dorsal and medial navicular. The majority of fractures are in the central third of the bone and as such have a point of maximum tenderness dorsally.

Due to the short nature of this predominantly cancellous bone, plain film radiographs will not become positive as quickly as with metatarsal stress fractures. Plain film radiographs will reveal the fracture with a sclerotic line at a later stage of the injury. Bone scan will show the fracture very rapidly but will not give an indication of the extent of joint involvement. CT scans will show any cortical breaks and are very beneficial in the event that surgical intervention is warranted (Figure 6). MRI is an excellent imaging modality for this injury due to the ease of early diagnosis and to allow for evaluation of the posterior tibial tendon at the same time due to the common confusion with insertional tendonitis.

Rapid diagnosis of midfoot stress fractures is key in appropriate management and limiting potential arthritic conditions that may develop in cases of neglected or undiagnosed fractures. Navicular stress fractures should be treated with 6-8 weeks of non-weightbearing immobilization followed by a period of protective weightbearing in a walking cast. Physical therapy may be necessary to strengthen the posterior tibial muscle complex. Fractures which do not respond to conservative measures or which are undiagnosed will require surgical intervention to achieve compression across the fracture line. CT is beneficial in planning the surgical approach to this condition. Early diagnosis and aggressive non-weightbearing management will usually result in uneventful resolution of this potentially disabling condition.

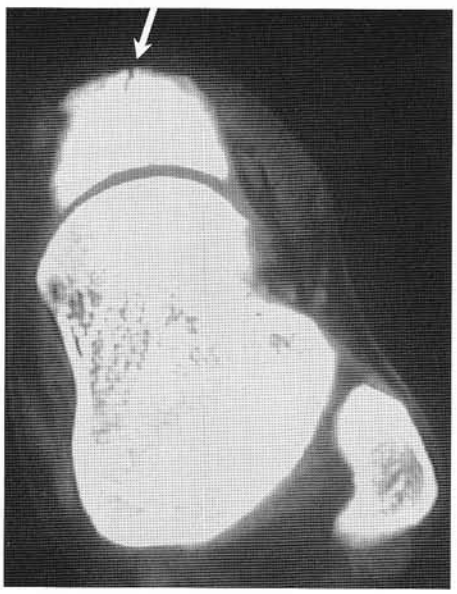

Figure 6. CT of navicular stress fracture developing into cortical fracture.

Calcaneus

Calcaneal stress fractures are the second most common stress fracture occurring in the foot. Plantar fasciitis is the most common cause of heel pain and many of the signs and symptoms can be similar. It is important to differentiate accurately between the two conditions as calcaneal stress fractures can result in compression fractures and subsequent arthritic degeneration in the subtalar joint. Calcaneal stress fractures may be treated for months as plantar fasciitis and not respond at all clinically. Calcaneal stress fractures are often the result of two competing forces. The stress from the pull of the Achilles tendon and the plantar restraint of the plantar fascia and musculature. The same mechanics which produce plantar fasciitis may be on a continuum that ends with the development of a calcaneal stress fracture if the ligamentous/muscular pull is stronger than the osseous structures. These injuries are more common in sports requiring jumping with higher impact contact with the ground and on harder surfaces.

Calcaneal stress fractures usually produce more pain throughout weightbearing with increased pain as the day or activity progresses. It is usually not accompanied by "first step" pain and can often have a degree of swelling as compared with the contralateral extremity. Pain is usually increased at the medial and/or lateral wall of the calcaneus and the "heel squeeze" test is indicative of a calcaneal stress fracture. Pain is usually not in a plantar location as is common with plantar fasciitis.

Radiographic plain film evaluation does not usually indicate a stress fracture until approximately 4-6 weeks when a sclerotic type line will develop

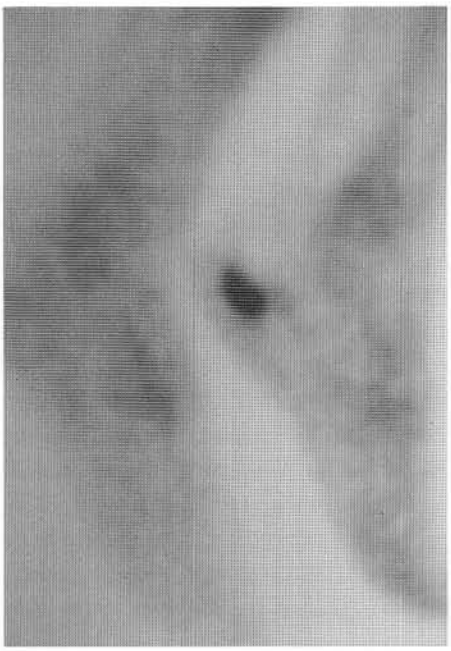

Figure 7. Bone scan of calcaneal stress fracture.

Figure 8. MRI of calcaneal stress fracture.

Figure 9. The classic "Runner's Fracture" of the distal fibula.

posterior to the posterior facet of the subtalar joint. If a high degree of suspicion for a calcaneal stress fracture is noted then early treatment and secondary imaging studies are warranted to prevent collapse at the subtalar joint. Bone scans will be positive within 24 hours of the stress fracture occurring and MRI will show the marrow edema immediately (Figure 7). MRI will also allow the opportunity to evaluate other adjacent soft tissue structures for associated pathology (Figure 8).

Calcaneal stress fractures tend to heal rapidly without the need for nonweightbearing immobilization. Key parts to the treatment plan involve eliminating the cause of the stress and immobilizing the patent in a weightbearing cast to prevent collapse at the joint level. Compression is often used to decrease edema and biomechanical considerations must be evaluated to prevent the recurrence of this injury due to the competing forces of the posterior and inferior musculo-tendinous pull.

Fibula

Fibular stress fractures are commonly called the "runner's fracture" and have been described as a result of indirect muscle pull with increased activity or potentially a result of increased pronation causing strain on the lateral column of the ankle (Figure 9). The injury typically occurs proximal to the ankle joint.

A ring-like band of edema localized to the region of the fracture is commonly identified with pin-point tenderness with palpation. As the injury progresses, more pain is involved with increasing weightbearing. The pain does not typically resolve with increased activity and may result in a shift of the bone should it not be adequately immobilized.

Plain film radiographs may take 2-3 weeks to identify fracture secondary healing. Bone scintigriphy is very useful in identifying the fracture with the use of serial radiographs to monitor any shift of the alignment of the fibula. The fracture should be evaluated for lateral shift or deviation due

to the potential pronatory force that could place a valgus stress on the fibula.

Treatment involves biomechanical support and possibly the need for weightbearing immobilization with a cast or removable fracture walker. In the case of displacement, it may be necessary to immoblize the limb nonweightbearing and potentially consider surgical intervention, although not commonly necessary.

Tibia

Tibial stress fractures can be a challenging dilemma for the lower extremity specialist, both diagnostically and in the treatment realm. These injuries commonly occur in jumping populations such as basketball players, jumpers and dancers although they have been identified following rearfoot and ankle arthrodesis. The fracture is due to either compression or tension at the anterior portion of the tibia or due to tension that occurs at the posterior portion. The latter tend to be more difficult to heal due to being on the tension side of the fracture and placing increased stress on this weightbearing bone.

Pain with direct palpation with edema or induration at the site is typically indicative of a tibial stress fracture. Pain in this region must be differentiated from medial tibial stress syndrome and exertional compartment syndrome. Pain with attempting a single leg hop is also pathomnemonic for a tibial stress fracture. Plain film radiographs may have a delay in relation to positive bone scan of three weeks to two months. Additional imaging studies are necessary to make a more rapid diagnosis. MRI will show early marrow edema prior to true cortical break and will allow for early intervention while bone scans will also be positive early in the course of the injury (Figures 10, 11).

Treatment for tibial stress fractures usually only involves the removal of the abnormal stress such as eliminating running, jumping, or dancing. Pain should be monitored as should serial radiographs for signs of union. If the patient does not respond, a weight bearing fracture walker or cast may be applied and in some circumstances nonweight-bearing immobilization. Tibial stress fractures usually have a significant delay in diagnosis and therefore have an increased ratio of delayed or nonunion fractures. The use of bone stimulation can assist with the healing of these fractures and allow more expedient return to activity. The person should not return to any athletic activity until able to perform the single leg hop painfree, which may take 6 months or longer.

Stress fractures can create significant problems and limitations for patients whether due to abnormal stresses or due to osseous insufficiency. They may also indicate an underlying disease process or deficiency that must be managed to eliminate the increased risk for more stress fractures or other osseous injuries. Early diagnosis and aggressive treatment with various forms of immobilization will best serve the patient sustaining this type of injury and allow for resumption or normal function with the underlying cause established and treated.

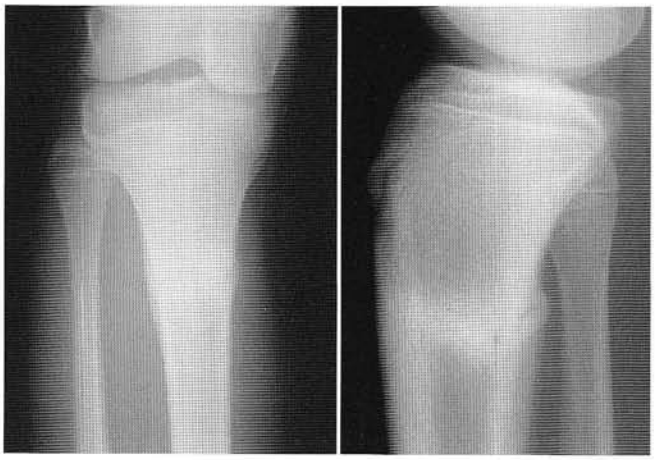

Figure 10. Proximal tibial stress fracture in distance runner doing plyometics.

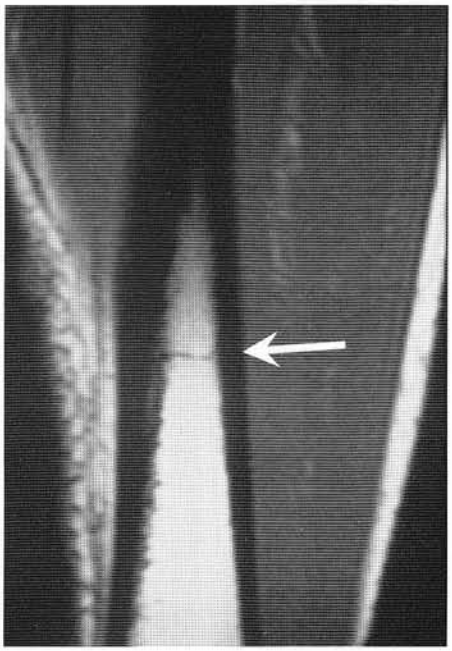

Figure 11. MRI of tibial stress fracture.

REFERENCES

1. Johnson LC, Stradford HT, Geis RW, et al. Hisogenesis of stress fractures. *J Bone Joint Surg Am* 1963;45:1525.
2. Gilbert RS, Johnson HA. Stress fractures in military recruits – a review of twelve years' experience. *Mil Med* 1966;131:716-21.

ADDITIONAL REFERENCES

Baker J, Frankel VH, Burnstein A. Fatigue fractures: biomechanical considerations. *J Bone Joint Surg Am* 1972;54:1345.

Bennell KL, Malcolm SA, Thomas SA, et al. The incidence and distribution of stress fractures in competitive track and field atletes: a twelve month prospective study. *Am J Sports Med* 24: 211-217, 1996.

Daffner RH, Pavlov H. Stress fractures: current concepts. *AJR* 159: 245-252, 1992.

Darby RE. Stress fractures of the os calcis. *JAMA* 200: 1183, 1967.

Derereaus MD, Parr GR, Lachmann SM , et al. The diagnosis of stress fractures in athletes. *JAMA* 252:531-533, 1984.

Geslien GE, Thrall JH, Espinosa JL, et al. Early detection of stress fractures using Tc-polyphosphate. *Radiology* 1976;121:683-7.

Giladi M, Migrom C, Simpkiin A, et al. Stress fractures: identifiable risk factors. *Am J Sports Med* 1991;19:647-52.

Lidor C, Ferris LR, Hall R, et al. Stress fracture of the tibia after arthrodesis of the ankle or the hindfoot. *J Bone Jone Surg Am* 1997;79:558-64.

McBryde AM. Stress fractures in runners. *Clin Sports Med* 1985;4:737-53.

Orava S,Hullko A. Delayed unions and nonunions of stress fractures in athletes. *Am J Sports Med* 1988;16:378-82.

Orava S, Puranen J, Ala-Ketola L. Stress fractures casued by physical exercise. *Acta Orthop Scand* 1978;49:19-27.

Prather JL, Nusynowitz ML, Snowdy HA, et al. Scintigraphic findings in stress fractures. *J Bone Joint Surg Am* 1977;59:869-74.

Stanitski CL, McMaster JH, Scranton PE. On the nature of stress fractures. *Am J Sports Med* 1978;6:391-6.

Sterling JC, Edelstein DW, Calvo RD, et al. Stress fractures in the athlete: diagnosis and management. *Sports Med* 1992;14:336-46.

Wilson ES, Katz FN. Stress fractures: an analysis of 250 consecutive cases. *Radiology* 1969;92:481-6..