

# MANAGEMENT OF COMPLEX FIBULAR FRACTURE: Double Plating of Fibular Fractures

*Justin J. Fleming, DPM*

*Kwasi Y. Kwaadu, DPM*

*David Lin, DPM*

### INTRODUCTION

Fractures about the ankle joint can be associated with various outcomes following surgical repair. When the injury is complicated with poor bone quality, complex fracture patterns, and/or high energy mechanisms, the prognosis is less favorable. In the geriatric population, the preinjury functional capacity is a significant influence on the decision to proceed with open reduction and internal fixation (1, 2). Failure to restore and maintain fibular length, rotation, and axial alignment are known to create asymmetrical loading patterns and altered contact characteristics in the ankle mortise, promoting degenerative changes and functional impairment (3).

Complex fractures of the fibula are typically seen in two scenarios. The first occurs in the geriatric population with diminished bone stock. In this scenario low energy rotational forces can produce complex fracture patterns making fracture reduction and maintenance complicated. The second scenario is seen in fractures produced by high energy mechanisms generated by combined axial and rotational loading producing significant metaphyseal and diaphyseal comminution. Various techniques have been described in the management of these injuries via a combination of load sharing and load bearing devices, the most common of which involve laterally or posteriorly placed locking plates. The utilization of single bridge plating augmented with intramedullary Kirschner wires has also been described highlighting the biomechanical advantages over simpler bridge plating techniques (4, 5). The technique in this publication similarly has been previously described in a single case study and has subsequently been referred to by other various authors as an option for severely comminuted fractures (6, 7). However, there have been no studies evaluating the outcomes of a larger patient population in order to ascertain its safety profile and efficacy. In this retrospective case series, we evaluate the outcomes of 24 ankle fractures treated with this double bridge plating

technique over the past 4 years in order to offer another technique in the surgeon's arsenal in managing these more difficult fracture patterns.

### MATERIALS AND METHODS

Indications for this technique were preoperative radiographs demonstrating significant porosis and/or significant comminution or bone loss associated with the fibular fracture. Additional indications included reduced bone quality at the time of surgery and its reluctance to accept hardware with appropriate torque. In order to assess the clinical value of this technique, we evaluated the time to radiographic union, subjective complaints related to hardware irritation and incidences of removal, and wound complications.

Following Institutional Board Review approval, consent was obtained from all patients. Inclusion criteria included patients with unstable malleolar fractures who had undergone double plating technique for fibular fractures without the utilization of interfragmentary fixation and were able to provide informed consent. Exclusion criteria included any plating technique that incorporated interfragmentary screw fixation. A total of 524 ankle fractures were surgically repaired from 2007 to 2011 by the primary surgeon (JJF).

We retrospectively reviewed the records of 24 patients who met the inclusion criteria who had been managed in a single hospital system. A total of 12 male patients and 12 female patients with an average age of 53.6 years were identified. There were three isolated lateral malleolar fractures, two of which demonstrated associated deltoid insufficiency, six bimalleolar ankle fractures, thirteen trimalleolar ankle fractures, and two tibial plafond fracture with isolated lateral malleolar fractures. Twelve injuries required syndesmotom stabilization. Three patients each sustained the following associated injuries: a nonoperative cervical spinal injury, nonoperative metatarsal fractures, and a spiral fifth metatarsal neck fracture that required surgical

repair. Four patients sustained high energy injuries. The mechanism of injury was a motor-vehicle accident for two patients, a pedestrian versus motor vehicle accident for one patient, and a fall from a three-story building in one patient. A rotational mechanism was the etiology of the injury for the remaining 20 patients. Two patients sustained Gustilo-Anderson IIIA open injuries, and the remaining 22 patients sustained closed injuries. Ten patients sustained dislocated injuries that required closed reduction. The average time from injury to repair of the fibular fracture was 16.6 days. Computed tomography (CT) evaluation was performed at the surgeon's discretion.

Postoperative management consisted of immobilization in well-padded posterior splint with the ankle in neutral alignment. Range of motion exercises were begun when the wounds were sealed. Serial radiographs were obtained to monitor bone healing and early fixation failure. Progressive protected weightbearing was begun when radiographic and clinical union were present.

In order to assess the clinical value of this technique, we evaluated the time to radiographic union, subjective complaints related to hardware irritation and incidences of removal, and wound complications. Charts and radiographs were analyzed retrospectively and the following items were documented: radiographic/clinical union, compliance, mechanism of injury, other musculoskeletal injuries, complications, comorbidities, and time to unprotected weightbearing (Figure 1).

## SURGICAL TECHNIQUE.

Patients were placed in the supine position with a bolster under the ipsilateral hip. With hemostasis accomplished with the aid of a pneumatic thigh tourniquet, a standard lateral incision was created over the fibula. This incisional approach was modified in cases of concomitant tibial plafond fractures and those patients requiring direct posterior exposure to the ankle. If a medial malleolar fracture was present, it was frequently fixed first to provide a stabilizing effect on the talus and facilitate the lateral reduction. Exposure was facilitated using sharp and blunt dissection techniques. Following debridement of the fracture interface and periosteal reflection, reduction was performed and maintained with a combination of bone reduction clamps and Kirschner wires (Figure 2). Periosteal stripping was minimized and attached cortical fragments were maintained on a periosteal hinge in an effort to preserve blood supply.

At this time, an intraoperative assessment of bone quality was performed. If the reduction forceps sunk into the cortex of the fibula with little resistance, the utility of an

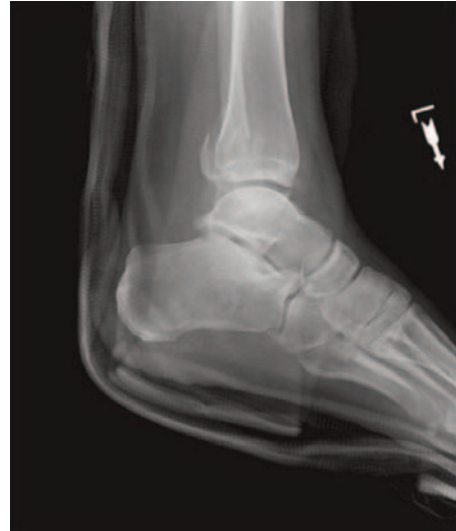

Figure 1A. Lateral projection of a trimalleolar fracture.

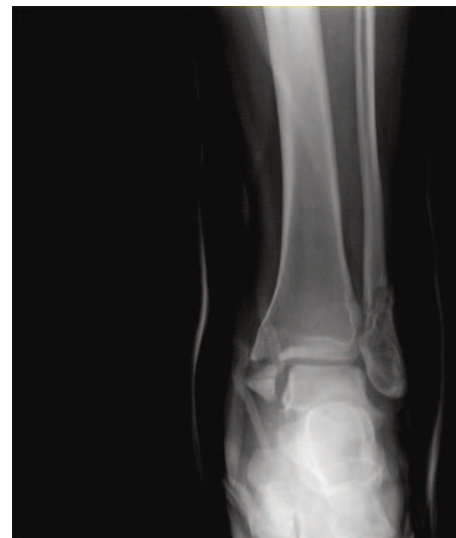

Figure 1B. Anteroposterior projection.

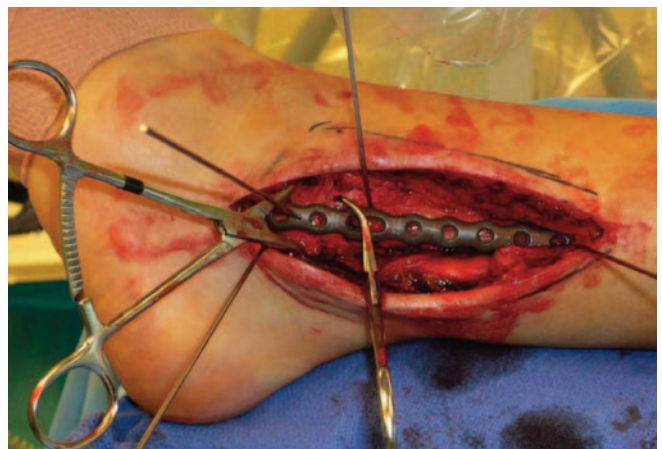


Figure 2. Reduction and rotation of the fibular fracture maintained with Kirschner wires.

interfragmentary screw was precluded. Often the geometry of the fracture did not lend itself to screw compression.

When direct cortical interdigitation could not be utilized to confirm the reduction because of either severe comminution and/or bone loss, the distal fragment was often provisionally fixated to the talus to maintain length and rotation. A 1/3 tubular plate with locking capability was placed posterolaterally with its most inferior end just proximal to the superior peroneal retinaculum. The plate is compressed to the bone via a verbugge or serrated bone clamp. Six cortices are engaged in the diaphysis with the first screw placed just proximal to the fracture. The application of locking screws on the posterior plate is rarely needed. Although a distal screw in the posterior plate has not been advocated historically in the literature, we found that this screw routinely has good purchase and appears to provide rotational control of the distal fragment. With careful technique, bicortical purchase can be achieved. In an individual with a smaller diameter fibula, a 1/4 tubular plate can be substituted.

Following posterolateral plate placement, a 1/3 tubular plate with similar capacity was applied laterally and its length confirmed fluoroscopically. Plate contouring was performed on an as needed basis. Bicortical screw fixation was then performed proximal to the fracture with multiple unicortical locking screw fixation within the lateral malleolus (Figure 3). At the most proximal end of the plate, a bicortical non-locking screw can be utilized for two main reasons. First, the fibular diaphysis offers ample cortical purchase and as such, the benefit of locking screws are not significantly greater than nonlocking screws. Secondly, there is evidence that the utilization of a nonlocking screw in long bone fractures can be associated with a reduction of the incidence of periprosthetic fracture (7). We have not witnessed this problem in the fibula.

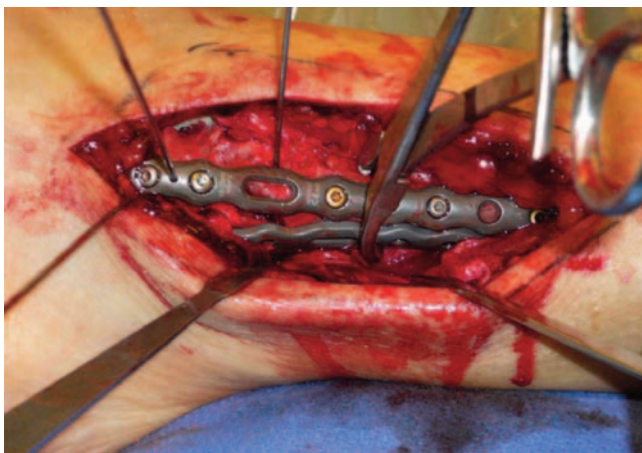


Figure 3A. Lateral plate applied with locking screws (silver) in malleolus and non-locking screws (gold) in proximal segment of plate.

Another beneficial technique in the severely comminuted setting is by overdrilling the near fibular cortex immediately deep to the plate and subsequently underdrilling the far fibular cortex. This serves to reduce scattering of the comminuted fragments. If satisfactory alignment is achieved, provisional fixation can be removed. Careful fluoroscopic assessment is critical to ensure extraarticular screw placement and overall plate positioning (Figure 4). In complex fractures, radiographic parameters as described by Weber and Simpson are useful guides to obtaining a well-aligned mortise (9).

## RESULTS.

Ages ranged from 27 to 79 years with a mean of 53.6 years. There were 12 males and 12 females. Follow-ups ranged from 6 to 72 weeks with a mean of 19.5 weeks. Additional patient demographics and comorbidities can be reviewed in Table 1.

There were two hardware-related reoperations. One patient complained of discomfort of a medial distal tibial plate used for osteosynthesis of his tibial OTA 43C3 fracture, which was removed one year postoperatively. In the second case, revisional osteosynthesis unrelated to the fibular repair was performed 20 days following the initial fibular repair. There were no other instances of hardware removal because of symptomatic complaints or local irritation. There were two instances of postoperative infection in the perioperative period defined as the time until the incision site was healed, both of which occurred in patients with diabetes mellitus. One patient was managed uneventfully with oral antibiotics. The second patient required hospitalization due to mild systemic manifestations, which resolved uneventfully with intravenous antibiotics.

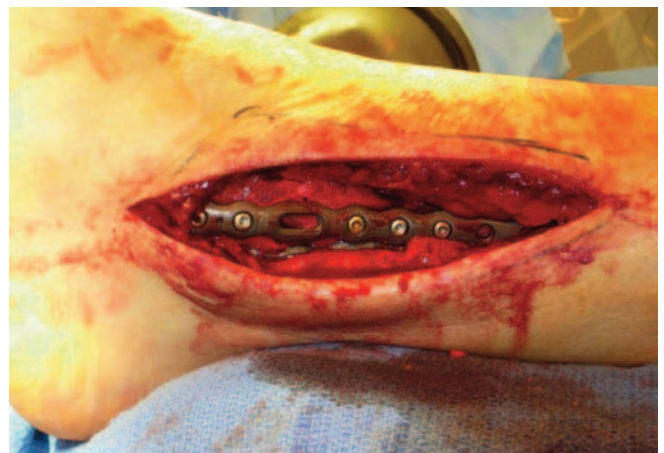

Figure 3B. Lateral plate applied with locking screws.

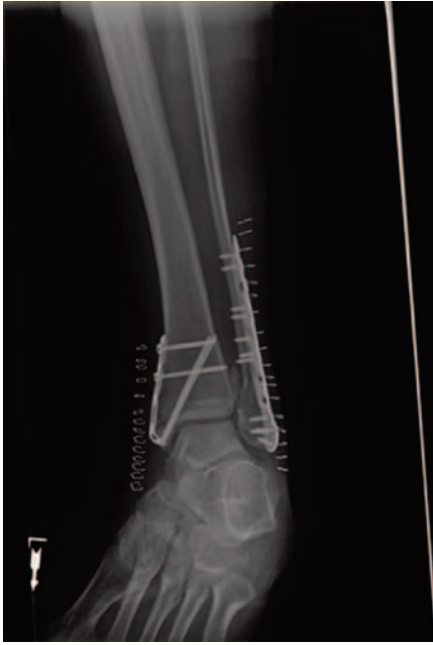

Figure 4A. Final intraoperative appearance of the double plated fibula with concurrent post-operative radiographs.

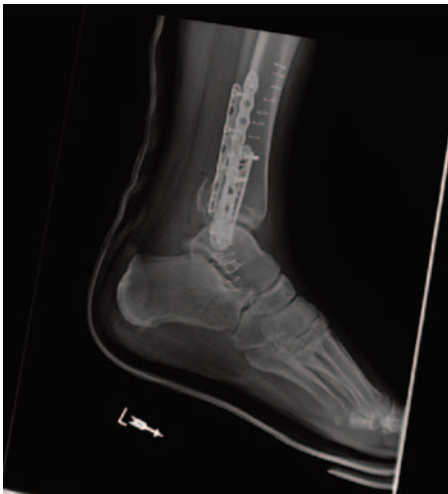

Figure 4B. The medial malleolar fracture is addressed with two interfragmentary screws augmented with a hook plate.

Due to real life scenarios that influence the patients' ability to keep appointments times, it was difficult to unequivocally correlate suture and staple removal with delayed wound healing. However, the latest follow-up within the first postoperative month, with respect to all distal fibular incisions of 22 of the 24 subjects objectively documented either of the following: staples/sutures removed, or wounds healed. In the other two instances, chart review unequivocally documented instances of delayed wound healing over the site of fibular exposure 1 and 1.5

months, respectively, both of which were managed uneventfully with local wound care.

Time to unrestricted weightbearing ranged from 6 to 26 weeks with a mean of 11.3 weeks.

Unrestricted weightbearing was prolonged to 16 weeks in a noncompliant diabetic with a closed dislocated trimalleolar fracture who underwent osteosynthesis with multiple syndesmotomic screws. Unrestricted weightbearing was similarly prolonged to 21 and 26 weeks, respectively in two patients with OTA 44C2 and 43C3 pilon fractures with associated fibular fractures. Another patient who underwent revisional surgery at 20 days unrelated to the original repair of the fibular fracture was not cleared for unrestricted weightbearing until 14 weeks. With these patients eliminated, the mean time to unrestricted weight bearing was 9.75 weeks. Fracture consolidation ranged from 5 to 11 weeks with a mean of 7.5 weeks, all of which preceded unprotected weightbearing.

## DISCUSSION

Since the inception of the AO foundation, the concepts and application of internal fixation with special attention to fractures of the appendicular skeleton has accelerated exponentially. With these principles as the mainstay, many authors have described various methods of fixation involving the utilization of locking and non-locking screws, highlighting placement in order to influence optimal biomechanical stability (10,11). In keeping with our growing understanding in treating these pathologies and these recommendations, various companies have created implants with these objectives in mind in order to facilitate bone healing and an earlier return to function.

Lateral neutralization plating has historically been the most commonly utilized fixation for lateral malleolar fractures. With friction generated between the interdigitating bone ends via interfragmentary compression, the plate serves to neutralize the effects of bending, rotational, and axial forces at the fracture site functioning as a load sharing device. Stability is created via friction at the plate-bone interface. This is directly proportional to the amount of available torque when inserting the nonlocking screws. In standard lateral plating of Weber B fractures, unicortical screw fixation is employed in the distal portion of the fibula to avoid violating the articular components of the ankle mortise. The working length of the screws is significantly reduced in the lateral malleolus resulting in lesser mechanical stability. The disadvantage of this plating technique is magnified in porotic bone and in short or comminuted distal segments.

Table 1

| Sex | Age | Injury Mechanism                             | Fracture Type   | Comorbidities  | Complication  | Management   | Fracture Consolidation |
|-----|-----|--|---|--|---|--|------------------------|
| F   | 39  | Rotational: Slidding                         | Closed, right, trimalleolar fracture with large posterior piece: Weber B (no SD screw)                  | None   | None  | No Intervention  | 5 weeks                |
| F   | 79  | Rotational: Trip and fall                    | Closed, left, trimalleolar fracture: Weber B (SD screw)   | GERD, HTN, encephalopathy  | Delayed wound healing 1 month postop  | Local wound care.  | 7 weeks                |
| F   | 44  | Rotational: Slipped on ice                   | Closed, dislocated, right, complex, trimalleolar fracture: Weber B (no SD screw)                        | Former smoker: Quit > 10yrs  | Malaligned anterior collicular fracture   | Revisional ORIF  | 8 weeks                |
| M   | 56  | Rotational: Fall while shoveling             | Closed, dislocated, left, trimalleolar fracture: Weber B (SD screw)                                     | DM<br>gross WB non compliance<br>premature WB  | Cellulitis POD # 7<br>Small pressure wound distal to lateral incision<br>Non infected dime-sized heel decubitus ulcer 2 months postop   | Hospitalization and intravenous antibiotics  | 9 weeks                |
| M   | 60  | Rotational: Missed step coming out bar       | Closed, dislocated, right, complex, trimalleolar fracture: Weber B (no SD screw)                        | HTN, Chol, MI x3, CABG, ETOH   | None  | No Intervention  | 11 weeks               |
| F   | 28  | Auto v ped                                   | Closed, dislocated right, trimalleolar fracture with severe fracture blisters: Weber C (with SD screws) | Concomittant unstable TMT fracture<br>Diploidal abuse<br>Recreational drugs<br>Smoker  | Postero-medial ankle wound with purulence<br>Exposed posterior tibial tendon 3 months postop<br>Drainage from posterior tibial tendon 3.5 months postop<br>4 months postop, posterior tibial tendon granulating | Hospitalization with debridement and intravenous antibiotics<br>Local wound care wound NPWT, intravenous antibiotics via PICC line<br>Local care (NPWT off x 2 weeks). Patient refused rehospitalization and debridement<br>Local care, NPWT and intravenous antibiotics via PICC line | 8 weeks                |
| F   | 45  | Rotational: Uneven pavement                  | Closed, dislocated, left, trimalleolar fracture: Weber B (SD screw)                                     | Smoker, HTN  | None  | No Intervention  | 5 weeks                |
| M   | 34  | High energy MVC                              | Open (GA IIIA), left pilon fracture(OTA 43C3) with a comminuted distal fibular fracture (no SD screw)   | Smoker: WB non compliance  | Painful medial tibial plate with broken screw   | Removal of all hardware 1 year postop  | 8 weeks                |
| M   | 36  | High energy MVC                              | Closed, right, bimalleolar fracture with medial malleolar comminution (no SD screw)                     | MVP: Nonoperative cervical spine injury  | None  | No Intervention  | 9 weeks                |
| M   | 38  | Rotational: syncope episode                  | Closed, dislocated, left, trimalleolar fracture: Weber B (SD screw)                                     | DM, COPD, Back pain, anxiety, HTN  | None  | No Intervention  | 6 weeks                |
| F   | 34  | Rotational: Fall while cleaning snow off car | Closed, left, trimalleolar fracture: Weber B (SD screw)   | DEXA 1.9, HTN, HLD   | Proximal wound suture abscess with dehiscence 1.5 months postop   | Local care   | 5 weeks                |
| M   | 39  | Rotational: Fall down steps                  | Closed, dislocated, left, trimalleolar fracture: Weber B (SD screw)                                     | Hyperthyroidism, IDDM, CHF, GERD, Smoker   | None  | No Intervention  | 11 weeks               |
| F   | 58  | Rotational: Slip and fall                    | Closed, left, bimalleolar fracture: Weber B (with SD screw)   | HTN, Depression  | None  | No Intervention  | 6 weeks                |
| F   | 66  | Rotational: Slip and fall                    | Closed, dislocated, right, trimalleolar fracture: Weber B (SD screw)                                    | WB non compliance<br>HLD, HTN, Anxiety, COPD, anemia<br>bisphosphonate therapy   | None  | No Intervention  | 10 weeks               |
| M   | 75  | Rotational: moving fridge                    | Open (GA IIIA), right, bimalleolar fracture: Weber B (no SD screw)                                      | ETOH   | None  | No Intervention  | 6 weeks                |
| M   | 70  | Rotational: Slipped in kitchen               | Closed, left, fibular fracture: Weber B (SD screw)  | FAO, CAD, HTN, Smoker  | None  | No Intervention  | 6 weeks                |
| M   | 60  | Rotational: twisted ankle                    | Closed, left, comminuted, distal fibular (no SD screw)  | WB noncompliance, CAD, IDDM, A fib<br>hypothyroidism, concomittant left spiral fifth metatarsal fracture   | Cellulitis POD # 6 with suture rejection  | Oral antibiotics   | 7 weeks                |
| F   | 27  | High energy: Auto v ped                      | Closed, left, dislocated bimalleolar fracture: Weber B (no SD screw)                                    | Concomittant left nonoperative second and third metatarsal fractures<br>Decompressional fasciotomy left foot 20 days prior to ORIF<br>IVDA, Smoker | Delayed wound healing   | Local care   | 7 weeks                |
| F   | 52  | Rotational: Trip and fall                    | Closed, right, dislocated trimalleolar fracture: Weber B (no SD screw)                                  | None   | None  | No Intervention  | 6 weeks                |
| M   | 36  | Rotational: Slip and fall                    | Closed, left non union porotic fibular fracture: Weber B (no SD screw)                                  | IDDM, obesity, HTN, Smoker   | None  | No Intervention  | 7 weeks                |
| F   | 72  | Rotational: Trip and fall                    | Closed, left bimalleolar fracture: Weber B (no SD screw)  | PE, CAD, HTN, Chol, Anxiety  | None  | No Intervention  | 6 weeks                |
| F   | 54  | Rotational: Slip and fall                    | Closed, right trimalleolar fracture: Weber B (with SD screw)  | Asthma, corticosteroids medications  | None  | No Intervention  | 6 weeks                |
| M   | 69  | Rotational: Slip and fall                    | Closed, right bimalleolar fracture: Weber B (with SD screw)   | IDDM, HTN, CAD   | None  | No Intervention  | 6 weeks                |
| F   | 44  | Rotational: Trip and fall                    | Closed, dislocated left trimalleolar fracture: Weber B (with SD screw)                                  | Smoker   | None  | No Intervention  | 7 weeks                |
| M   | 31  | High energy: From from height                | Closed, left pilon fracture (OTA 44C2)  | Smoker, WB noncompliance   | None  | No Intervention  | 17 weeks               |

LEGEND

|       |   |      |                           |      |                                |            |                                       |      |   |
|-------|---|------|---------------------------|------|--------------------------------|------------|---------------------------------------|------|---|
| SD    | Syndesmotic                             | Chol | hypercholesterolemia      | CABG | Coronary Arterial Bypass Graft | COPD       | Chronic Obstructive Pulmonary Disease | OTA  | Orthopaedic Trauma Association                |
| GERD  | Gastroesophageal reflux disease         | MI   | myocardial infarction     | FibH | Fibular Head                   | MVC        | Motor Vehicle Collision               | POD  | Postoperative day                             |
| IDDM  | Insulin Dependent Diabetes Mellitus     | FAO  | Fatigue                   | WB   | Weight Bearing                 | Auto v Ped | Automobile struck by automobile       | P-IC | Peripherally inserted Central Catheter        |
| NDDM  | Non-Insulin Dependent Diabetes Mellitus | CAD  | Coronary Arterial Disease | MVP  | Mitral Valve Prolapse          | NPWT       | Negative-Pressure Wound Therapy       | USIB | Unrestricted weight bearing                   |
| A-Fib | Atrial Fibrillation                     | CHF  | Congestive Heart Failure  | TMT  | Tarsometatarsal Joint          | DEXA       | Dual Emission X-ray Absorptiometry    | GA   | Gustilo Anderson Open Fracture Classification |
| HTN   | Hypertension                            |      |                           |      |                                |            |                                       |      |   |

Despite these shortcomings, this remains a proven option for uncomplicated fractures of the distal fibula.

Isolated posterior plating techniques in Weber B fractures serve to obviate the need for distal screws by placing the plate over the fracture apex. Under loading conditions, the fracture fragment attempts to escape posteriorly. The posterolateral application on the distal fibula changes the plate loading characteristics from a neutralization into a load bearing device. This orientation counters shear forces at the fracture by converting them to compressive loads. Additional rotational stability can be achieved by placing bicortical screws from posterior to anterior in the distal fibula with little concern of violating the ankle joint. This increases the working length and

pullout strength of the screws, improving the construct's resistance to failure.

Despite the higher utilization of laterally placed fixed angle plates in lateral malleolar fractures, posterior non-locking plates have been shown to provide improved construct stiffness and torque to failure (13, 14). This is most likely due to the load bearing properties associated with its placement. Additional factors include a combination plate stiffness and the strong bicortical screw purchase in the fibular diaphysis. In this scenario failure occurs either by pullout of the screw immediately proximal to the fracture line or by plastic deformation of the plate at the fracture apex (13). However, this plating technique is not entirely without risk. Weber and Krause retrospectively evaluated seventy

patients who underwent posterior plating for Weber B fractures; 30 of which underwent plate removal because of discomfort and symptoms along the course of the peroneal tendons. Nine of these 30 displayed had lesions intra-operatively (15).

We have nonetheless encountered scenarios at our institution where these previously described techniques when evaluated individually do not always appear to provide sufficient fracture stability. With special attention to high energy injuries, porotic malleolar fractures with significant comminution, and bone loss, and those fractures without an identifiable fracture apex, the utilization of interfragmentary screw fixation in most instances appear a poor choice. Approaching a torque of 3.5Nm for a 3.5 cortical screw is not possible when the sturdy, structural cortical bone is sparse (16). In these instances our treatment method has been the utilization of both lateral and posterior plating techniques. With the application of both lateral and posterior plates, the summation of strengths for each of these techniques can be achieved. This inherently stronger construct allows for early active range of motion with little fear in loss of reduction as well as maintenance of the reduction until bony union. Gajendran et al biomechanically evaluated metacarpal fracture models with three different plating techniques: single row non-locking plate, double row non-locking plate, and double row locking plates. The models were tested in torsion and cantilever bending. Both double row-plating constructs demonstrated statistically equivalent bending and torsional stiffness, which was significantly higher than the single row non-locking plate (17).

Additional hardware considerations may be given to the screw density and screw position within the plate and their relative proximity to the fracture. Freeman et al evaluated 7 different plate screw constructs in hybrid constructs in order to objectively define parameters influencing stability and

found the following (Figure 5): 1) Stiffness was most influenced by number of screws: increased by 33% from 3 to 4 screws per side; 2) The utilization of at least 3 locked screws per side increased the torsional stiffness of the construct by 24%; 3) Post-cyclic removal torque of non-locked screw furthest from the fracture was increased by 274% when they were protected by locked screws (10).

Stoffel et al (11) revealed similar findings in their study. Torsional stability was mostly influenced by the number of screws. However, more than three screws did little to affect axial stiffness whereas more than four screws did little to improve torsional stiffness. The position of the third screw significantly influenced axial stiffness: the closer to the fracture, the stronger the construct's torque to failure (Figure 6). With greater understanding of these plating models in long bone fractures the above recommendations can be made to optimize the overall stability of the constructs.

These comminuted fractures are not unique to our institution and historically these have been managed with single bridged plating and bone grafting. Therefore randomized control trials evaluating outcomes of malunion and subsequent posttraumatic arthritis may more appropriately justify the utilization of this technique. Additional long-term followup may grant better insight to time-related screw loosening and hardware irritation after fracture union. We nonetheless theorize that this construct is structurally more sound and will better resist hardware failure due to cyclical loading. Further biomechanical evaluations of this double plating technique are required to justify the cost benefit of the additional hardware and operative time. However short term follow-ups demonstrate that this is a safe and viable option for the operative management of these complex fibular fractures with little inherent risk of delayed healing or hardware related complications.

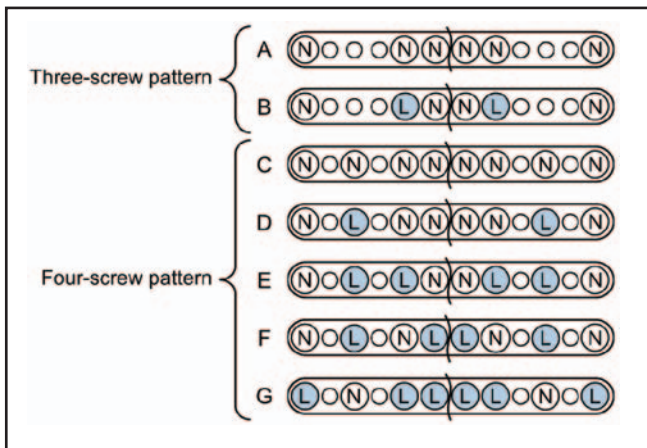


Figure 5. Schematic of constructs evaluated by Freeman et al with improved construct performance from A to G.

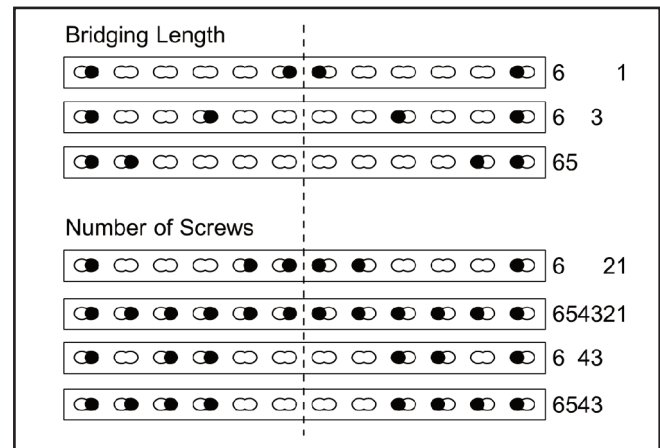


Figure 6. Schematic of construct evaluated by Stoffel et al. At least 3 screws are needed to significantly affect constructs stiffness.

## REFERENCES

1. Lemon M, Somayaji HS, Khaleel A, Elliot DS. Fragility fractures of the ankle: Stabilisation with an expandable calcaneotalotibial nail. *J Bone Joint Surg Br* 2005;87:809-13.
2. Shivarathre DG, Chandran P, Platt SR. Operative fixation of unstable ankle fractures in patients aged over 80 years. *Foot Ankle Int* 2011;32:599-602.
3. Ramsey PL, Hamilton W. Changes in tibiotalar area of contact caused by lateral talar shift. *J Bone Joint Surg Am* 1976;58:356-7.
4. Koval KJ, Petraco DM, Kummer FJ, Bharam S. A new technique for complex fibula fracture fixation in the elderly: A clinical and biomechanical evaluation. *J Orthop Trauma* 1997;11:28-33.
5. Dunn WR, Easley ME, Parks BG, Trnka HJ, Schon LC. An augmented fixation method for distal fibular fractures in elderly patients: A biomechanical evaluation. *Foot Ankle Int* 2004;25:128-31.
6. Bevan WS, Barei DP, Nork SE. Operative fixation of osteoporotic ankle fractures. *Tech Foot Ankle Surg* 2006;5:222-9.
7. Savage TJ, Stone PA, McGarry. Internal fixation of distal fibula fractures: A case presentation demonstrating a unique technique for a severely comminuted fibula. *J Foot Ankle Surg* 1995;34: 587-92.
8. Bottlang M, Doornink J, Byrd GD, Fitzpatrick DC, Madey S. A nonlocking end screw can decrease fracture risk caused by locked plating in osteoporotic diaphysis. *J Bone Joint Surg Am* 2009; 91:620-7.
9. Weber BG, Simpson LA. Corrective lengthening osteotomy of the fibula. *Clin Orthop Related Res* 1985;199:61-7.
10. Freeman AL, Tornetta III P, Schmidt A, Bechtold J, Ricci W, Fleming M. How much do locked screws add to the fixation of "hybrid" plate constructs in osteoporotic bone? *J Orthop Trauma* 2010;24:163-9.
11. Stoffel K, Dieter U, Stachowiak G, Gachter A, Kuster M. Biomechanical testing of the LCP-how can stability in locked internal fixators be controlled? *Injury* 2003;34 Suppl 2:B11-9.
12. Egol KA, Kubiak EN, Fulkerson E, Kummer FJ, Koval KJ. Biomechanics of locked plates and screws. *J Orthop Trauma* 2004;18:488-93.
13. Schaffer JJ, Manoli II A. The antiglide plate for distal fibular fixation. *J Bone Joint Surg Am* 1987;69:596-604.
14. Minihane KP, Lee CL, Ahn C, Zhang LQ, Merk BR. Comparison of lateral locking plate and antiglide plate for fixation of distal fibular fractures in osteoporotic bone: a biomechanical study. *J Orthop Trauma* 2006;20:562-6.
15. Weber M, Krause F. Peroneal tendon lesions caused by the antiglide plates used for fixation of lateral malleolar fractures: the effect of the plate and screw position. *Foot Ankle Int* 2005;26:281-5.
16. Cordey J, Borgeaud M, Perren SM. Force transfer between plate and the bone: relative importance of the bending stiffness of the screws and the friction between plate and bone. *Injury* 2000;31 Suppl 3:C21-8.
17. Gajendran VK, Szabo RM, Myo GK, Curtiss SB. Biomechanical comparison of double-row locking plates versus single and double-row non-locking plates in a comminuted metacarpal fracture mode. *J Hand Surg Am* 2009;34:1851-9.