

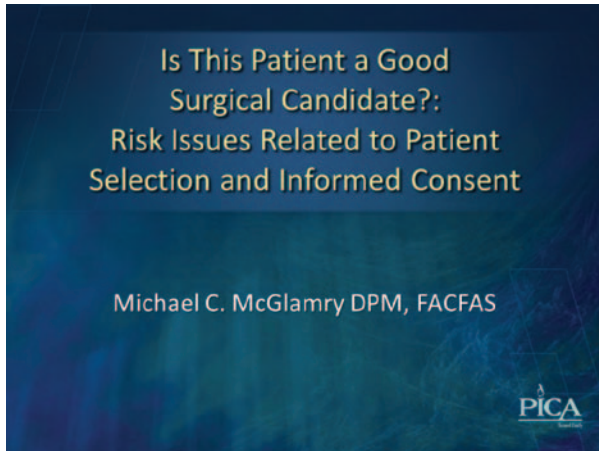

Figure 1.

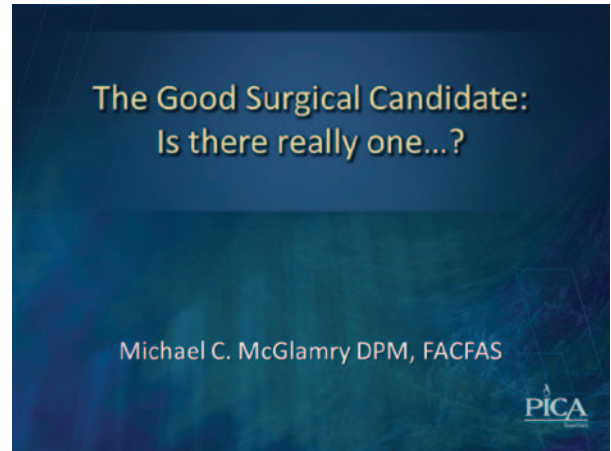

Figure 2.

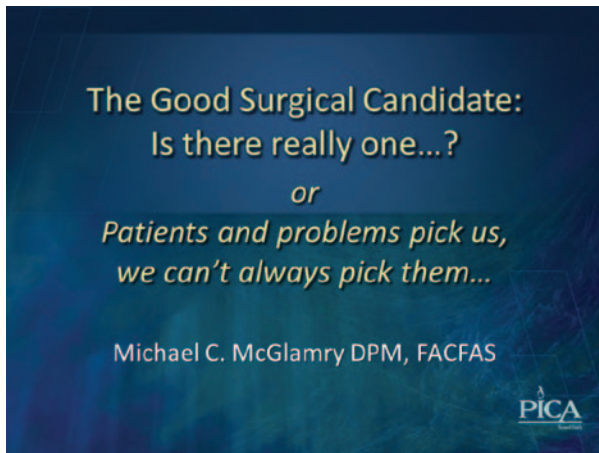

Figure 3.

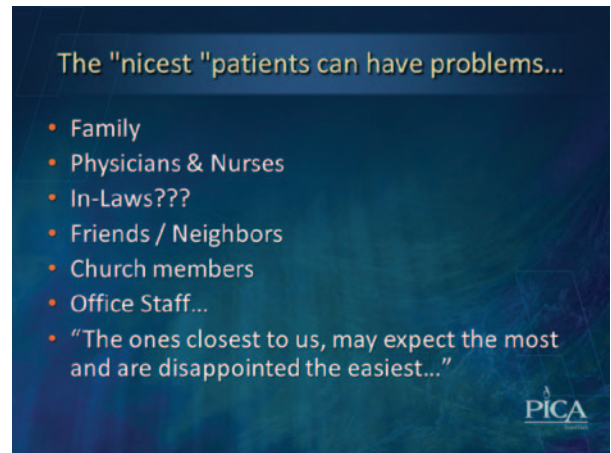


Figure 4.

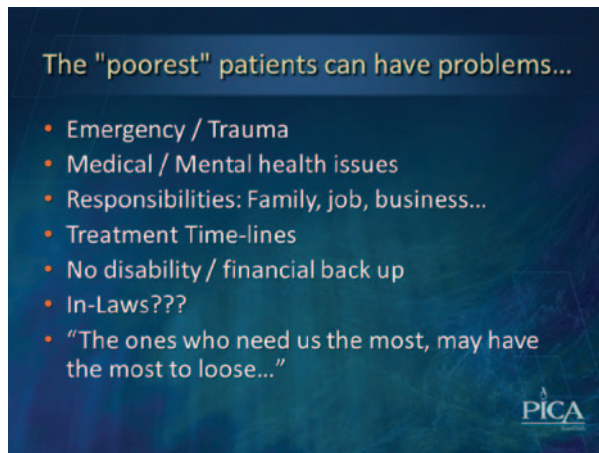


Figure 5.

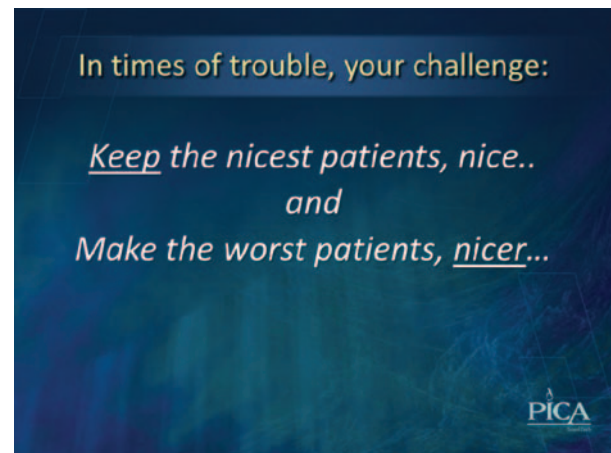


Figure 6.

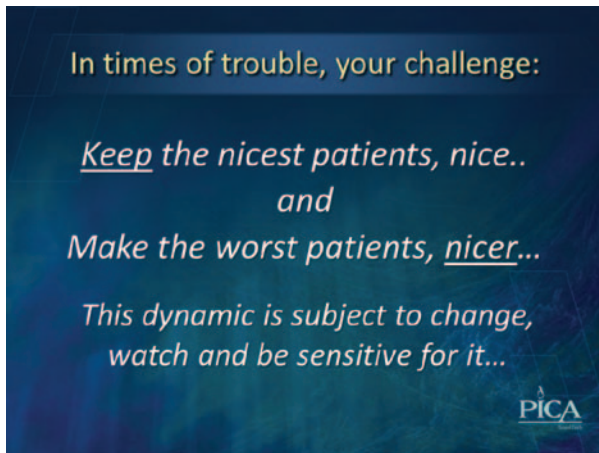


Figure 7.

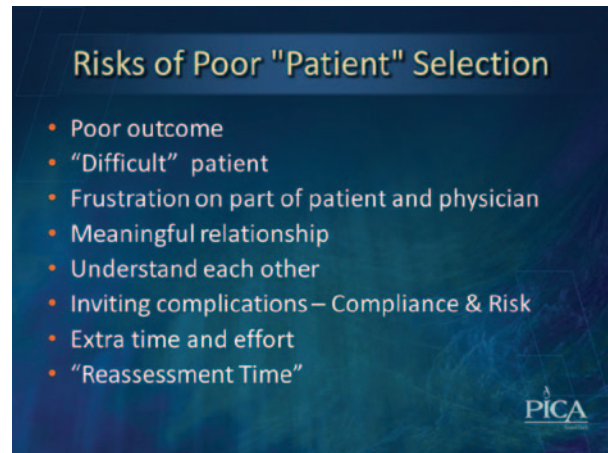


Figure 8.

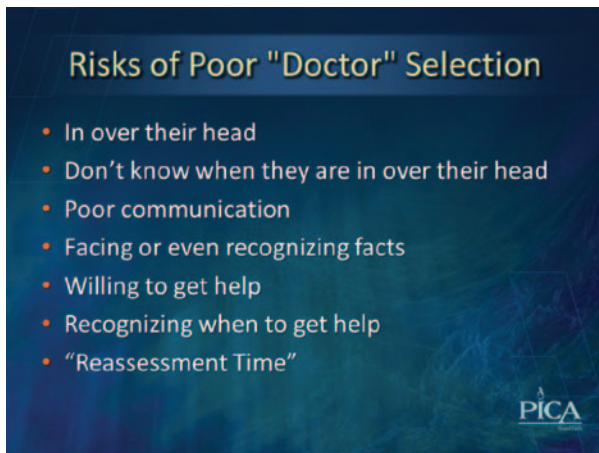


Figure 9.

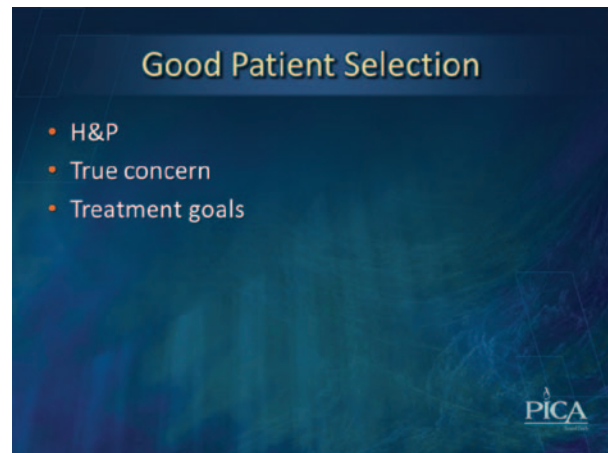

Figure 10.

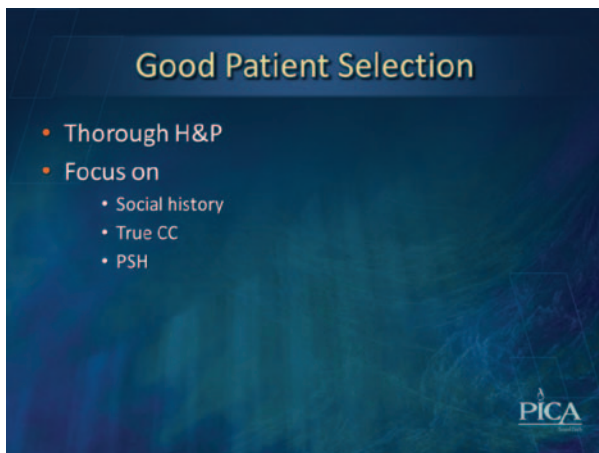


Figure 11.

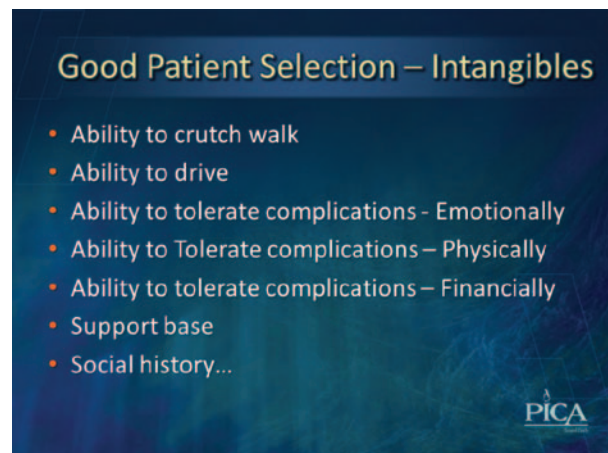

Figure 12.

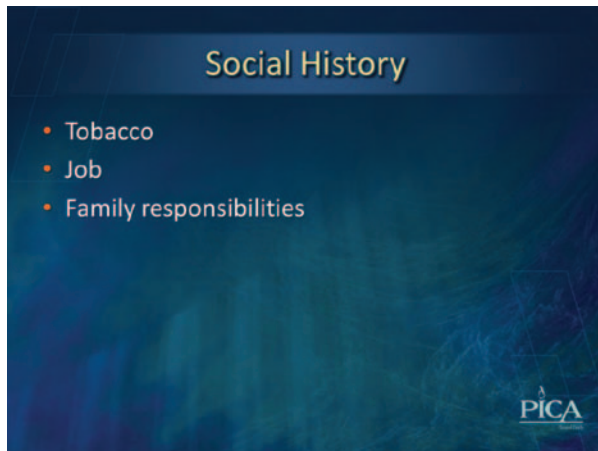


Figure 13.

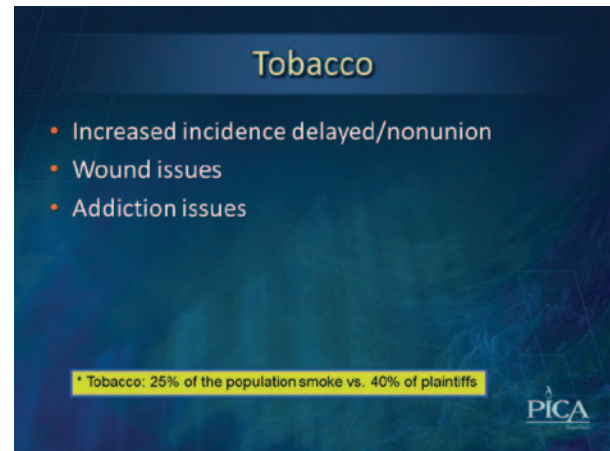


Figure 14.

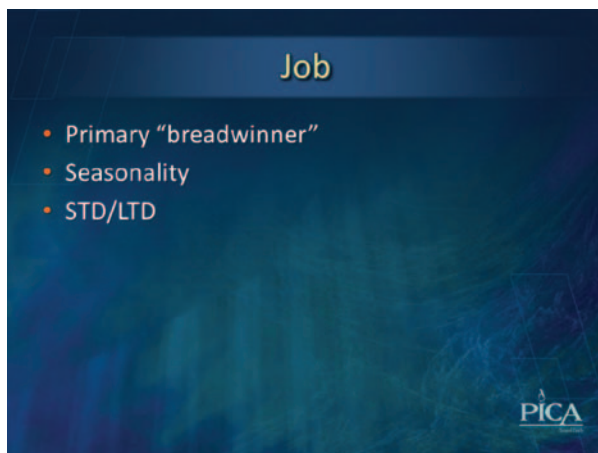

Figure 15.

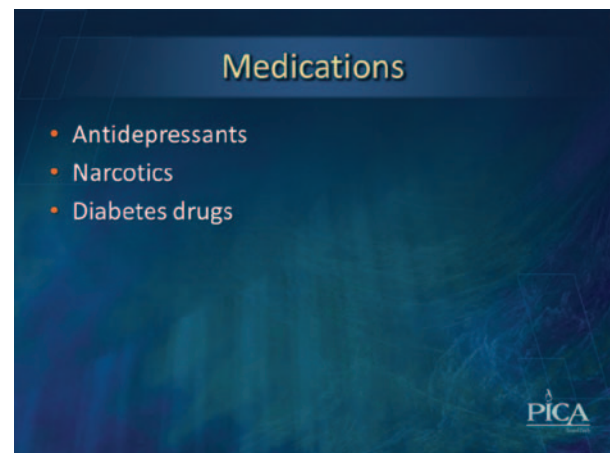


Figure 16.

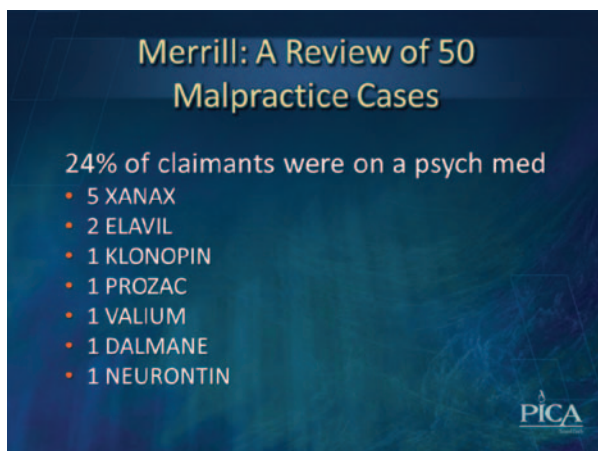


Figure 17.

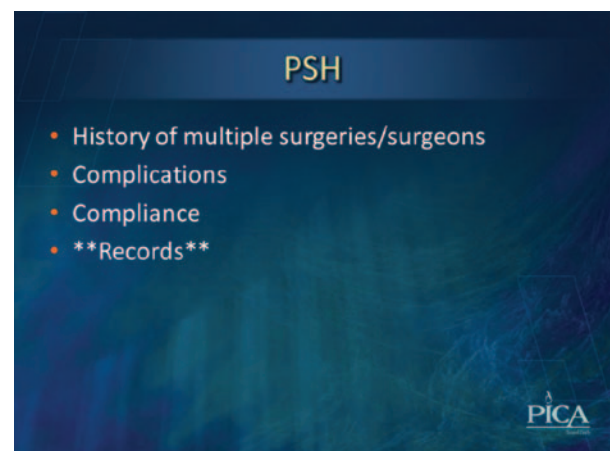

Figure 18.

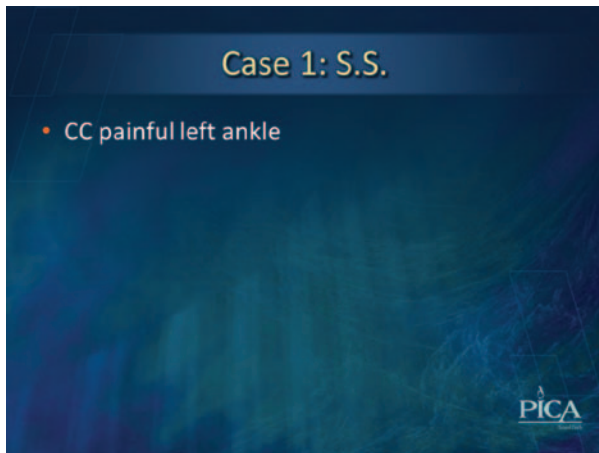

Figure 19.

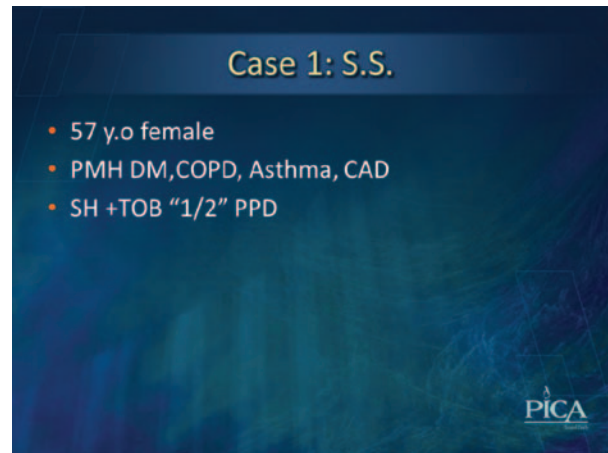


Figure 20.

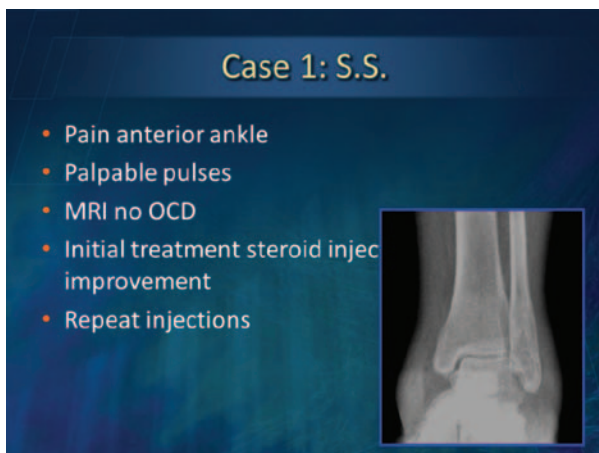

Figure 21.

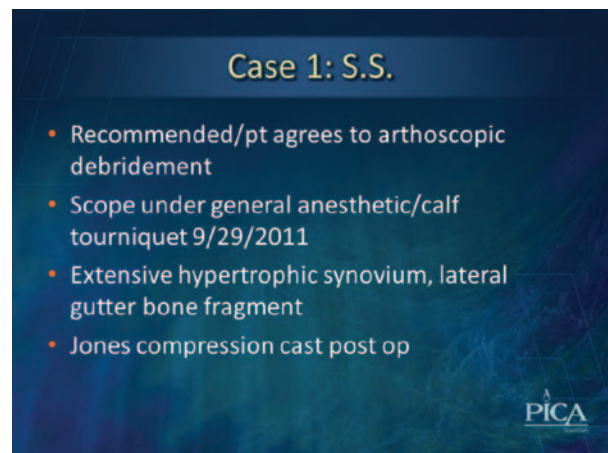


Figure 22.

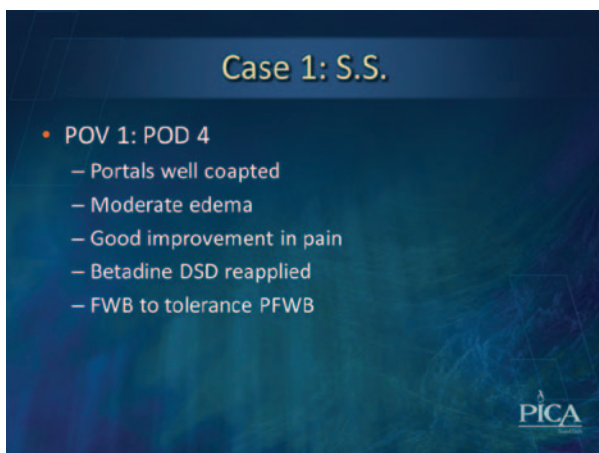


Figure 23.

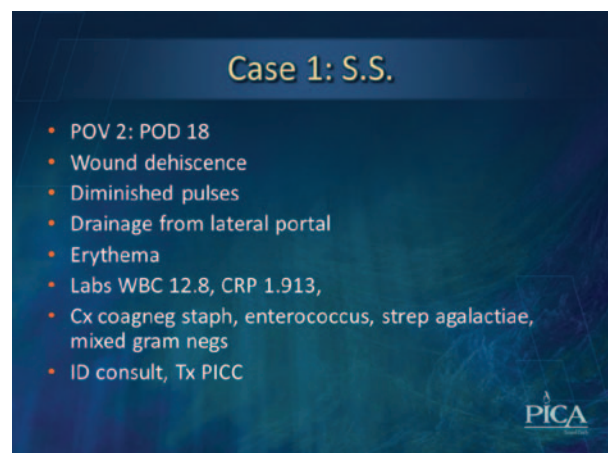


Figure 24.

Case 1: S.S.

- PO 4 weeks/1week IV's
- Continued purulent drainage lateral incision/extensor tendon sheath area
- Hospital admission/I&D




Figure 25.

Case 1: S.S.

- Primary closure
- Dehiscence
- VAC application
- Continued IV ABX




Figure 26.

Case 1: S.S.




Figure 27.

Case 1: S.S.

- Primary closure
- Dehiscence
- VAC application
- Continued IV ABX






Figure 28.

Case 1: S.S.

- Continued LWC
- Long term IV ABX
- Continued referrals/communication w/ vascular/cardiology
- neuritis
- Very slow wound progress
- Continued tobacco abuse despite counseling




Figure 29.

"Reassessment Time"






Figure 30.

Case 1: S.S.

- Continued LWC
- Long term IV ABX
- Continued referrals/communication w/ vascular/cardiology
- neuritis
- Very slow wound progress
- Continued tobacco abuse despite counseling




Figure 31.

Case 1: S.S.



6 mo S/P Arthroscopic Debridement



Figure 32.

Case 1: S.S.



4 mo postop



Figure 33.

Case 1: S.S.

- Wounds closed
- Persistent pain
- Intolerance to OTS bracing
- Nerve entrapment
- Pain management
- Narcotics, topicals
- 2 subsequent spontaneous breakdowns
- Adverse Rxn gabapentin and pregabalin
- Tx topical neuropathic cream (compounded)
- NS/Cx PM appts




Figure 34.

Case 1 S.S.

- Persistent chronic pain
- Aggravated weather change
- Pain with WB
- Continues manament w/ narcotics, custom AFO




Figure 35.

Case 1 S.S.



11 mo post arthroscopy



Figure 36.

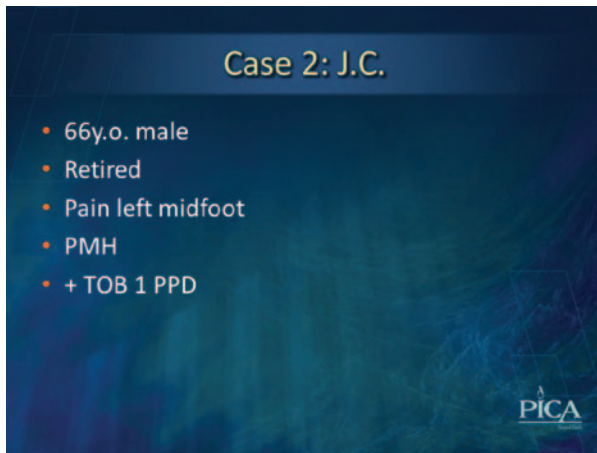


Figure 37.

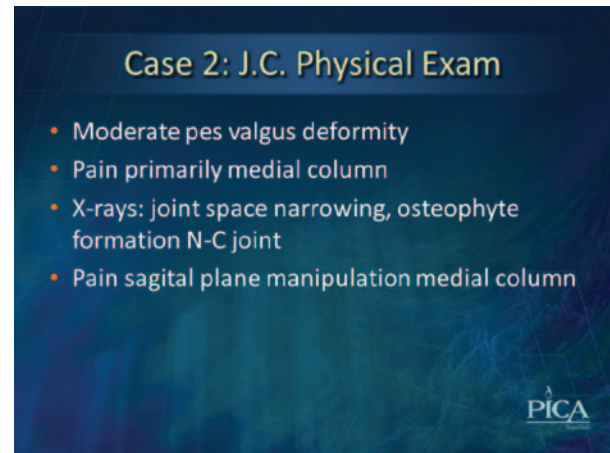


Figure 38.

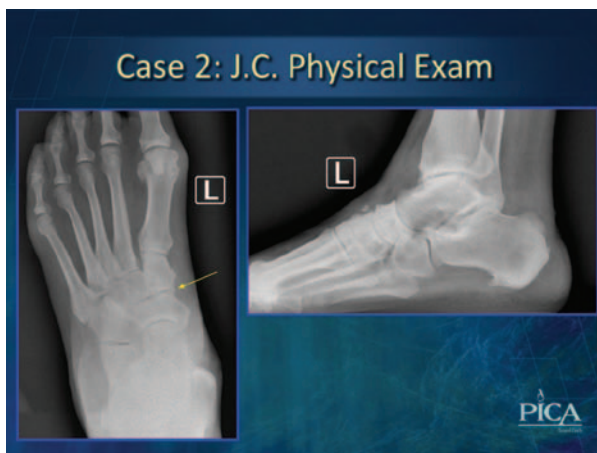

Figure 39.

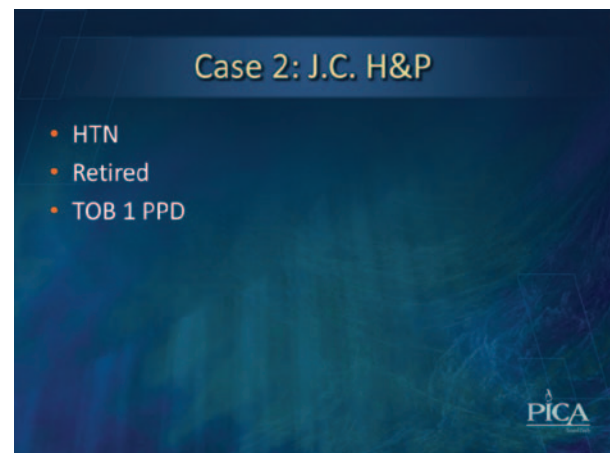


Figure 40.

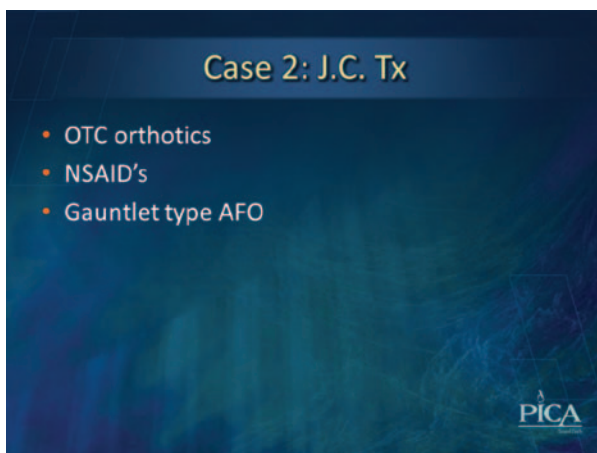


Figure 41.

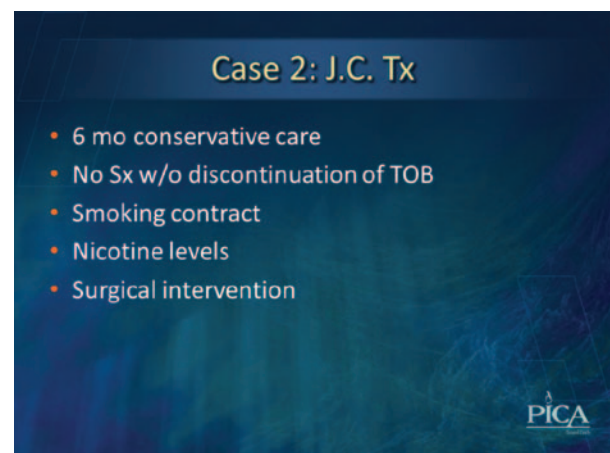


Figure 42.

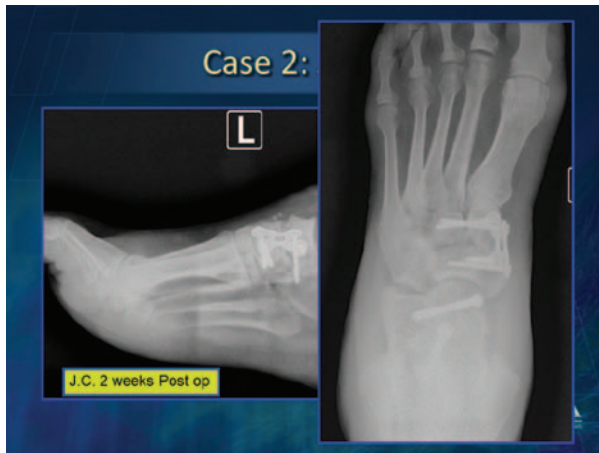

Figure 43.

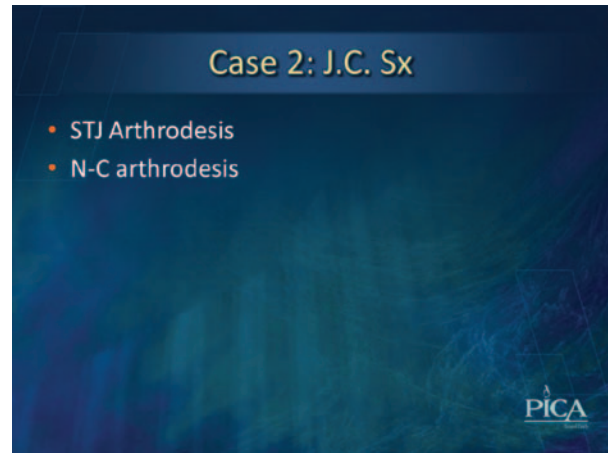


Figure 44.

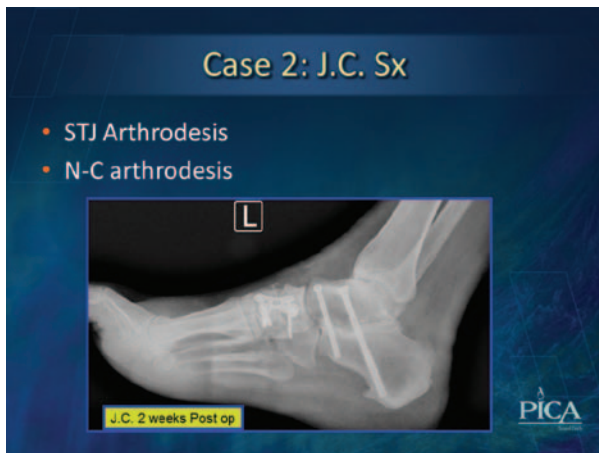

Figure 45.

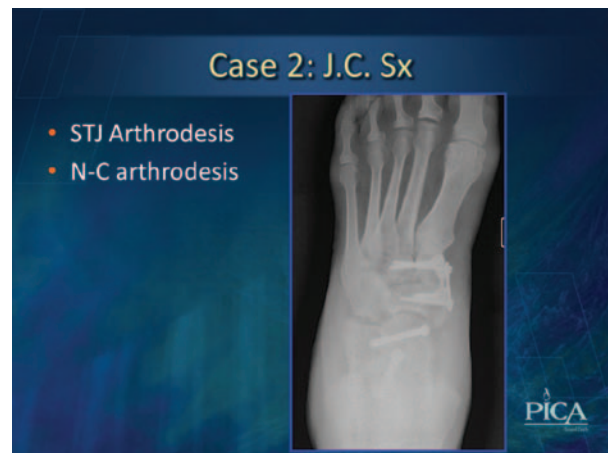

Figure 46.

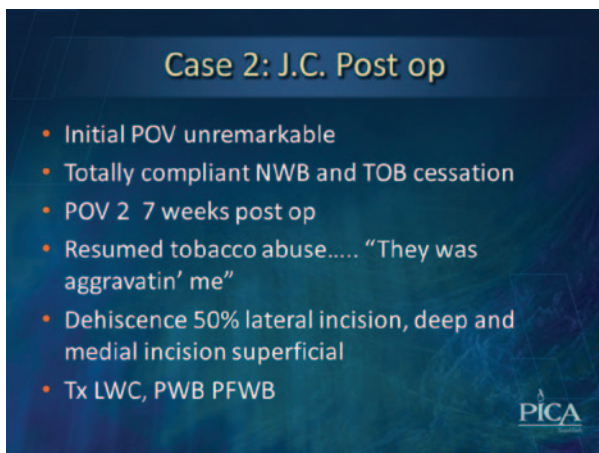


Figure 47.

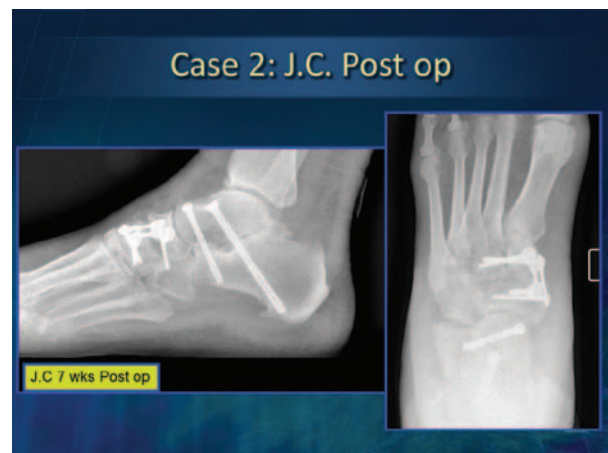

Figure 48.

Case 2: J.C. Wound

- Initial Tx Silvadene
- Subsequent VAC Tx
- Amniox graft placement, tissue biopsies
- Subsequent cx results show Pseudomonis. - markers
- IV abx
- F/U Amniox, tissue cx
- Recurrent Pseudomonas + cx, no clinical signs infection
- Tx acetic acid/h₂o soaks




Figure 49.

Case 2: J.C. Wound

Test Name	In Range	Out Of Range	Reference Range
SDS RATE BY MODIFIED WESTERBLOM	2		< 20 = 20 nm/h
CBC (INCLUDES DIFF/PLT)	5.7		3.8-10.8 Thousand/uL
WHITE BLOOD CELL COUNT	4.72		4.20-10.80 Million/uL
RED BLOOD CELL COUNT	15.6		13.2-17.1 g/dL
HEMOGLOBIN	45.6		20.3-30.0 g/dL
HEMATOCRIT	90.7		27.0-33.0 g/dL
HCV	13.5		12.0-16.0 g/dL
HCMC	144		11.0-15.0 f
RDW	2298		140-400 Thousand/uL
PLATELET COUNT	1442		1500-3800 cells/uL
ABSOLUTE LYMPHOCYTES	530		800-3800 cells/uL
ABSOLUTE MONOCYTES	105		100-850 cells/uL
ABSOLUTE EOSINOPHILS	29		15-500 cells/uL
ABSOLUTE BASOPHILS	57.8		0-300 cells/uL
NEUTROPHILS	24.3		
LYMPHOCYTES	9.3		
MONOCYTES	7.1		
EOSINOPHILS	2.5		
BASOPHILS	0.14		

4 mo postop

C-REACTIVE PROTEIN
Please be advised that patients taking Carbapenem antibiotics may exhibit falsely decreased C-reactive protein levels due to an analytical interference in this assay.




Figure 50.

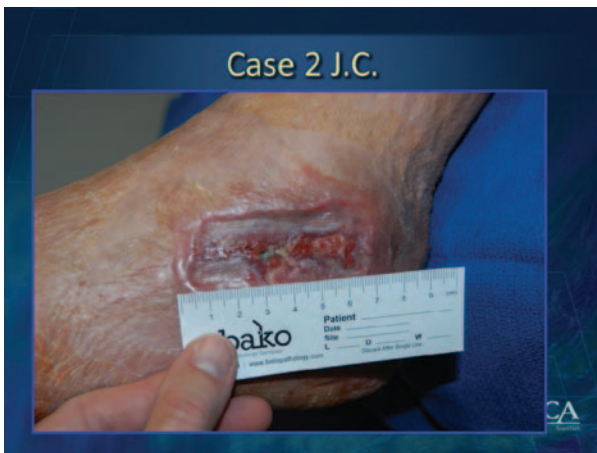

Figure 51.

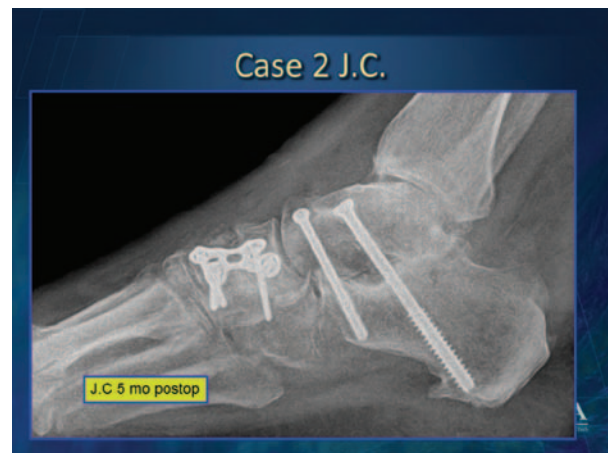

Figure 52.

Case 2: J.C. Outcome

- Wounds closed @ 6 mo
- Full consolidation arthrodesis sites
- Never any evidence of deep infection
- Good relief of preop symptoms
- Some persistent edema




Figure 53.

Case 3: B.C.

- 35 y.o. female
- Married, 4 children
- 2 jobs, both requiring extended standing
- 2 year hx b/l foot pain
- Soc Hx significant for cocaine abuse and "more than one" stay in rehab.




Figure 54.

Case 3: B.C.

- Dx plantar fasciitis and metatarsalgia
- Visit 2 Pt. improved
- Visit 4 Pt c/o sig. pain
- Visit 1 Tx Rx Naprosyn & Ultracet
- Visit 2 Tx injected 2nd and 3rd interspaces B/l
- Visit 3 heels injected
- Visit 4 Tx injection steroid and sclerosing ETOH
- 1 week later "pt stated she wanted surgery"




Figure 55.

Case 3: B.C.

- Sx performed left
 - Plantar fascia release
 - Excision neuromas 2nd, 3rd and 4th IS's
- Rx's Oxycontin 20mg (30), Lorcet 10 (40)




Figure 56.

Case 3: B.C.

- Right foot sx, 5 months later
 - Plantar fascia release
 - Excision neuromas 2nd, 3rd and 4th
- Same narcotic regimen continues (Oxycontin 40 and Percocet 7.5)




Figure 57.

Case 3: B.C.

- Recovery slow
- Some difficulty with hypertrophic scars
- Referral to pain management @ 3 ½ months
- Appt 2 months later
- Dx neuropathic pain, Rx Methadone
- After PM eval/Tx Dr gives 2 additional refills




Figure 58.

Case 3: B.C. Questions??

- Was B.C. a good surgical candidate?
- Was a reassessment done?
- Were referrals made in a timely fashion?
- Tx's appropriate?




Figure 59.

Red Flags



- Subjective concerns w/o objective findings
- Patients demanding surgery when not indicated
- History of non-compliance
- Doctor hopping
- History of unsuccessful surgeries
- The flatterer



Figure 60.

How to say "NO"

- Trust your gut
- Refer to colleague/competitor
- Stress positive nature of getting the pt to another provider




Figure 61.

Informed Consent

- Complete
- Honest
- Promote realistic expectations
- Honest discussion of complications
- Visual aids
- Take time to listen and hear what the patient's goals of tx are
- Written and verbal



Figure 62.

Literature

Foot & Ankle International
Copyright © 2005 by the American Orthopaedic Foot & Ankle Society, Inc.

Recall of the Risks of Forefoot Surgery After Informed Consent

Paul S. Shuman, M.D.¹; Michael J. Coughlin, M.D.¹
Murray Hill, NJ, USA; ID



Figure 63.

Case 4: H.L.

- Initial eval Jan 2005
- 57 y.o. female
- Cc painful bump 1st MPJ LT
- Dx HAV with limitus
- PMH: Breast Ca, HTN
- Meds: Plendil, Ambien, diuretic




Figure 64.

Case 4: H.L.

- Surgical correction April 27, 2005
- "Bicorrectional Austin w/ Hemi"



Figure 65.

Case 4: H.L.

- Surgical correction April 27, 2005
- "Bicorrectional Austin w/ Hemi"
- Subsequent fracture 2nd
- Tx boot, stim, analgesics,




Figure 66.

Case 4: H.L.

- Later tx for neuroma LT 2nd IS
- Returns 3 years post w/ co contracted LT big toe
- Revision w/ removal implant and 1st MPJ arthrodesis




Figure 67.

Case 4: H.L.

- Returns 2 years later
- Toe has “popped up”
- Pain IPJ and MPJ
- “destruction dorsal 1st metatarsal”
- Recommends hardware removal, IPJ and MPJ arthrodesis




Figure 68.

Case 4: H.L.

- Sx: hardware removed
- Bone soft/nonviable
- Arthrodesis no longer possible
- Amputates toe
- No signed consent




Figure 69.

"Reassessment Time"

The “Former” patient becomes a “New” patient again...



Figure 70.

"Reassessment Time"

The “Former” patient becomes a “New” patient again...

...schedule an office consult for the patient with you!



Figure 71.

"Reassessment Time"

The “Former” patient becomes a “New” patient again...

Time



Figure 72.

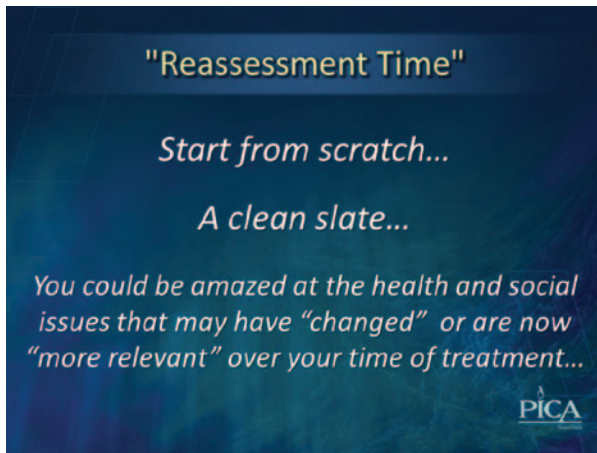

Figure 73.

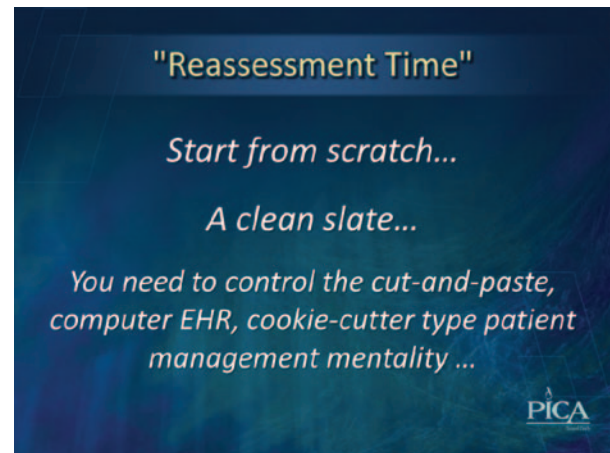

Figure 74.

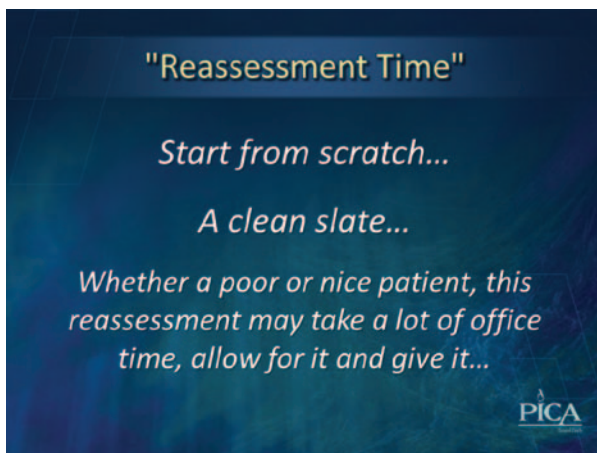


Figure 75.

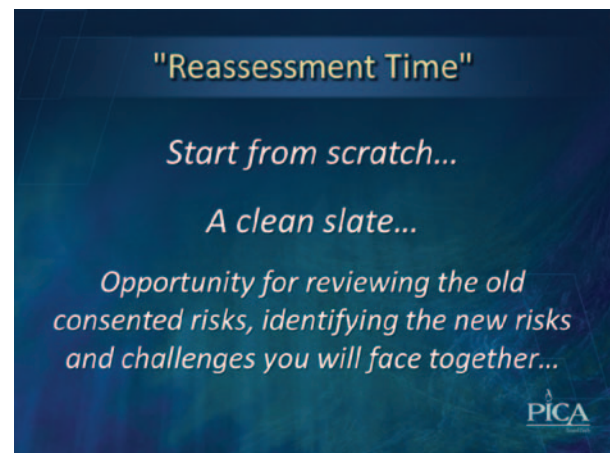

Figure 76.

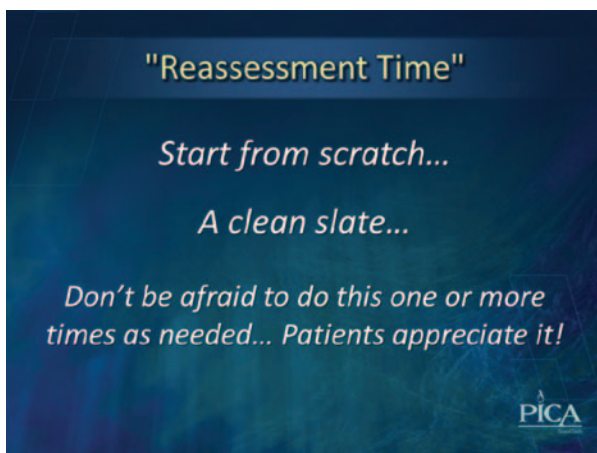


Figure 77.

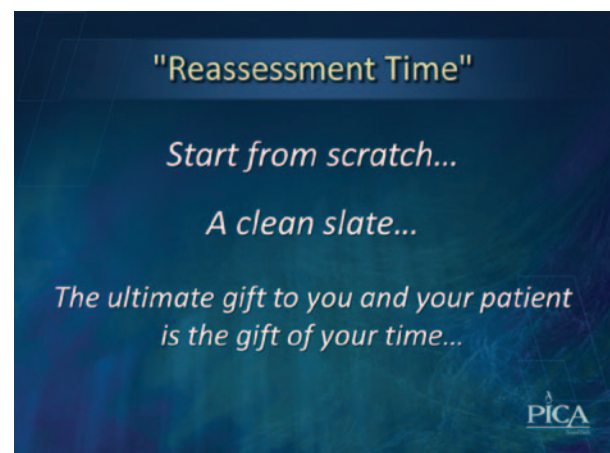

Figure 78.

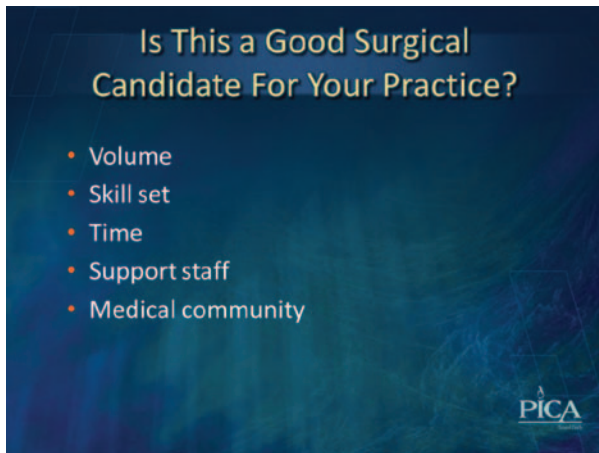

Figure 79.

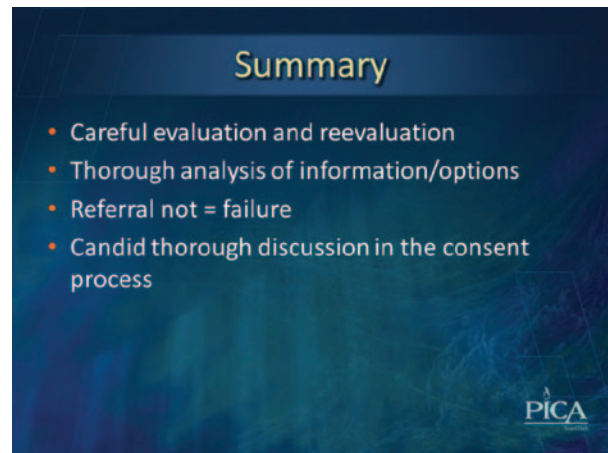


Figure 80.

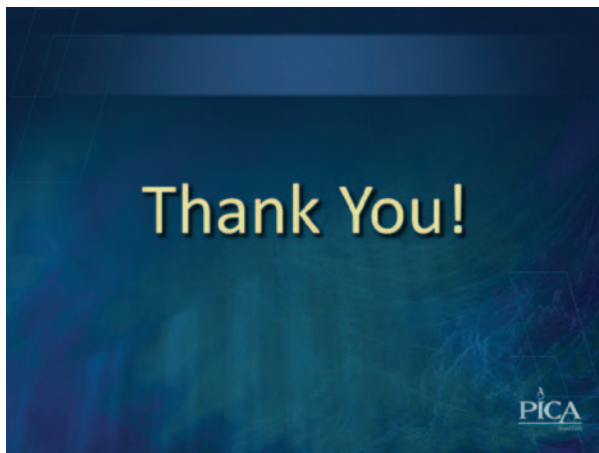


Figure 81.