

# PEDIATRIC ANKLE FRACTURES

*Sofie Pinney, DPM, MS*

### INTRODUCTION

The purpose of this review is to examine the current literature on pediatric ankle fractures. I will discuss the anatomic considerations of a pediatric patient, how to evaluate and manage these fractures, and when to surgically repair them. Surgical techniques and complications will be briefly reviewed.

Ankle fractures are the third most common fractures in children, after the finger and distal radial physeal fracture. Approximately 20-30% of all pediatric fractures are ankle fractures. Most ankle fractures occur at 8-15 years old. The peak injury age is 11-12 years, and is relatively uncommon under the age 5. This injury is more common in boys. The most common cause of pediatric ankle fractures is a rotational force, and is often seen in sports injuries associated with sudden changes in direction (1).

### ANATOMY

Pediatric ankle fractures must be considered separately from adult ankle fractures, namely because of the special anatomy and the ramifications of mistreating this injury. The long bone anatomy is unique because of the epiphyseal plate, the disk of cartilage between the metaphysis and epiphysis, which permits length-wise growth. Growth is primarily longitudinally and occurs enchondrally, via latitudinal growth centers in the periphery. Histology is important for understanding the overall prognosis. The epiphysis contains the germinal layer of the cartilage, and the cartilage cells grow from the epiphysis towards the metaphysis, with neovascularization occurring in the opposite direction. Damage to either the epiphyseal or metaphyseal vascular supply disrupts bone growth. However, damage to the layer of cartilage may not be significant if the surfaces are reopposed, and vascular supply to the growing cartilage is not permanently interrupted. The cartilage functions as a shock absorber. The distal tibial physis permits about 40% of tibial growth, approximately 3-4 mm per year. There is minimal longitudinal growth after the age of 12 in females and 14 in males (1-3).

The immature bone is less dense and more porous, with a thicker, stronger periosteum. There is a low modulus of elasticity relative to adult bone. Failure can occur as a result of both tension and compression injuries. The epiphysis is rarely injured in younger children, but risk increases with age. The ligaments are distally attached to the physis and are

stronger than both the physis and bone. As a result, there is a greater capacity for plastic deformation and less chance of intra-articular fractures, joint dislocation, and ligamentous disruptions. However, ligamentous injury may be more common than originally believed (1). A case-control study by Zonfrillo et al found an association between an increased risk of athletic injury in obese children, and concluded a higher body mass index risk factor for ankle sprains (4).

Secondary ossification centers are located in the epiphysis. The distal tibial ossification center appears at 6-24 months of age and closes asymmetrically over an 18-month period first central, then medial and posterior, with the anterolateral portion closing last at 15 and 17 years of age for females and males, respectively. The distal fibula ossification center appears at 9-24 months of age and closes 1-2 years after the distal tibial. The fibular growth plate should be at the same level as the ankle joint on an anteroposterior radiograph. Accessory bones are uncommon but can be present; the os subtibiale appears in 0.9-20% and os subfibulare in 2.1% of the population (1).

### DIAGNOSIS

In order to diagnosis a pediatric ankle fracture, the physician must take a good history including age of the patient, body hiatus, activity and position at the time of injury. The physical examination can present with edema, ecchymosis, and skin tenting, with limited range of motion and point tenderness over the growth plate. First line imaging includes standard plain film radiographs. It is important to take contralateral views. Stress views are not recommended because they are unlikely to change the overall treatment, can be uncomfortable, and cause increased radiation to the child. Computed tomography (CT) and magnetic resonance imaging (MRI) can be utilized, especially for surgical planning. Horn et al compared CT scans with plain film radiographs in cadaver models of juvenile Tillaux fractures. He found that both imaging modalities were accurate within 1 mm 50% of the time. However, the CT was more sensitive if the fracture was displaced >2 mm. He concluded that thee CT improved the ability to accurately plan screw placement for triplane fractures (5).

In contrast, the MRI has been shown to provide better soft tissue, fine bone detail and does not radiate the patient. Carey et al reviewed 14 patients and identified an occult fracture when compared to plain film radiographs, which did change management of 5/14 patients (6).

Petit et al evaluated 29 patients and only 1 patient was misclassified when compared to plain film radiographs but the treatment did not change (7, 8). In conclusion, the MRI is recommended to identify occult fractures, assess for premature physal closure, or identify the source of persistent pain after a fracture has healed.

## FRACTURE CLASSIFICATION

There are several classification systems used in relation to ankle fractures. Salter Harris (SH) is the most commonly utilized pediatric ankle fracture classification. Introduced in 1963, it separated fractures in relation to the physis into five unique fracture patterns, but did not take into account the mechanism of injury. The Dias and Tachdjian classification correlates the Salter Harris with Lauge-Hansen. It is based on the mechanism of injury, which looks at the foot position at the time of injury and the direction of force, in order to guide fracture reduction (Figure 1).

A Salter Harris type I fracture is often misdiagnosed as a pediatric ankle sprain. About 6-15% of pediatric ankle fractures are this type, with 10.5 years old being the average age of incidence. It is an open growth plate fracture. It is important to repeat radiographs at 1 week to check for displacement. This is a stable fracture and unlikely to result in growth arrest, because although the physal width is increased, known as “slipped epiphysis,” the growing zone is undisturbed. Treatment includes immobilization for 3-4 weeks in a below knee cast, then transition to a walking boot.

The most common type of pediatric ankle fracture, which accounts for 75% of physal injuries, is a Salter Harris II. This injury occurs in a fixed supination, external rotation position and involved fracture of the physis and up through the metaphysis. Growth arrest is possible. But shortening is minimal and rarely results in functional limitations. There are numerous articles that discuss the premature physal closure rate. For example, Raman et al 22-36%, Leary et al 25%, Barmada et al 17% if <3 mm displacement after reduction (1). There is also some controversy on acceptable reduction. Spiegel et al showed that there is an increased inability to reduce a fracture if the patient is over 12 years (1). Phieffer et al concluded that in a rat model, significant ( $P < 0.05$ ) physal bar formation and leg length discrepancy was noted in the group with interposed periosteum (1). It is recommended that nondisplaced fractures be immobilized 3-4 weeks then transitioned to weightbearing in a boot for 2-3 weeks. Displaced fractures treated with open reduction internal fixation (ORIF) resulted in the lowest residual displacement (1-3).

A fracture of the physis and lower through the epiphysis, which accounts for 8% of pediatric ankle fractures is a Salter Harris III. It occurs with high energy, supination

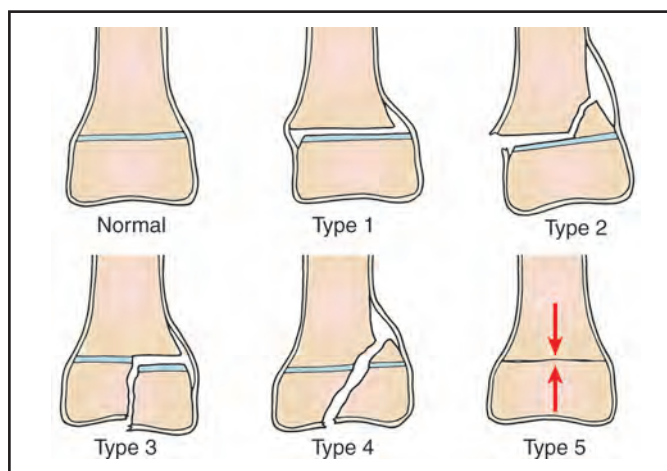


Figure 1. Salter Harris Classification system.

inversion injuries at an average age of 8-12 years. There is the potential for growth arrest because of damage to the articular surface. The nondisplaced fractures are treated with a short leg cast. The displaced fractures, however, require ORIF because the most “accurate and perfect” reduction yields the most favorable prognosis. Kling et al’s study said there is less chance of premature physal closure ( $P = 0.027$ ) with accurate reduction. Leary et al concluded if there is >2 mm displacement, then treatment with ORIF would reduce the premature closure rate to only 13% (1-3).

About 10% of pediatric ankle fractures cross through the epiphysis, physis and metaphysis. The Salter Harris IV is prevalent in 8-11 year olds. Treatment of this type is the same as SH III. Surgery is used to obtain anatomic reduction. Cottalorda et al treated this fracture pattern with open arthrotomy, reduction under direct visualization, then screw pin fixation (1). The risk of partial growth arrest was increased if the fracture was intra-articular. Chronic disability resulted if the fragment displaced, which could cause premature focal fusion and deformity.

Salter Harris V is a compression injury, which is very rare, representing only about 1% of cases. It is difficult to diagnosis because pain and swelling are usually the only symptoms. There is no specific algorithm for treatment. Unfortunately, there is a high risk of growth arrest for this “crush” fracture, namely because the fracture is missed on radiographs, as it appears as a “raised epiphysis” (1).

Described by Rang in 1969, the Salter Harris VI is an open injury with physal loss. It presents as a peripheral bruise, burn, or perichondrial ring avulsion. There can be growth problems if there is premature physal closure. The most common cause of this pattern is a lawn-mower injury. If the fracture is closed and minimally displaced, no surgery is warranted. If there is an open fracture, then antibiotics, tetanus, irrigation and debridement are needed with possible soft tissue reconstruction depending on the amount of damage and tissue loss.

Other rare Salter Harris fracture patterns have been described but are not commonly used today. Described by JA Ogden in 1982, Type VII is an isolated injury to the epiphyseal plate. Type VIII is an isolated injury to the metaphysis, with possible injury related to endochondral ossification. Lastly, Type IX is an injury to the periosteum, which may interfere with membranous growth.

## TRANSITIONAL FRACTURES

The Juvenile Tillaux is a transitional fracture, often described as a SH III. The distal tibial physis ossification closes central medial to anterolateral. If an external rotation injury occurs during the 18-month closure period, the AITFL avulses epiphyseal fragment. Surgery is needed to address the articular incongruity. The surgery can be arthroscopically assisted and often a single screw parallel to the physis is utilized for fixation (1, 9, 10) (Figure 2).

The second transitional fracture is the Triplane fracture. It is relatively uncommon, accounting for 6% of physeal injuries and occurring in adolescents, typically around 13 years old. An external rotation injury creates a 3-part fracture: a rectangular fragment of distal tibial physis, a large fragment of epiphysis with a metaphyseal spike, and the tibial shaft. This fracture requires a CT because on plain film radiographs the AP view appears to be a SH III, but the lateral view appears as a SH II, IV. The risk for growth arrest is high because it takes time to occur and angular deformity and shortening can result from this injury. Minimally displaced and extra-articular fractures are treated by reduction and long leg immobilization. If >3 mm of initial displacement or >2 mm of residual intra-articular step off, then closed reduction and surgery is the preferred treatment. Surgery includes ORIF or arthroscopically assisted reduction with percutaneous fixation (9-12).

## CONTROVERSY IN FRACTURE CARE

Once the fracture pattern is understood, it can be more effectively diagnosed and treated. However, there is some controversy in pediatric fracture care. The Ottawa Ankle Rules (OAR) are a set of clinical decision rules derived for use in adults with acute ankle and midfoot injuries. The Emergency Department will utilize the OAR to exclude fractures and reduce unnecessary imaging. Clark et al evaluated ankles in 195 patients, average age of 12.6 years. His study concluded that OAR cannot be applied to children (13, 14). Dowling et al, evaluated patients and concluded OAR is a reliable tool to exclude fractures in children over 5 years old (13, 14). With the threat of

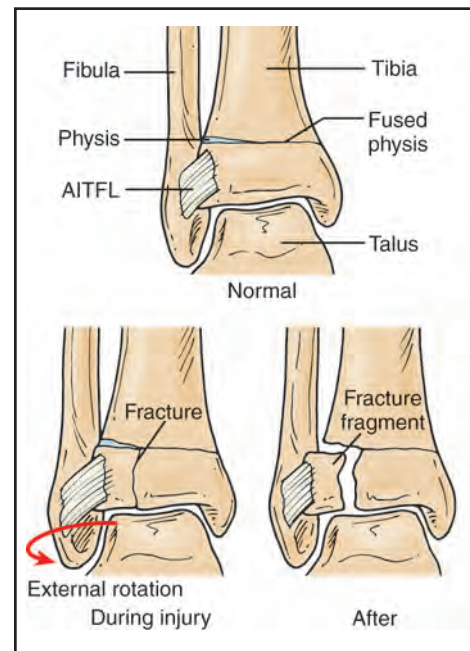


Figure 2. Tillaux fracture

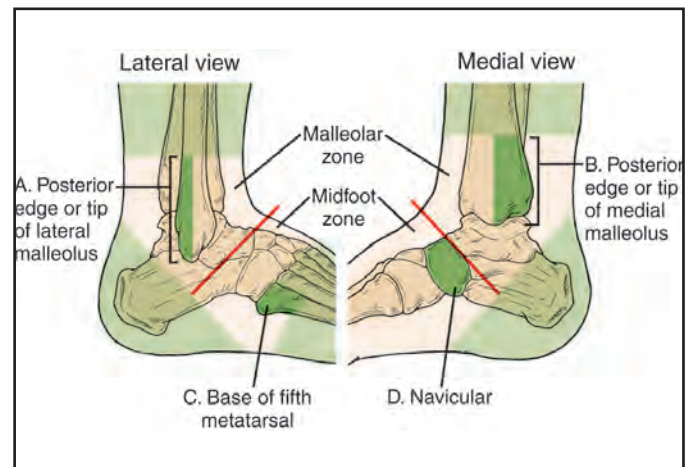


Figure 3. Ottawa Ankle Rules

legal repercussions hanging over a physician, is it worth it to chance not obtaining radiographs and missing this injury? The relevance of early diagnosis is critical. Patients with a delay in presentation had more significant growth disturbance patterns. A delay in presentation of greater than 24 months resulted in angular deformities in 92% of those patients. A delay less than 24 months resulted in 33% of patients having deformity. Overall, patients with angular or linear deformities are more likely to be male, present late, have high-energy injuries, or with a Salter Harris IV-V. In conclusion, early diagnosis and treatment of growth disturbance can prevent severe deformity (15) (Figure 3).

## TREATMENT

Once a patient presents and a diagnosis is made, treatment is initiated. Closed reduction can be done with IV sedation or general anesthesia. It is recommended to limit to 1-2 attempts. Cast immobilization is performed and the decision is made whether to proceed with surgery. The decision for surgery or not is based on the fracture type, the amount of displacement, and the ability to restore and maintain alignment of the physis and ankle congruity. Schurz et al reported all displaced fractures need surgery, regardless of the patient's age (1). Siegel et al reviewed 237 fractures and concluded that if there is >2 mm gap within the growth plate then ORIF is necessary (1). Kling et al showed that 85% patients with >2 mm gap exhibited growth arrest if treated with only closed reduction (1). Based on results such as these, the "2 mm rule" is often utilized as a way to guide surgical treatment (1, 12).

If surgical treatment is warranted, there are some general principles that should be observed in the treatment of pediatric ankle fractures. First is the importance of anatomic reduction and to avoid growth plates, in order to minimize the risk for future arthritis and growth arrest. Adequate fixation is used but only as necessary. Fixation that can be easily removed is preferred. Internal fixation should be in the epiphyseal or metaphyseal regions, and should be parallel to the physis when possible. If it is necessary to transverse the physis, use smooth Kirschner wires and avoid threaded pins.

Open reduction internal fixation allows for reduction under direct visualization. There are a variety of internal fixation options. Kirschner wires, small fragment metallic screws, or transepiphyseal screws can all be utilized. Bioabsorbable fixation is also an option. It is more expensive, but does obviate the need for a second surgery to remove the hardware. Screw removal is beneficial in children. If an acceptable closed reduction is obtained, percutaneous fixation can be utilized. This technique reduces the morbidity associated with an extensive surgical approach, which decreases wound complications and increases the return to activity time. Arthroscopic reduction is also known as arthroscopically assisted percutaneous fixation. This technique reduced the need for open surgery, while allowing for direct visualization of the tibial plafond. The extent of articular surface fracture can be assessed, and so can the accuracy of the closed reduction. There is a more rapid return to mobility and function. Postoperative protocol includes a below knee cast for 2 weeks, followed by a removable splint and starting range of motion exercises. Typically the patient is completely non-weightbearing for 6 weeks.

## COMPLICATIONS

Complications of pediatric ankle fractures can include osteochondral defects, compartment syndrome, and growth arrest. Long-term follow-up is critical in this patient population. Osteochondral defects are increasingly more commonly diagnosed and present as persistent pain following ankle injury. MRI is recommended to evaluate the cartilage and osseous detail. Open or arthroscopic surgery is performed for stabilization, microfracture, or drilling. Compartment syndrome can result from trauma, especially crush injuries. In the pediatric patient, extensor retinaculum syndrome is a unique form in that there is severe ankle pain, swelling, hypoesthetic first web space, weakness of EHL, ED, and pain with passive toe flexion. Extensor retinaculum release is the treatment. Growth arrest is a very serious complication. Typically, physeal arrest is recognized 3-6 months after injury. This is why it is important to follow the pediatric patient up to 2 years after injury or until skeletal maturity. The growth arrest occurs secondary to a bony bridge from the metaphysis to epiphysis. The amount of deformity depends on the size and location of bridge. The magnitude of deformity depends on how much growth is left. Deformity can be either an angular deformity or limb-length discrepancy. Complete growth cessation is possible but uncommon (1, 15).

Partial growth arrest can occur in 3 patterns. Type I is the most common and presents as a peripheral bar, which produces an angular deformity. Type II is a central bar, which results in tenting of physis and epiphysis leading to articular surface distortion. Type III is a linear bar involving the peripheral and central physis. It usually results from a displaced SH IV. This type results in intraarticular incongruity and progressive angular growth. A diagnosis of physeal arrest is made from close radiographic follow up. There can be blurring and narrowing of the physis, reactive bone condensation, or distortion of the metaphyseal growth region. Asymmetric Harris line is a sclerotic line in the metaphysis, which appears 6-12 months after the fracture. It should be parallel to and extend across the entire width of physis. Advanced imaging, such as CT and MRI are used to rule out "secondary tethers" or incomplete bar resection or recurrent bars. The treatment of physeal arrest is to convert a partial arrest to complete arrest. A contralateral limb epiphysiodesis can be performed. Limb-lengthening of the affected side can be considered if the discrepancy is >5 cm. Bar resection is recommended if more than 2 years of growth remain and <50% physis is damaged (1, 15).

In conclusion, pediatric ankle fractures are unique injuries and should be treated in a timely and precise fashion in order to avoid the long-term complications that can ensue

from misdiagnosis or a neglected fracture. Salter Harris II is the most common type. Overall, nondisplaced fractures can be immobilized. In contrast, displaced fractures or an articular step off of greater than 2 mm should be closed reduced, followed by ORIF. All pediatric ankle fractures should have radiographic follow-up for 2 years or until skeletal maturity.

## REFERENCES

1. Blackburn E, Aronsson D, Rubright J, Lisle J. Ankle fractures in children. *J Bone Joint Surg Am* 2012;94:1234-44.
2. Peterson HA, Madhok R, Benson JT, et al. Physeal fractures: Part 1. epidemiology in Olmsted County, Minnesota, 1979-1988. *Pediatr Orthop* 1994;14:423-30.
3. Peterson CA, Peterson HA. Analysis of the incidence of injuries to the epiphyseal growth plate. *J Trauma* 1972;12:275-81.
4. Zonfrillo MR, Seiden JA, House EM, et al. The association of overweight and ankle injuries in children. *Ambul Pediatr* 2008;8:66-9.
5. Horn BD, Crisci K, Krug M, et al. Radiologic evaluation of juvenile Tillaux fractures of the distal tibia. *J Pediatr Orthop* 2001;21:162-4.
6. Carey J, Spence L, Blickman H, Eustace S. MRI of pediatric growth plate injury: correlation with plain film radiographs and clinical outcome. *Skeletal Radiol* 1998;27:250-5.
7. Petit P, Panuel M, Faure F, et al. Acute fracture of the distal tibial physis: role of gradient-echo MR imaging versus plain film examination. *AJR Am J Roentgenol* 1996; 166:1203-6.
8. Lohman M, Kivisaari A, Kallio P, et al. Acute paediatric ankle trauma: MRI versus plain radiography. *Skeletal Radiol* 2001; 30:504-11.
9. McGillion S, Jackson M, Lahoti O. Arthroscopically assisted percutaneous fixation of triplane fracture of the distal tibia. *J Pediatr Orthop B* 2007;16:313-6.
10. Masquijo J. Percutaneous plating of distal tibial fractures in children and adolescents. *J Pediatric Orthopaedics B* 2014;1:1-5.
11. Hinds R, Lazaro L, Burket J, Lorich D. Risk factors for posttraumatic synostosis and outcomes following operative treatment of ankle fractures. *Foot Ankle Int* 2014;35:141-7.
12. Crawford A. Triplane and Tillaux fractures: is a 2 mm residual gap acceptable? *J Pediatr Orthop* 2012;32:69-S73.
13. Dowling S, Spooner S, et al. Accuracy of Ottawa ankle rules to exclude fractures of the ankle and midfoot in children: a meta-analysis. *Acad Emerg Med* 2009;16:277-87.
14. Clark K, Tanner S. Evaluation of the Ottawa Ankle Rules in children. *Pediat Emerg Care* 2003;19:73-8.
15. Berson L, Davidson, et al. Growth disturbances after distal tibial physeal fractures. *Foot Ankle Int* 2000;21:54-8.