

# Plantar Incision Approach for Hammertoe Correction

*Jacqueline Brill, DPM*

*Raymond J. Lopez, DPM*

*Brian Asencio, DPM*

*Thomas Merrill, DPM*

## INTRODUCTION

Hammertoe deformities are a common pathology of patients presenting with forefoot pain. Perhaps because of cosmetic and shoe-wearing issues, the deformity is reportedly more common in women than men. Hammertoe deformities are found in men as well, especially in those with certain predisposing factors such as an associated elongated metatarsal, metatarsophalangeal joint synovitis and instability, inflammatory arthropathies, neuromuscular conditions, and ill-fitting shoe gear (1-3). The biomechanical influences that disrupt the intrinsic balance of muscle insertions into metatarsals and phalanges, which leads to the deforming forces contributing to digital contracture, has been well-established in the literature (4,5).

To review, there are 3 main biomechanical mechanisms of development for hammertoe contracture. The most common etiology is flexor stabilization. This type of hammertoe contracture results from abnormal excessive pronation during the stance phase of gait. The posterior leg muscles contract earlier and longer than normal, creating a mechanical disadvantage of the normally stabilizing interossei muscles, leading to pathological contracture. In addition, with the long flexors gaining a mechanical advantage over the intrinsic musculature, the quadratus plantae muscle also loses its ability to straighten the oblique course of the long flexor tendon, which results in the classic finding of the adductovarus contracture of the fourth and fifth digit.

The next most commonly encountered digital contracture is described as extensor substitution. This type of contracture is associated with an equinus type of gait in which the gastrocnemius and soleus muscles are contracted leading to a tight heel cord. As a result, the anterior leg muscles must assist the ankle in dorsiflexion to oppose the contracted Achilles tendon leading to a mechanical advantage over the lumbrical muscles of the foot, resulting in excessive metatarsophalangeal joint hyperextension during the swing phase of gait and eventual metatarsal plantarflexion and digital contracture.

The least encountered type of digital contracture is termed flexor substitution. This type of contracture is observed when the patient has a weakened gastrocnemius

or soleus muscle, which leads to a calcaneus style of gait. The flexor muscles of the deep posterior compartment of the leg substitute for the weakened gastrocnemius and soleus muscles. The decreased plantarflexory force of the ankle is achieved with the flexor digitorum longus muscle, allowing it to achieve a mechanical advantage over the interossei muscles leading to a sagittal plane contracture of all the digits.

The development of hammertoes is known to be progressive with stages of treatment corresponding to the severity and reducibility of the contracture. Many hammertoes begin as flexible or reducible interphalangeal joint contractures and over time progress to more rigid, non-reducible deformities. While conservative treatment options are available, surgical intervention has proven to provide the best long-term outcome (6).

## DISCUSSION

The traditional surgical approach for hammertoe correction is to utilize a longitudinally oriented dorsal incision, allowing access to the underlying soft tissue and osseous components necessary to complete the interphalangeal joint release. Due to the transverse orientation of this type of incision to the underlying relaxed skin tension lines, scar contracture is not uncommon. Additionally, the large dorsal incisions are easily visible and not aesthetically pleasing to the patient postoperatively (7). Modifications to this procedure have since been made and more recently, laterally located incisions have been gaining popularity (8). While this approach minimizes the visibility of the incision site, it does so at the cost of increasing possible complications, namely digital ischemia, avascular necrosis, and digital nerve trauma (9,10). It is for these reasons that this region of the digit has historically been avoided when considering surgical portals (11,12). It is the viewpoint of the authors that the plantar aspect of the digit may be the key to providing a safe and effective portal for the surgical correction of hammertoes that also satisfies the patient's aesthetic concerns.

As previously noted, the sensitive neurovascular structures located medially and laterally along the digits have deterred access in those regions, however the anatomic makeup on the plantar aspect of the digit is free

of concerning structures. Interestingly, the plantar level of the proximal interphalangeal joint (PIPJ) mirrors the dorsal aspect, minimizing any learning curve to those familiar with the traditional dorsal approach.

Traditionally, longitudinal incisions on the plantar aspect of the digits are avoided, due to the possibility of a painful scar on the weight-bearing surface of the foot. Incision sites on weight-bearing surfaces have been shown to lead to increased fibrosis and the possibility of a secondary contracture (13). It must be noted however that fat pad allocation at the metatarsophalangeal joint and unique curvature of the lesser digits significantly minimize contact forces experienced on the plantar PIPJ cleft of the digits during gait, rather than allocating ambulatory pressures to the distal tuft, which are further increased in hammertoe deformities (14). Furthermore, successful use of a plantar longitudinal incision for the tendon release in the treatment of claw toes has been previously outlined (15,16). While a plantar longitudinal incision has shown to be a viable option for accessing the lesser digits, a smaller, less invasive transverse incision provides sufficient space for dissection while further minimizing complications.

### TECHNIQUE

The following is a detailed description of our proposed plantar incisional approach for PIPJ arthroplasty. The patient is prepped and the extremity draped in a sterile fashion. A typical V block of local anesthetic is administered with 3-5 ccs of 0.5% bupivacaine to the affected digit. A #15 blade is used to make a 1-cm transverse incision just proximal to the PIPJ using the proximal crease line as the parallel guide (Figure 1). Blunt dissection then follows to

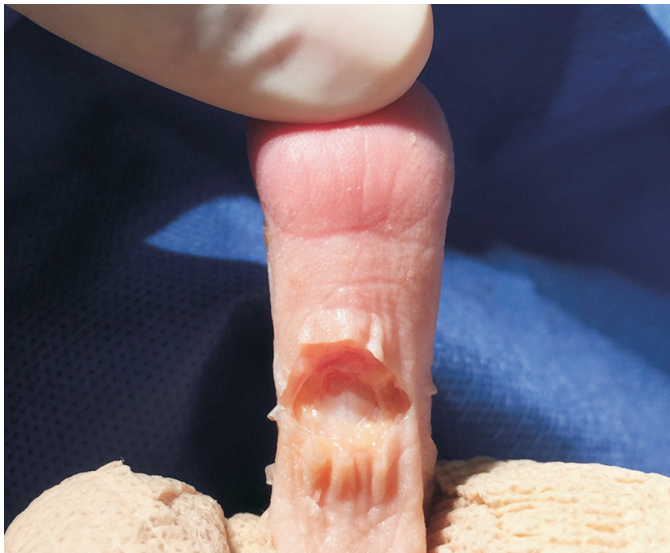

Figure 1. Transverse incision on the plantar aspect of the second proximal interphalangeal joint, followed by blunt dissection to the flexor tendon sheath.

the flexor tendon sheath (Figure 2). The flexor tendons are then split transversely as far distally as possible allowing for the possibility of a flexor tendon transfer if required. Plantar PIPJ joint capsulotomy is performed, and the medial and lateral collateral ligaments are then released (Figure 3). The blade is then passed between the extensor tendon and the proximal phalanx releasing the extensor hood. The head of the proximal phalanx is now free and delivered into the field through the elliptical portal. A bone saw or double action bone cutter is used to transect the proximal phalanx at the neck or at whatever level the surgeon deems as necessary (Figure 4).

It should be noted that cartilaginous resection at apposing joint surfaces could also be performed if joint fusion is necessary. The free bone is removed and any rough edges are smoothed with a rasp. If a flexor tendon transfer is to be performed, the remaining flexor tendon is split longitudinally and inserted on the dorsal aspect of the proximal phalanx. If necessary a Kirschner wire (K-wire) is then inserted into the base of the middle phalanx and advanced, exiting the distal aspect of the digit. Joint contracture is reduced and the K-wire is then retrograded proximally into the proximal phalanx base (Figure 5). The surgical site is then irrigated with normal saline, the flexor tendon re-approximated with 4-0 vicryl, and primary closure of incision is performed (Figures 6, 7). Suture strips are placed over the incision and a loose splint with Betadine bandage and gauze is placed over the toe (Figure 8). The patient is instructed to ambulate with a surgical shoe, and sutures are removed in 2 weeks.

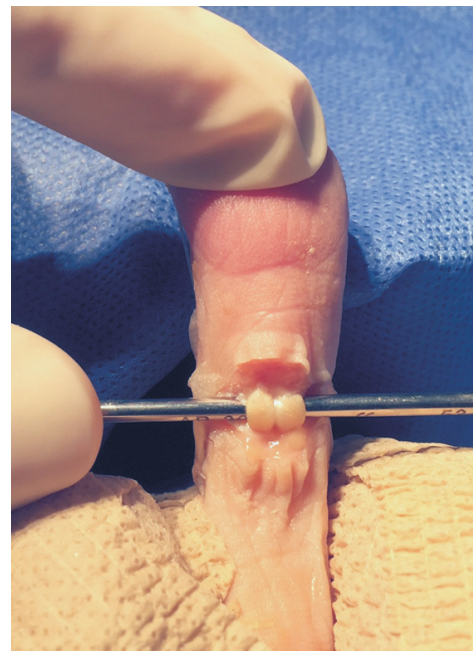


Figure 2. Flexor tendon is isolated, then transected to expose the proximal interphalangeal joint and joint capsule.

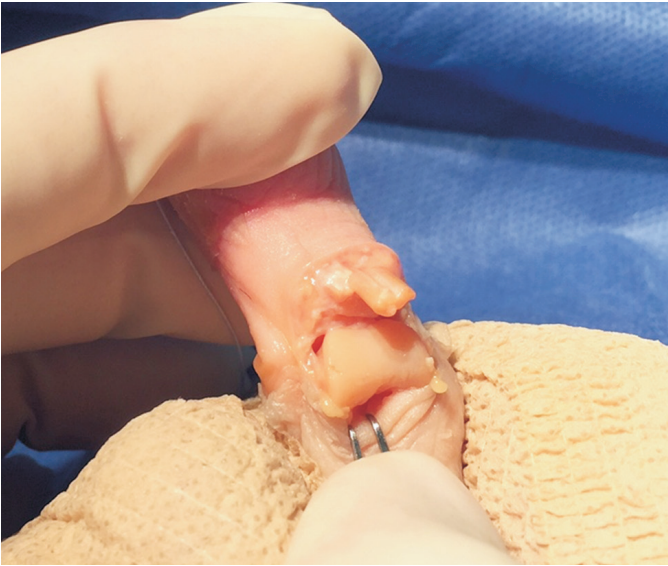

Figure 3. Transected flexor digitorum longus and flexor digitorum brevis tendons are visible. The joint capsule is entered with a transverse incision. The medial and lateral collateral ligaments are then cut, freeing the proximal phalanx and allowing it to be exposed plantarly through the incision site. At this point the EDL tendon is also visible dorsally and can be accessed if required.

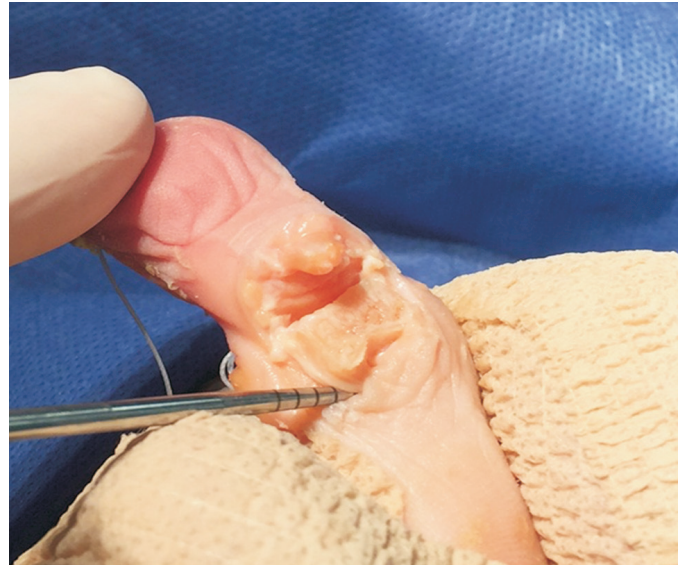

Figure 4. With the proximal phalanx exposed plantarly through the incision site the arthroplasty of the proximal phalanx head is performed.

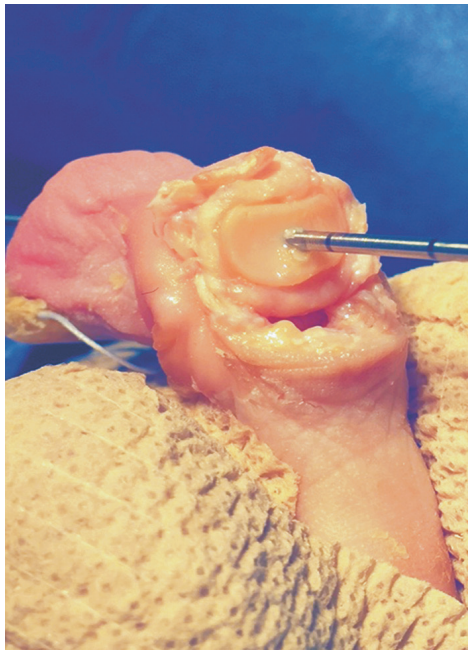


Figure 5. Kirschner wire is advanced distally into the base of the middle phalanx then proximally into the proximal phalanx when the digit is in the corrected position.

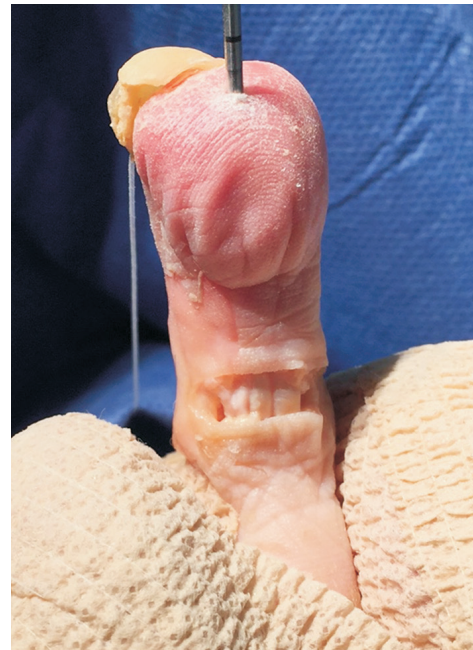

Figure 6. Once the phalanges are in an acceptable position, the flexor tendons are reapproximated with 4-0 Vicryl absorbable sutures.

## SUMMARY

Considerations for a new surgical technique should be made in instances where sufficient correction can be obtained through a superior approach, which provides for a more favorable outcome. When considering various surgical options, specifically in the instance of cosmetically-oriented procedures, one must consider the prospective

outcomes as well as the possible complications. This plantar incisional approach to reducible hammertoe repair is clearly less invasive than the traditional dorsal longitudinal incision; providing for equally sufficient access to the joint and surrounding structures and yielding an exponentially favorable aesthetic outcome. While some choose to avoid plantar incisions believing the pressure will increase fibrous and adhesions, the short transverse incision described, due

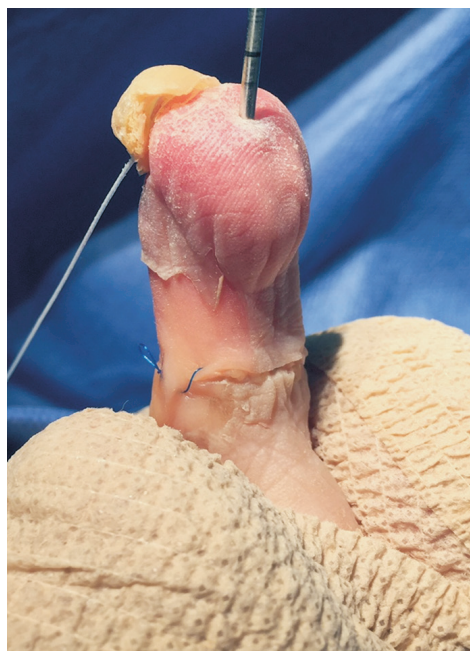

Figure 7. Running subcutaneous technique with 4-0 prolene is used to further minimize post operative scarring.

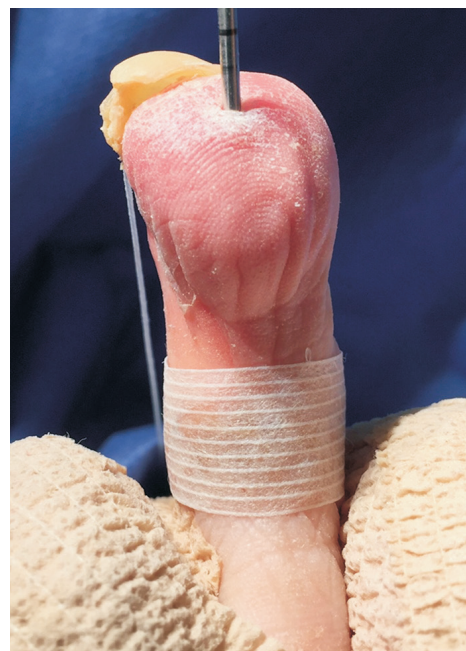

Figure 8. Incision site and suture is then covered with steri-strips for additional reinforcement and protection. Post-operative dressing and orders remain the same as traditional digit arthroplasty.

to its unique placement located in the nonweight-bearing portion of the PIPJ fold, as well as its orientation to the relaxed skin tension lines, the authors feel the risks are minimal. The transverse plantar approach also avoids the susceptible neurovascular bundles located on the lateral and medial aspects of the digit, therefore avoiding the complications of devascularization and necrosis.

The transverse plantar approach delivers the expected correction common with the traditional approach, with however absolutely no scar visible on the patients standing foot, and an incision hidden in the plantar PIPJ fold. We believe this is an excellent alternative to the traditional procedure for patients seeking optimal correction with a cosmetically-appealing outcome, and we feel further research is warranted to assess its applicability in surgical practice.

## REFERENCES

- Mordicai A, Dodd L, Foote J, Palmer S. Prospective review of medium term outcomes following interpositional arthroplasty for hammer toe deformity correction. *Foot Ankle Surg* 2011;17: 256-8.
- Kwon JY, DeAsla RJ. The use of flexor to extensor transfers for the correction of the flexible hammer toe deformity. *Foot Ankle Clin* 2011;16: 573-82.
- Roukis TS, Schade VL. Minimum incision metatarsal osteotomies. *Clin Podiatry Med Surg* 2008;25:587-607.
- Bade H, Tsikaras P, Koebke J. Pathomorphology of the hammer toe. *Foot Ankle Surg* 1998;43:139-43.
- Schubert JM. Hammer toe syndrome. *J Foot Ankle Surg* 1999;38:166-78.
- Good J, Fiala K. Digital surgery: current trends and techniques. *Clin Podiatr Med Surg* 2010;27:583-99.
- Van Enoo RE, Cane EM. Minimal incision surgery: a plastic technique or a cover-up? *Clin Podiatr Med Surg* 1986;2:321-55.
- DeBello J, DeCoteau K, Beatty E. Taking a novel approach to hammertoe surgery. *Podiatry Today* 2006;19.
- Scheck M. Degenerative changes in the metatarsophalangeal joints after surgical correction of severe hammer-toe deformities: a complication associated with avascular necrosis in three cases. *J Bone Joint Surg Am* 1968;50:727-37.
- Scheck M. Etiology of acquired hammer toe deformity. *Clin Orthop* 1997;123:63-9.
- Dhukaram V, Prasthofer CA, Upadhyay PK. Minimally invasive forefoot surgery: a cadaveric study. *Foot Ankle Int* 2012;33:1139-44.
- Gilheany M, Baarini O, Samaras D. Minimally invasive surgery for pedal digital deformity: an audit of complications using national benchmark indicators. *J Foot Ankle Res* 2015;8:17.
- Maffulli N, Easley ME. *Minimally Invasive Surgery of the Foot and Ankle*. London: Springer Verlag; 2011.
- Maffulli N, Easley ME. *Minimally Invasive Surgery of the Foot and Ankle*. London: Springer Verlag; 2011.
- Bouche RT, Heit EJ. Combined plantar plate and hammertoe repair with flexor digitorum longus tendon transfer for chronic, severe, sagittal plane instability of the lesser metatarsophalangeal joints: preliminary observations. *J Foot Ankle Surg* 2008;47:125-37.
- Kernbach KJ. Hammertoe surgery: arthroplasty, arthrodesis, or plantar plate repair. *Clin Podiatr Med Surg* 2012;35:5-6.