

Combined Reconstruction of the Deltoid and Spring Ligament Complex in an Acute Ligamentous Injury

Samuel Hammer-Nahman, DPM

Philip Wroslavsky, DPM

INTRODUCTION

The deltoid ligament complex and the spring ligament complex have been shown to be significant structural stabilizers for proper foot function. These ligaments can be considered one larger complex anatomically and functionally (1-3). Controversy exists in determining which ligaments play the greatest part in preventing valgus ankle tilt and rotational stability of the ankle (4-8). Injury of these ligaments can cause catastrophic deformity, dysfunction, and pain. Rupture of the deltoid ligament and spring ligaments are often associated with concomitant fracture, chronic flatfoot deformity, and poor results of total ankle arthroplasty or triple arthrodesis (3,9-13). The authors propose a case of combined reconstruction of both deltoid and spring ligaments that may be advantageous for use in numerous clinical situations because of its anatomic and biomechanic considerations.

ANATOMY AND BIOMECHANICS

The anatomy of the deltoid ligament has varied greatly in the literature, but the literature agrees on some more consistent ligamentous bands. The number of ligaments ranges from 4 to 8 ligaments (14-18). There is a general agreement that the deltoid ligament complex is comprised of a superficial and deep layer. The superficial layer of the deltoid ligament consists of a tibionavicular ligament, tibiospring ligament,

and tibiocalcaneal ligament in many reports. The deep deltoid ligaments consist of the deep posterior tibiotalar ligament, superficial posterior tibiotalar ligament, and the anterior tibiotalar (11). In Milner et al's cadaveric study, they found the tibionavicular ligament, tibiospring ligament, and the deep posterior tibiotalar ligament to be constant throughout all of the 40 specimens dissected (17).

The term spring ligament is a misnomer and should be considered an articular sling. There are, in fact, no "spring" properties of this ligament histologically nor biomechanically (1,19). It is also a misnomer because it is not only 1 ligament. It has been described as being up to 3 ligaments, although it is most recognized as a 2-ligament complex consisting of the superomedial calcaneonavicular ligament and inferior calcaneonavicular ligament (20). The superomedial calcaneonavicular ligament is broader and contains an avascular articular facet for articulation with the talus. Davis et al studied 38 cadaver specimens and found the spring ligament to have histologic components of significant load-bearing without any elastin or special elastic properties. In their biomechanic testing of the spring ligament, they found that the spring ligament had strength similar to ankle ligaments (1,19) (Figures 1, 2).

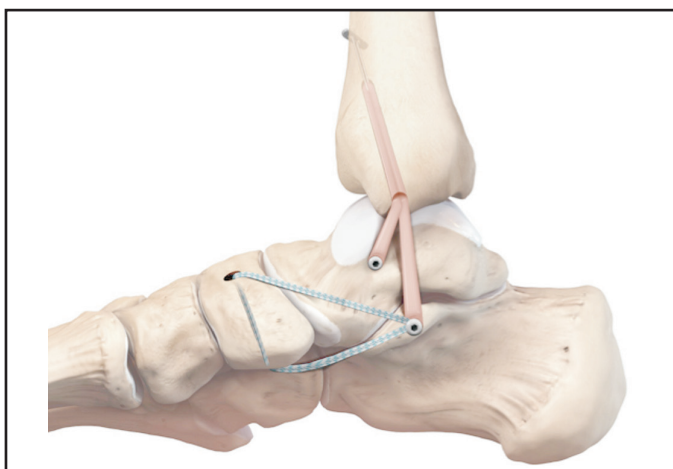


Figure 1. Combined deltoid ligament (beige allograft tendon) with spring ligament (blue suture tape) reconstruction.

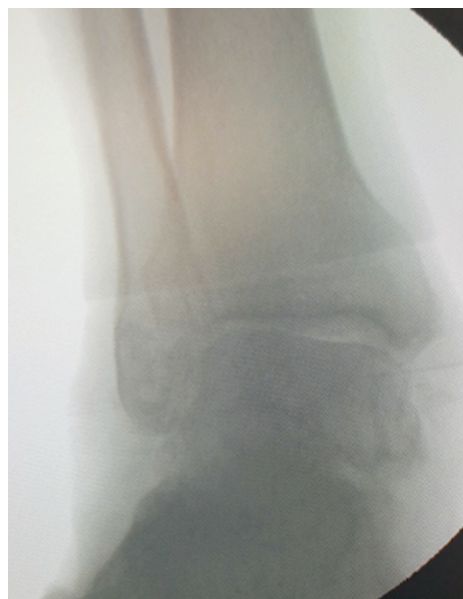

Figure 2. Stress eversion radiograph demonstrated 23 degrees of eversion of the tibio-talar joint.

The anatomy and biomechanics of the spring and deltoid ligaments are integral and this can be reflected in surgical reconstruction. Davis et al proposed a relationship between the spring and deltoid ligament and suggested its connection to pes planus. It has been suggested that these 2 ligaments should be considered part of 1 ligamentous complex because of the broad insertion of the superficial deltoid on the spring ligament and due to their complex interaction to stabilize the talus functionally (1-3).

SURGICAL TECHNIQUE

A 50-year-old man presented to our outpatient office reporting continued ankle pain and difficulty walking after sustaining an injury while playing recreational football 2 months prior. Severe eversion of greater than 45 degrees with mild crepitus of the ankle joint was seen on examination. There was a positive anterior drawer sign. Upon heel strike during gait examination, there was visible subluxation of the ankle into an everted position. Stress eversion radiographs demonstrated 23 degrees of eversion of the tibio-talar joint (Figure 2). Magnetic resonance imaging (MRI) was positive for deltoid, spring, and anterior-talofibular ligament ruptures.

The patient was brought to the operating room lying in the supine position and was prepped and draped in the usual fashion. A thigh tourniquet was inflated to 300 mm Hg. Upon fluoroscopic examination, there was widening of the medial clear space. A 9-cm curvilinear incision over the medial malleolus was made, curving down to the medial cuneiform. Blunt dissection was performed to expose the posterior tibial tendon and the flexor hallucis longus tendon. The sustentaculum tali, the talar body, and medial malleolus were identified. The posterior tibial tendon was then further dissected down to the navicular. Upon inspection of the superficial and deep deltoid ligaments and spring ligament, there were no visible remnants appreciated. Next a guide wire was passed up through the medial malleolus going posterior to anterior exiting the anterior tibia (Figure 3A).

A small incision was made to the anterior tibia to allow the wire to be passed through. A 4.0 drill was then used to drill over the wire. The hole was then over drilled with a 5.0 drill to a depth of 30 mm to allow for the semi-tendinosus allograft to pass part way through the tibia. Next, a semi-tendinosus allograft that was presutured was then passed from the medial malleolus up in through the tibia with the suture button passing out of the anterior tibia (Figure 3B). The tibial suture button was then placed down on the tibia and the graft was anchored into the tibia. A 3.0 drill was used in the medial aspect of the talar body. The shorter limb of

the graft was placed into the talar body and a bio-tenodesis screw was then placed to anchor the deep deltoid limb of the reconstruction. A 4.0 drill was used to drill through the sustentaculum tali. The longer limb of the semitendinosus allograft was then passed deep to the posterior tibial tendon into the drill hole in the sustentaculum tali. Along with the graft, 2 arms of the internal brace were also anchored into the drill hole using 1 bio-tenodesis screw (Figures 3C, 3D).

Next, the ankle was placed at 90 degrees and the subtalar joint was placed in a neutral position. While in this position, the suture button was fully tensioned at the tibial end, thus pulling the graft up the canal and tightening the newly reconstructed deltoid ligaments. This completed the superficial and deep deltoid reconstruction, and fluoroscopy was employed to confirm that the ankle joint had symmetric gutters and was stable under eversion stress (Figure 4A).

A drill hole was made through the navicular from dorsal to plantar. The 2 arms of the internal brace that were previously anchored into the sustentaculum tali were then passed through the hole, 1 dorsal-to-plantar and the other plantar-to-dorsal forming a hammock like effect. The internal brace reconstruction was then tensioned and bio-tenodesed with a 3.5 bio-tenodesis screw from dorsal-to-plantar (Figures 4B-D). There was adequate exposure for this entire procedure without resection of the posterior tibial tendon. The spring ligament reconstruction was noted to be adequate. PRP was then injected over the graft and incision sites. Amniotic graft was then placed over the tendon to prevent adhesions.

Next the ankle was put through an anterior drawer test and there was noted to be over 20-mm of anterior translation. There was a preoperative diagnosis of anterior talofibular ligament tear seen on MRI and at this point the decision was made to repair the lateral ankle ligaments. A 3-cm incision was made at the distal aspect of the fibula. Blunt dissection was made down to the fibula and the anterior talofibular ligament was noted to be completely torn. The body of the talus was then predrilled and the suture tape was biotenodesed into the nonarticulating surface of the talar body. The fibula was predrilled and the 2 arms of the suture tape were then biotenodesed into the fibula. At that point, the reconstruction was stressed with an anterior drawer test resulting in approximately 5-mm of motion. Amniotic graft was placed into the lateral incision as well.

Subcutaneous tissue was closed with 2-0 and 3-0 vicryl and the skin was closed with staples. A wound vac over the medial and lateral incisions was used due to the amount of swelling expected to be created from these procedures. The patient was placed in a posterior splint and made nonweight-bearing for 6 weeks (Figure 5).

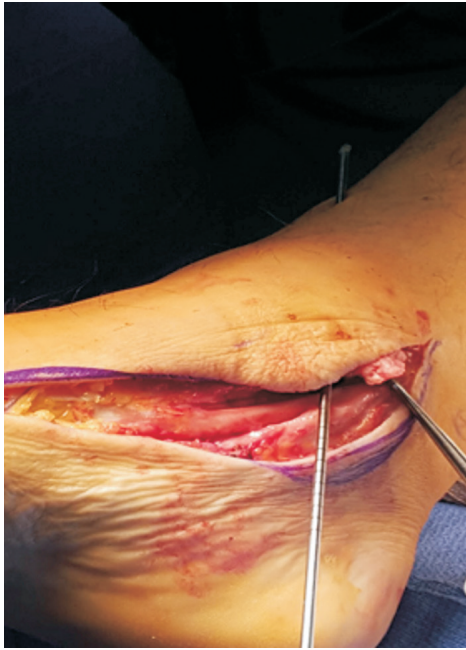

Figure 3A. Deltoid reconstruction begins with a guide wire that was passed up through the medial malleolus going posterior to anterior exiting the anterior tibia. A small incision was made to the anterior tibia to allow the wire to be passed through.

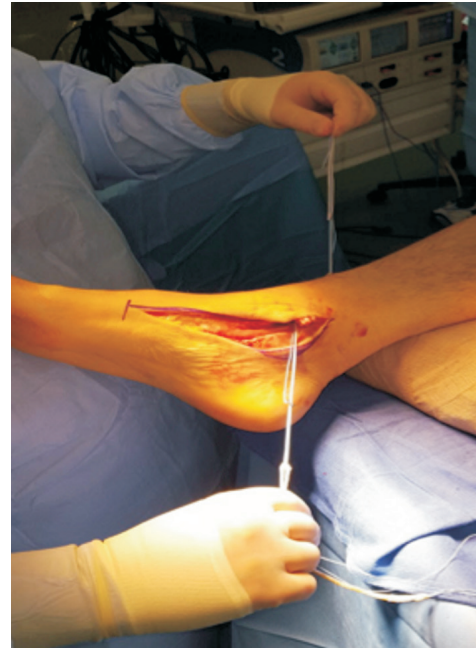

Figure 3B. The allograft tendon passed from the medial malleolus up through the tibia with the suture button passing out of the anterior tibia.

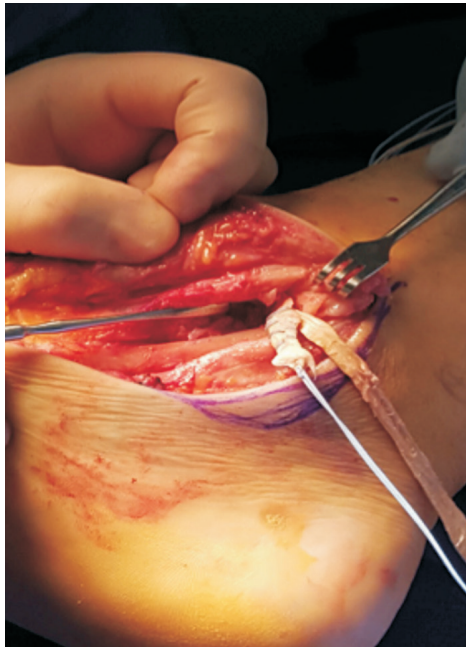


Figure 3C. A Freer pointing towards where the short arm of the tendon allograft will be inserted into the talar body.

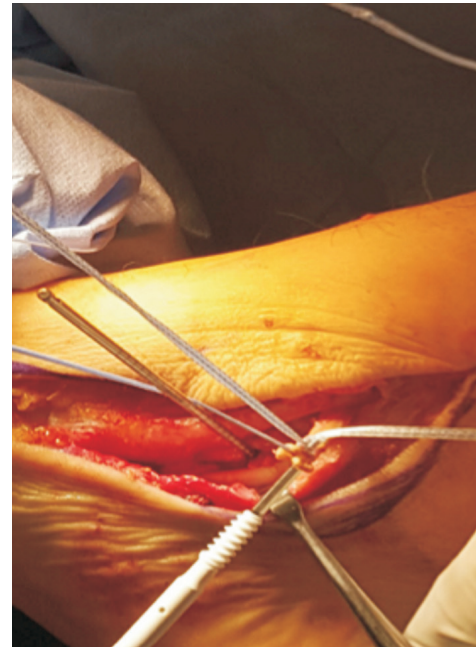


Figure 3D. The longer limb of the allograft tendon was then passed deep to the posterior tibial tendon. A guide wire was placed just inferior to the sustentaculum tali for cannulated drilling. The allograft tendon was anchored into the drill hole just beneath the sustentaculum tali. Along with the graft, 2 arms of suture tape were also anchored into the drill hole using 1 bio-tenodesis screw.

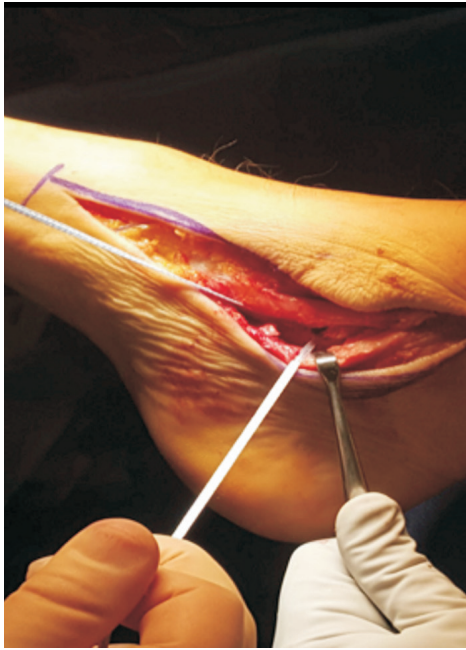

Figure 4A. Spring ligament reconstruction begins with the 2 arms of suture tape that have been anchored just inferior to the sustentaculum tali.

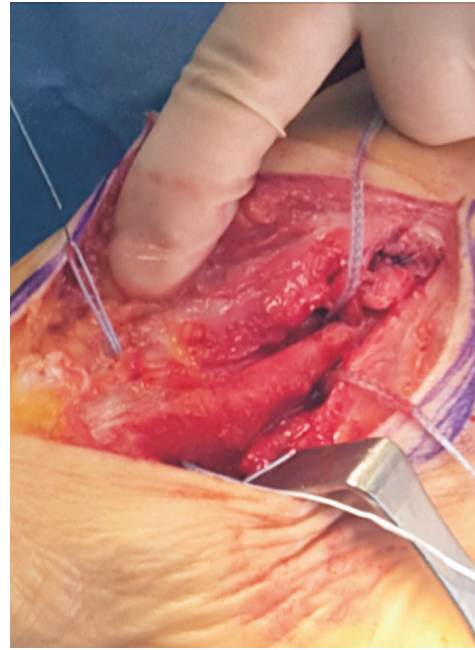


Figure 4B. A drill hole was made through the navicular from dorsal to plantar. The 2 arms of the suture tape that were anchored into the sustentaculum tali were then passed through the hole, one dorsal-to-plantar and the other plantar-to-dorsal (pictured) forming a hammock like effect.

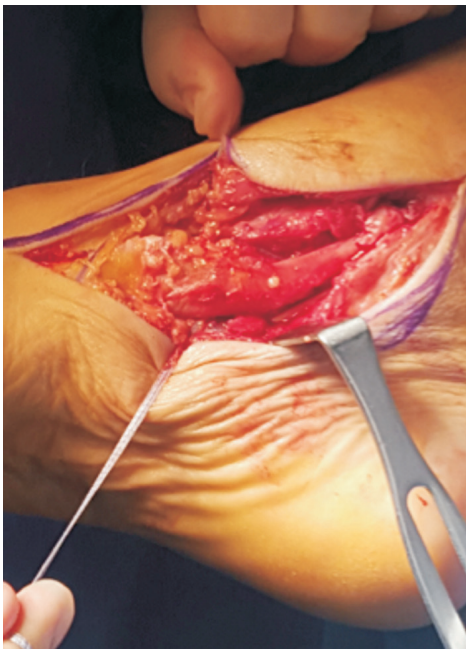


Figure 4C. The internal brace reconstruction of the spring ligament was then tensioned.

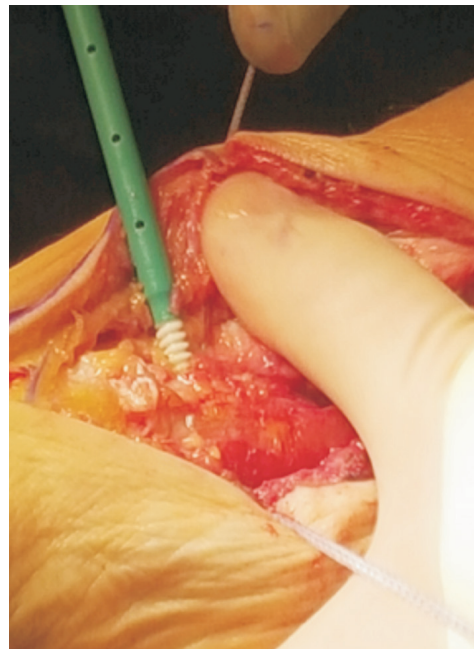


Figure 4D. The internal brace was anchored with a 3.5 bio-tenodesis screw from dorsal-to-plantar.

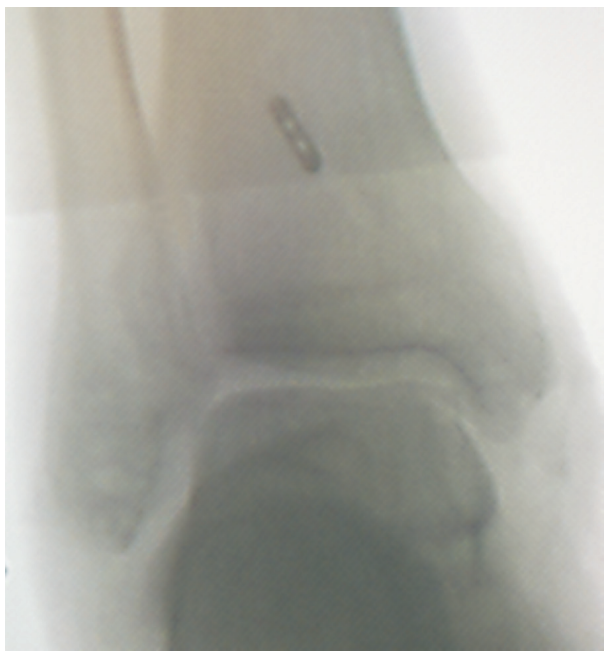


Figure 5. Intra-operative fluoroscopy demonstrating an even mortise medially and laterally.

DISCUSSION

The literature describes numerous techniques for reconstruction or repair of either the deltoid ligament or the spring ligament as separate procedures; however, there have been very few examples of repairing both together. The combined technique that the authors present was highly effective in this limited case study and has the added benefits of taking into account the anatomy and biomechanics of these ligaments.

The deltoid ligament is often compromised in bimalleolar equivalent ankle fractures, but controversy exists over whether or not to repair the ligament or fix it indirectly with syndesmotic fixation. Historically, the literature has discouraged many from repairing the deltoid ligament in bimalleolar equivalent ankle fractures (11). However, as Luckino et al pointed out, the majority of the limited research available on necessity for deltoid repair in ankle fractures was level IV evidence with less than satisfactory results (21). Other critics, point to the fact that these studies did not assess medial instability during stress examinations or direct visualization. Hsu and Anderson et al, in their study measuring outcomes of 14 NFL players with ankle fracture and subsequent repair with deltoid ligament repair had favorable results, including an 86% return to sport. Hsu and Anderson state that they now routinely repair the deltoid in these injuries based on their findings of complete avulsion of the superficial deltoid with infolding that can prevent adequate reduction and cause persistent pain and instability (12).

Contrastingly, Yu et al's multicenter retrospective review of ankle fractures found 131 patients with deltoid ruptures that were repaired when medial clear space was persistently >5 mm after fibular fracture fixation. Their study demonstrated no significant difference in outcomes, but there was no standardization of treatment or patients without increased medial clear space after fibular fixation that had deltoid repair (22). Jones and Nunley actually compared 27 patients sustaining bimalleolar equivalent ankle fractures that were split into 2 groups: 15 patients were treated with lateral malleolus open reduction with internal fixation (ORIF) with trans-syndesmotic fixation, whereas 12 were treated with lateral malleolus ORIF with deep deltoid ligament repair with suture anchor. They found no statistical difference in outcomes (9).

Adult acquired flatfoot deformity routinely progresses to medial column collapse and or a valgus ankle that requires spring and or deltoid ligament reconstruction, respectively. Numerous reconstruction techniques have been proposed for the attenuation of the deltoid ligament and spring ligaments in the adult acquired flatfoot deformity. The literature favors reconstruction rather than reefing up and repair of native tissue due to reports of native tissue repairs and reefing up failing over time due to poor quality of the tissues. Some deltoid reconstruction techniques have been criticized for only repairing the deep portion of the deltoid ligament (6,23,24). Other techniques only repair the superficial portion. Close et al biomechanic testing of the ankle ligaments found that with all of the lateral structures removed, the intact deltoid ligament allows only 2 mm of separation between the talus and medial malleolus. When the deep deltoid ligament is released, the talus can be separated from the medial malleolus by 3.7 mm (25). The authors as well as many others proposed techniques for deltoid reconstruction using autograft or allograft tissue to reconstruct both the superficial and deep deltoid ligaments (26,27).

Haddad et al proposed a deltoid reconstruction technique using anterior tibial tendon allograft attached to sutures and suture buttons that are passed through drill holes in the tibia, talus, and calcaneus. In their cadaver study, they were able to restore eversion and external rotation stability to the talus during biomechanic testing (24). The authors' proposed technique involves a deltoid ligament reconstruction component that is similar to Haddad's previous studies. The spring ligament reconstruction presented was performed using Arthrex InternalBrace. This procedure has the potential to be augmented with flexor digitorum longus transfer for added support and dynamic stabilization. Anatomically, the origin of the superomedial calcaneonavicular ligament was shared with the insertion point of the tibio-calcaneal fibers of the superficial deltoid

ligament (1). The procedure described in this case study uses this common ligamentous attachment site to more accurately reconstruct both ligaments anatomically.

In conclusion, combined deltoid and spring ligamentous injuries may necessitate surgical treatment if pain, deformity, and mechanical instability persist. The authors have demonstrated an effective technique for a combined repair of both the spring ligament and the deltoid ligament. This technique is relatively easily done and may be used in numerous clinical situations including acute ligamentous injuries, stage IV flatfoot, or TAR with valgus ankles and AAFD.

Acknowledgements

Special thanks to Arthrex for providing us with images and to James Danenberg for assistance with the literature search.

REFERENCES

- Davis WH, Sobel M, DiCarlo EF, et al. Gross, histological, microvascular anatomy and biomechanical testing of the spring ligament complex. *Foot Ankle Int* 1996;7:95-102.
- Siegler S, Block J, Schneck CD. The mechanical characteristics of the collateral ligaments of the human ankle joint. *Foot Ankle* 1988;8:234-42.
- Hintermann B, Knupp M, Pagenstert G. Deltoid ligament injuries: diagnosis and management. *Foot Ankle Clin* 2006;11:625-37.
- Giza E, Wuellner J. Acute deltoid rupture: history, diagnosis, and a repair technique. *Tech Foot Ankle Surgery* 2014;13:73-80.
- Foetisch CA, Ferkel RD. Deltoid ligament injuries: anatomy, diagnosis, and treatment. *Sports Med Arthrosc* 2000;8:326-35.
- Smith J, Bluman E. Update on stage IV acquired adult flatfoot disorder: when the deltoid ligament becomes dysfunctional. *Foot Ankle Clin* 2012;17:351-60.
- Jung MG, Park JT, Eom JS, Jung MG, Lee DO. Reconstruction of superficial deltoid ligaments with allograft tendons in medial ankle instability: a technical report. *Injury* 2016;47:780-3.
- Wenny R, Duscher D, Meytap E, Weningr P, Hirtler L. Dimensions and attachments of the ankle ligaments: evaluation for ligament reconstruction. *Anat Sci Int* 2015;90:161-71.
- Jones C, Nunley J. Deltoid ligament repair versus syndesmotic fixation in bimalleolar equivalent ankle fractures. *J Orthop Trauma* 2015;29:245-9.
- Bluman E. Deltoid ligament injuries in ankle fractures: should I leave it or fix it? *Foot Ankle Int* 2012;33:236-8.
- Sjoerd A, Stufkens S, Van Den Bekerom M, Knupp M, Hintermann B, Niek Van Dijk C. The diagnosis and treatment of deltoid ligament lesions in supination external rotation ankle fractures: a review. *Strat Traum Limb Recon* 2012;7:73-85.
- Hsu A, Lareau C, Anderson R. Repair of acute superficial deltoid complex avulsion during ankle fracture fixation in national football league players. *Foot Ankle Int* 2015;36:1272-8.
- Roukis T, Prissel M. Reverse Evans peroneus brevis medial ankle stabilization for balancing valgus ankle contracture during total ankle replacement. *J Foot Ankle Surg* 2014;53:497-502.
- Panchani P, Moore G, Tubbs R, Loukas M, Khan K, D'Antoni A, et al. Anatomic study of the deltoid ligament of the ankle. *F Ankle Int* 2014;35:916-21.
- Campbell K, Michalski M, Wilson K, Goldsmith M, Wijidicks C, LaPrade R, et al. The ligament anatomy of the deltoid complex of the ankle: a qualitative and quantitative. *J Bone Joint Surg Am* 2014;96:e62.
- Boss AP, Hintermann B. Anatomical study of the medial ankle ligament complex purpose. *Foot Ankle Int* 2012;23:547-53.
- Milner CE, Soames RW. The medial collateral ligaments of the human ankle joint: anatomical variations. *Foot Ankle Int* 1998;19:289-92.
- Milner CE, Soames RW. Anatomy of the collateral ligaments of the human ankle joint. *Foot Ankle Int* 1998;19:757-60.
- Hardy RH. Observations on the structure and properties of the plantar calcaneonavicular ligament in man. *J Anat* 1951;85:135-9.
- Taniguchi, A, Tanaka Y, Takakura Y, et al. Anatomy of the Spring Ligament. *J Bone Joint Surg Am* 2003;85 : 2174 -8.
- Luckino F, Hardy M. Use of flexible implant and bioabsorbable anchor for deltoid rupture repair in bimalleolar equivalent. *Weber B Ankle Fractures. J Foot Ankle Surg* 2015;54:513-6.
- Yu G, Tang X, Li B, et al. Repair of the acute deltoid ligament complex rupture associated with ankle fractures: a multicenter clinical study. *J Foot Ankle Surg* 2015;54:198-202.
- Peterson K, Hyer C. Dysfunctional surgical decision making for stage IV adult acquired flatfoot disorder. *Clin Podiatry Med Surg* 2014;31:445-54.
- Haddad SL, Dedhia S, Ren Y, et al. Deltoid ligament reconstruction: a novel technique with biomechanical analysis. *Foot Ankle Int* 2010;31:639-51.
- Close JR. Some applications of the functional anatomy of the ankle joint. *J Bone Joint Surg Am* 1956;38:761-81.
- Lui TH. Technical tips: reconstruction of deep and superficial deltoid ligaments by peroneus longus tendon in stage 4 posterior tibial tendon dysfunction. *Foot Ankle Surg* 2014;20:295-7.
- Bluman EM, Myerson MS. Stage IV posterior tibial tendon rupture. *Foot Ankle Clin* 2007;12:341-62.