

Local Infiltration Analgesia Techniques for Closed Reduction of Ankle Fractures

Kevin Y. Lu, DPM

INTRODUCTION

In the interest of time and cost-efficiency, the skilled practitioner should be able to obtain adequate analgesia with a local block for the majority of ankle fractures. Without adequate analgesia, the difficulty of reduction increases given that pain results in patients' voluntary muscle contraction and involuntary spasm. Some institutions elect to only give some form of intravenous conscious sedation for closed reductions, but the patient will still feel pain, and therefore, can still subconsciously respond to pain with muscle contraction. Although the patient may not remember it, this makes for a much more difficult closed reduction. Others will augment a local block with conscious sedation, but still relying heavily on the intravenous sedation for adequate relaxation to perform the reduction. Again, if the block is effective, conscious sedation is extraneous, unless in the case of an extremely anxious patient.

Technique is paramount for effective local blocks and should not be overlooked. The following attempts to illustrate the technique used for consistently complete analgesia for ankle fracture closed reductions. Most commonly, an intra-articular hematoma block is used. This involves infiltration of the ankle joint, which is filled with blood from the existing injury. The local anesthetic diffuses from the ankle joint to the fractured area. Since this relies on physical proximity, it is not unreasonable to think this alone may not be as reliable in certain fractures compared to others. A low transverse medial malleolar fracture may be completely anesthetized, whereas a tall vertical shear fracture or long spiral fibular fracture may only be partially affected, given the larger distance the anesthetic must travel from the ankle joint.

Perhaps less commonly, due to being more technically difficult, a fracture hematoma block is utilized, or multiple fracture hematoma blocks, depending on what fracture configuration presents. This relies on the caregiver's ability to accurately translate the 2-dimensional radiographic image osseous pathology to the 3-dimensional parameters of the patient's ankle. The same concept as the intra-articular hematoma block is used with hematoma aspiration confirming the needle location within the fracture, and subsequent infiltration with local anesthetic.

TECHNIQUE

Achieving complete analgesia consistently with only local anesthetic is simple: each injured structure must be anesthetized. If one chooses to only infiltrate fracture hematoma, then it cannot be expected that the torn ankle capsule will be affected at all. The ankle capsule has nerve endings. And as mentioned before, relying solely on an intra-articular hematoma block will not affect higher fibular fractures as seen in PER injuries, among other fractures with a more distant relationship to the ankle joint.

The first, and sometimes the only thing most residents think of when dealing with ankle fractures is the obvious osseous pathology. In order to assess what other soft tissue structures are injured, one must have a strong grasp of the Lauge-Hansen classification. Lauge-Hansen's legitimacy and ability to predict certain soft tissue injuries has been called into question before. However, in 2015, Warner et al demonstrated that 94% of ankle fractures classified had magnetic resonance image (MRI) readings consistent with the Lauge-Hansen classification. Moreover, only 6% showed discrepancies between the MRI and intraoperative findings (1).

Therefore, the author will perform an intra-articular hematoma block as well as a fracture hematoma block for every fracture present, and will also infiltrate the soft tissue structures injured, as predicted by Lauge-Hansen. For example, for a very common SER4 with true trimalleolar injury, an intra-articular hematoma block and 3 fracture hematoma blocks would be performed. One could rely on diffusion from the ankle joint and hope that the anesthetic reaches the ruptured AITFL, but direct infiltration is quite easy. This ensures all structures are anesthetized.

If an SER4 presents with deltoid ligament and PITFL ligament rupture, then the same intra-articular hematoma block and fibular fracture hematoma block are performed, followed by direct infiltration of the PITFL, AITFL, and the deltoid ligament. In this instance, the intra-articular block may be adequate to have reached most of these structures given their proximity to the ankle capsule, but it is minimal effort to ensure they are affected by direct infiltration. It can be useful to know that when the PITFL is injured, the majority of the time it is delaminated from its insertion onto

the posterior malleolus. Rarely, it is an intra-substance rupture in the middle of the ligament (2). This would direct PITFL injury infiltration somewhat more medial. Sometimes the saphenous nerve can be directly infiltrated just proximal to the ankle region, given its demonstrated role in innervating the medial malleolus and the anterior ankle capsule (3), which is commonly violated in rotational injuries.

To be comfortable with anesthetizing these injuries completely, bone pain physiology should be appreciated. One should remember that bone itself is without nociceptive receptors. Periosteum, however, is replete with nerve endings, as demonstrated extensively by Sakada et al (4-9). Periosteal disruption of any kind manifests as pain. Thus, torn periosteum is painful. Intact periosteum that is manipulated with closed reduction may also be uncomfortable, given the stretch receptors present (10). Conceptually, one should aim to infiltrate around the more superficial periosteum involved with each fractured site of any one ankle fracture, thinking about where periosteum would be disturbed 3-dimensionally, focusing less on the entirety of the surface area between bone fracture interfaces.

Bone marrow pain receptors, less well studied than periosteum nerve endings, have been shown to be responsive to increased pressure (11,12) but it is unclear what role, if any, these nerves play in the acute fracture setting pain. It is possible the increased pressure from hematoma or deep swelling could lead to the dull, lower grade pain that lingers after a closed reduction. The efficacy of intra-articular hematoma blocks of ankle fracture-dislocations has been studied. White et al did not find statistically significant difference between local block and conscious sedation (13) as far as perceived pain. However, their published average pain score is 3.1 for local block groups after reduction. The author feels this can be improved to a number approaching zero with direct and deliberate infiltration of all violated structures. Prospective studies investigating this are still needed. The additional time needed to ensure all injured areas are anesthetized is minimal and the benefits profoundly outweigh any perceived drawbacks from this additional time spent infiltrating.

There is literature citing the use of 20 gauge and 22 gauge needles. We use a 25 gauge needle for both intra-articular and fracture hematoma blocks, as it is less painful for the patient, but still relatively easy to infiltrate with. We recommend against the use of anything smaller than a 25 gauge because it becomes difficult to infiltrate. A 25 gauge needle will still afford enough size that when hematoma is encountered, blood will enter the syringe without deliberate aspiration, conferring relative ease in performing this maneuver.

The author prefers marcaine over lidocaine. Marcaine time of onset is not significantly longer than lidocaine in

the setting of the emergency room where supplies must be gathered for cast or splint immobilization. Epinephrine confers the ability to use more marcaine per kilogram of body weight, can help with bleeding, and possibly prolongs marcaine's duration, although not as profoundly as it does with lidocaine. Additionally, marcaine itself has been shown to confer analgesia for some time after sensation actually returns (14). If the patient has several different areas requiring infiltration, then a more dilute 0.25% marcaine will be used, especially if the structures or fractures are more difficult to access. If accurate infiltration is not felt to be ensured, flooding an area with a more dilute solution in a windshield wiper fashion and the use of epinephrine can help the caregiver stay within the advised limits of marcaine per kilogram of body weight, while ensuring adequate analgesia. Of course, one must allow enough time for the local anesthetic to take effect. This time will vary depending on which anesthetic was chosen, and whether epinephrine was utilized. Epinephrine may delay the time of onset.

After a good local block, it is important to discuss with the patient what to expect. Because the patient will be without sedation, explaining that his or her cooperation is needed in the form of relaxing the injured extremity is very helpful. Patients can usually understand that their contraction of muscles will make it more difficult for practitioners to "pull the ankle back into place." Only in the instance of an extremely anxious patient should conscious sedation be considered. Unnecessary sedation increases hospital costs. Increased length of stay in the emergency room is not only by virtue of the sedation process itself, but also the required monitoring the patient needs after receiving sedatives.

DISCUSSION

Achieving a block for a painless reduction is a skill like any other, and can be improved with time, practice, and proper guidance. Far too often, residents are content with the misguided sentiment that conscious sedation is simply easier. Over 3 years, the author has gone from intra-articular hematoma block with conscious sedation, to intra-articular hematoma block with heavy narcotic administration with dilaudid or morphine, to light narcotic administration with a combination of intra-articular and fracture hematoma blocks, to only local infiltration with attention to soft tissue injury as well. With this, patients are completely comfortable. Because the patients are completely comfortable, the reduction can be performed calmly, without any rush, for an excellent reduction with no re-reduction needed. White et al published average times from consult to reduction and immobilization to be approximately 60 minutes for lidocaine intra-articular block compared to 80 minutes

for intravenous conscious sedation (13). In the author's experience, time to consult to reduction and immobilization is closer to 45 minutes.

Recently, the upper extremity orthopedic literature has investigated the use of periosteal blocks in distal radial and ulnar fracture closed reductions (15). The forearm distal radial and ulnar fractures do not involve the wrist joint. Local anesthetic was administered to the periosteum proximal to the fracture site before closed reduction. They reported painless experiences by 83% of the patients, but further analyses revealed that in the patients who were ages 12-16 years, 94% reported no pain, suggesting younger children may have reacted unreasonably to needle stick and biased the result of perceived negative experience.

This could be applied in ankle fracture closed reduction settings to augment a fracture hematoma block, or if difficulty was encountered in identifying the fracture hematoma. It is unclear if this technique would be more effective if the periosteal block were to be performed both proximal and distal to the fracture sites. This also can be useful for comminuted pilon fractures that need to be reduced out to length before immobilized since it is impractical to go after each individual fracture that communicates with one another. Again, this is supported by the physiology of bone pain and the significant role of periosteum in conferring bone pain over deep bone tissue actually fragmented, which is not easily accessible by local block but does not actually appear to be essential for good local block pain control.

Additionally, the arthroscopic and knee and upper extremity orthopedic literature is replete with studies looking at irrigating joints and performing peripheral nerve blocks with a number of local anesthetic adjuvants to improve pain control. It has been suggested that osseous tissues have opioid receptors and that direct exposure to involved tissues to a number of different opioids has been studied. Others, such as toradol, magnesium, and even simply using cold local anesthetic over room temperature can enhance overall pain control and its duration, and eliminate side effects associated with systemic intravenous administration. These are all concepts that could translate to ankle fracture closed reduction local analgesia options for short-term and long-term pain control but are not in the scope of this article.

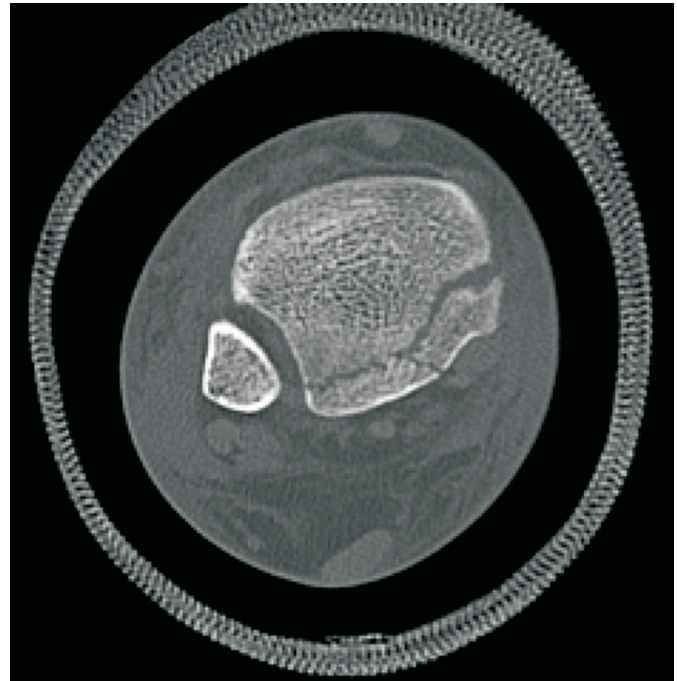


Figure 1A. Posterior malleolar fracture communicating with the medial malleolus demonstrating an instance when a proximal periosteal block may be useful before attempting closed reduction. Fracture location and morphology make this difficult to approach with fracture hematoma block only.

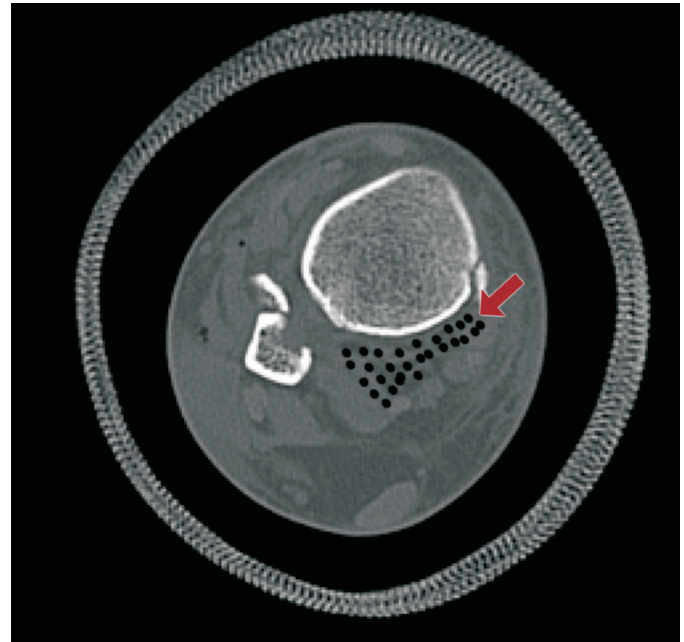


Figure 1B. Infiltration approach for proximal periosteal block for the fracture shown in Figure 1A.

REFERENCES

1. Warner SJ, Garner MR, Hinds RM, Helfet DL, Lorich DG. Correlation between the Lauge-Hansen classification and ligament injuries in ankle fractures. *J Orthop Trauma* 2015;29:574-8.
2. Warner SJ, Garner MR, Schottel PC, Hinds RM, Loftus ML, Lorich DG. Analysis of PITFL injuries in rotationally unstable ankle fractures. *Foot Ankle Int* 2015;36:377-82.
3. Clendenen S, Whalen JL. Saphenous nerve innervation of the medial ankle. *Local Reg Anesth* 2013;6:13-6.
4. Sakada S. Mechanoreceptors in fascia, periosteum and periodontal ligament. *Bull Tokyo Med Dent Univ* 1974;21(Suppl):11-3.
5. Sakada S, Aida H. Electrophysiological studies of Golgi-Mazzoni corpuscles in the periosteum of the cat facial bones. *Bull Tokyo Dent Coll* 1971;12: 255-72.
6. Sakada S, Aida H. Localization and shape of the Golgi-Mazzoni corpuscles in the facial bones' periosteum of the cat. *Bull Tokyo Dent Coll* 1971;12: 235-53.
7. Sakada S, Maeda K. Characteristics of innervation and nerve ending in cat's mandibular periosteum. *Bull Tokyo Dent Coll* 1967;8:77-94.
8. Sakada S, Maeda K. Correlation between histological structure and response to pressure of mechanoreceptors in the cat mandibular periosteum. *Bull Tokyo Dent Coll* 1967;8:181-96.
9. Sakada S, Miyake A. Response of slow-adapting free-fiber ending units in the cat mandibular periosteum, to vibratory stimulation. *Bull Tokyo Dent Coll* 1972;13: 205-25.
10. Nencini S, Ivanusic JJ. The physiology of bone pain. how much do we really know? *Front Physiol* 2016;7:157.
11. Brjussowa SS, Lebedenko WW. Zur Schmerzleitungs-fähigkeit der Geäfaben. *Z Gesamte Exp Med* 1930;69:29-40.
12. Furusawa S. A neurophysiological study on the sensibility of the bone marrow. *Nippon Seikeigeka Gakkai Zasshi* 1970;44:365-70.
13. White BJ, Walsh M, Egol KA, Tejwani NC. Intra-articular block compared with conscious sedation for closed reduction of ankle fracture-dislocations: a prospective randomized trial *J Bone Joint Surg Am* 2008; 90:371-4.
14. RX List, Marcaine. URL: <http://www.rxlist.com/marcaine-drug/clinical-pharmacology.htm>
15. Tageldin M, Alrashid EM, Khoriaty AA, Gadikoppula S, Atkinson HD. Periosteal nerve blocks for distal radius and ulna fracture manipulation-the technique and early results. *J Orthop Surg Res* 2017;17:157.